

Percutaneous Periprosthetic Regurgitation

**Charanjit S. Rihal MD MBA
Chair, Division of
Cardiovascular Diseases**

**Mayo Clinic and Foundation
Rochester, MN, USA**



DISCLOSURES

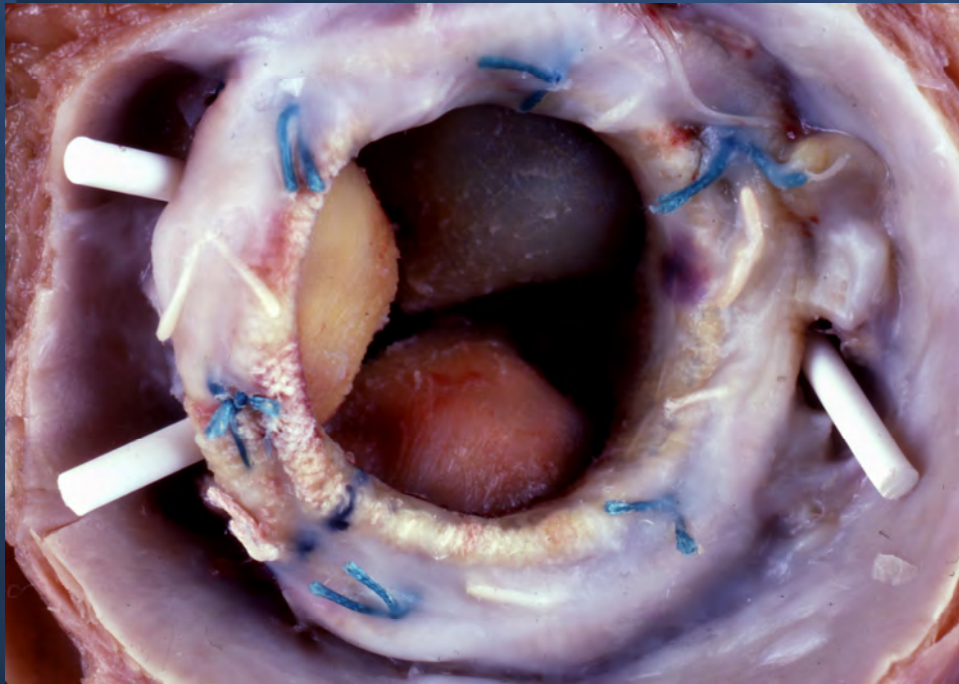
Relevant Financial Relationship(s)

None

Off Label Usage

AGA

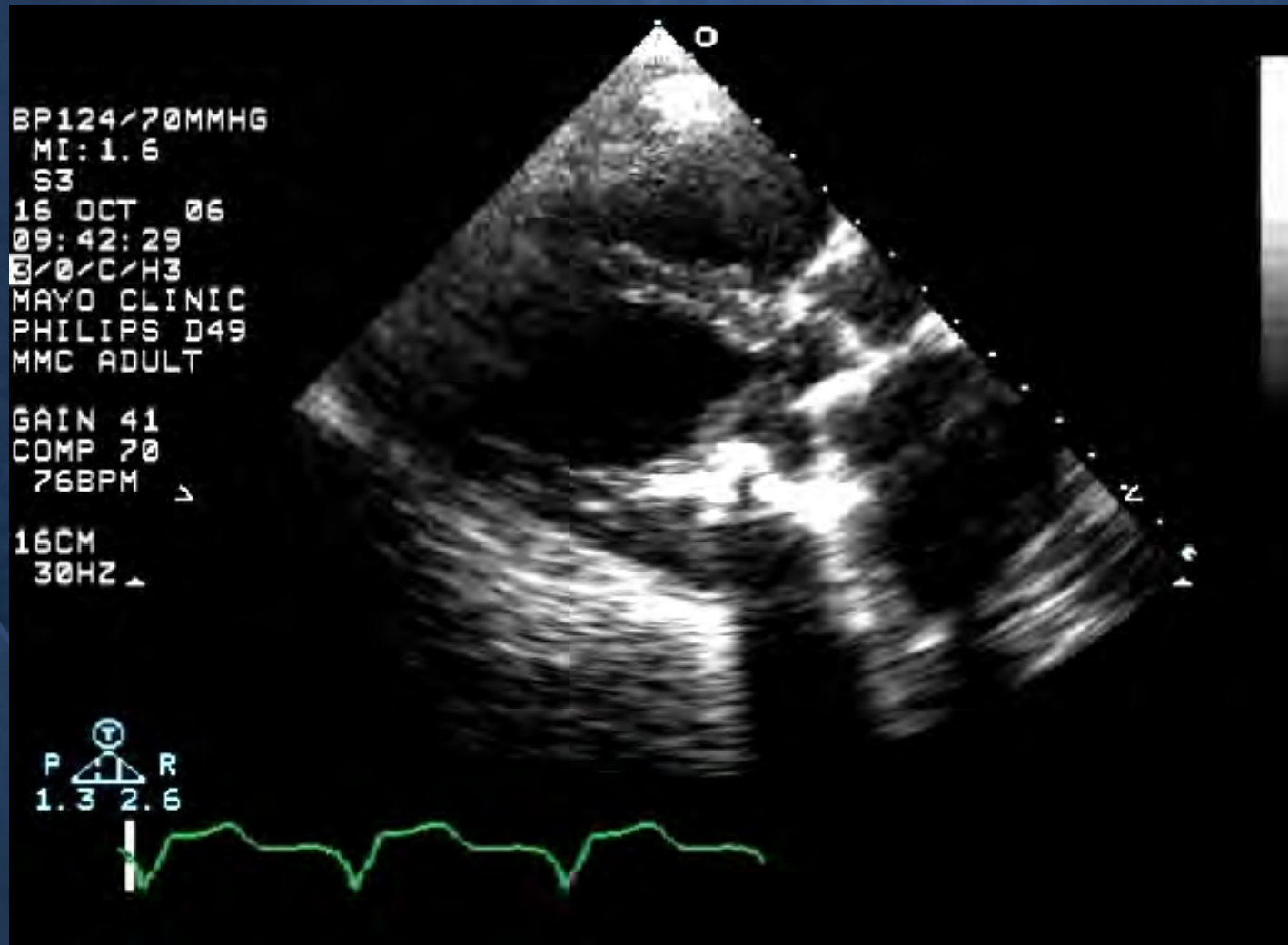
Percutaneous Approaches to Periprosthetic Regurgitation



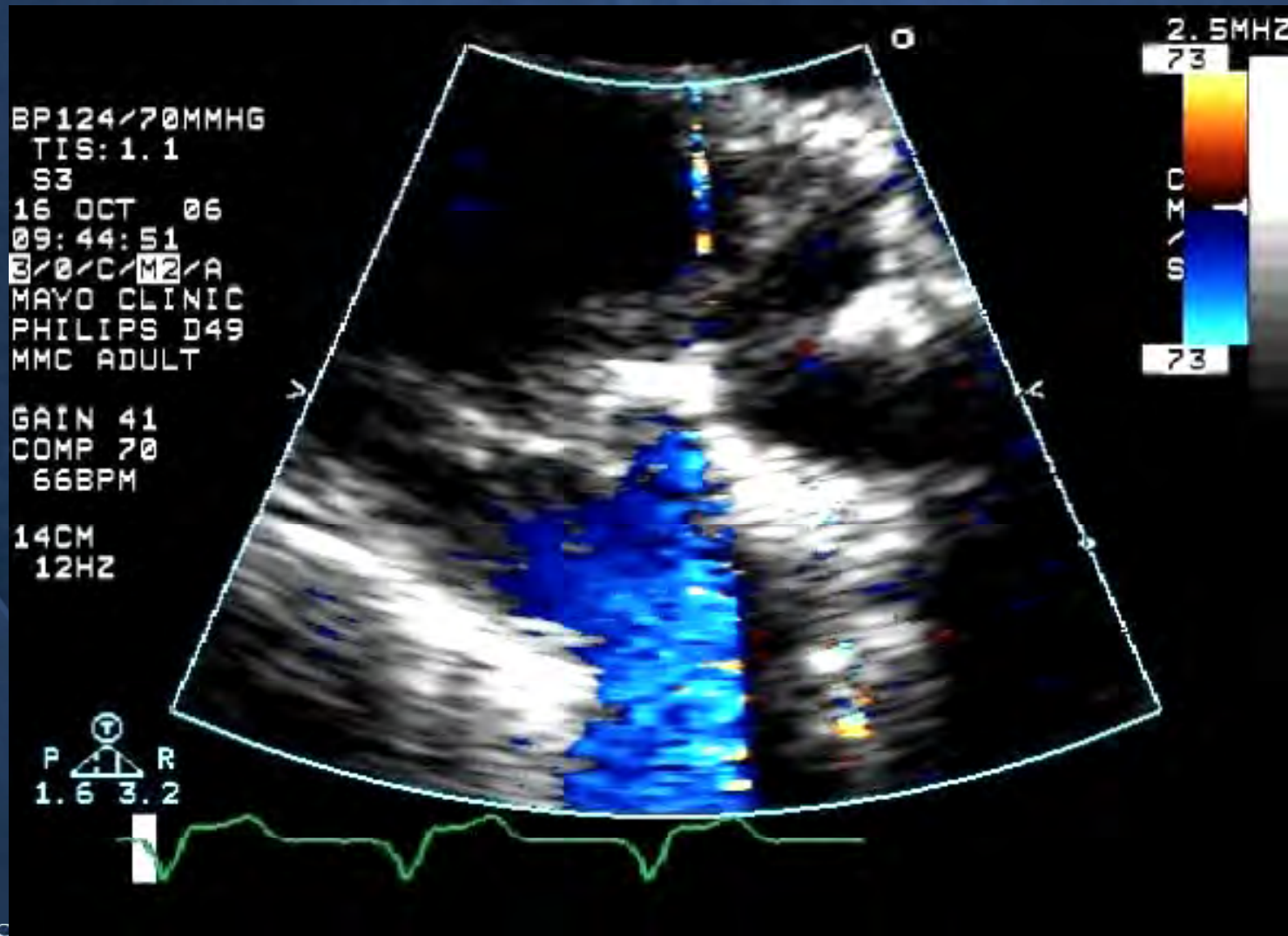
5 - 17% of valves
Hemolysis, CHF
Difficult to treat
Underestimated

74F Edwards Bileaflet MVR

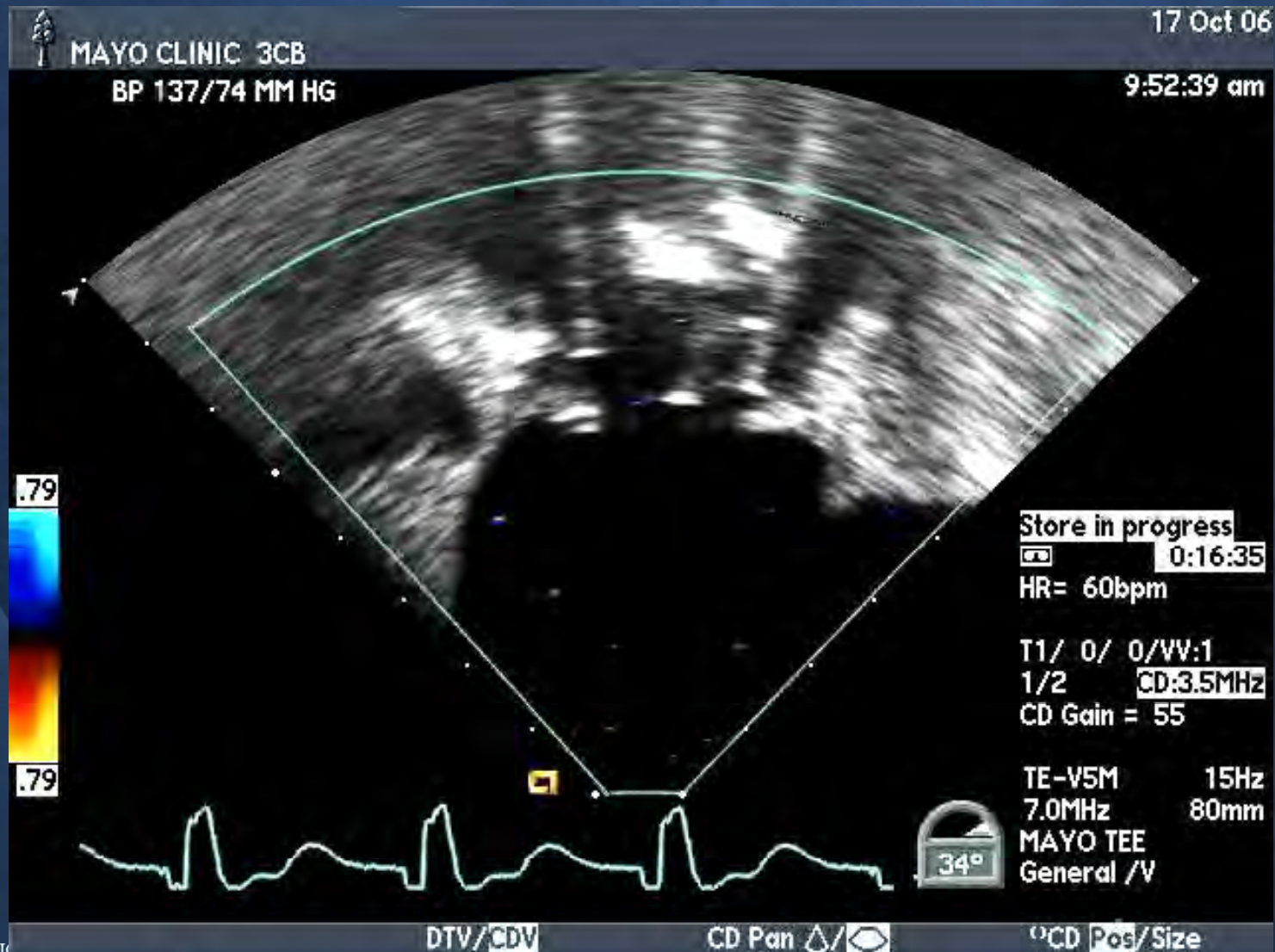
6 Years Old – Annual Echos



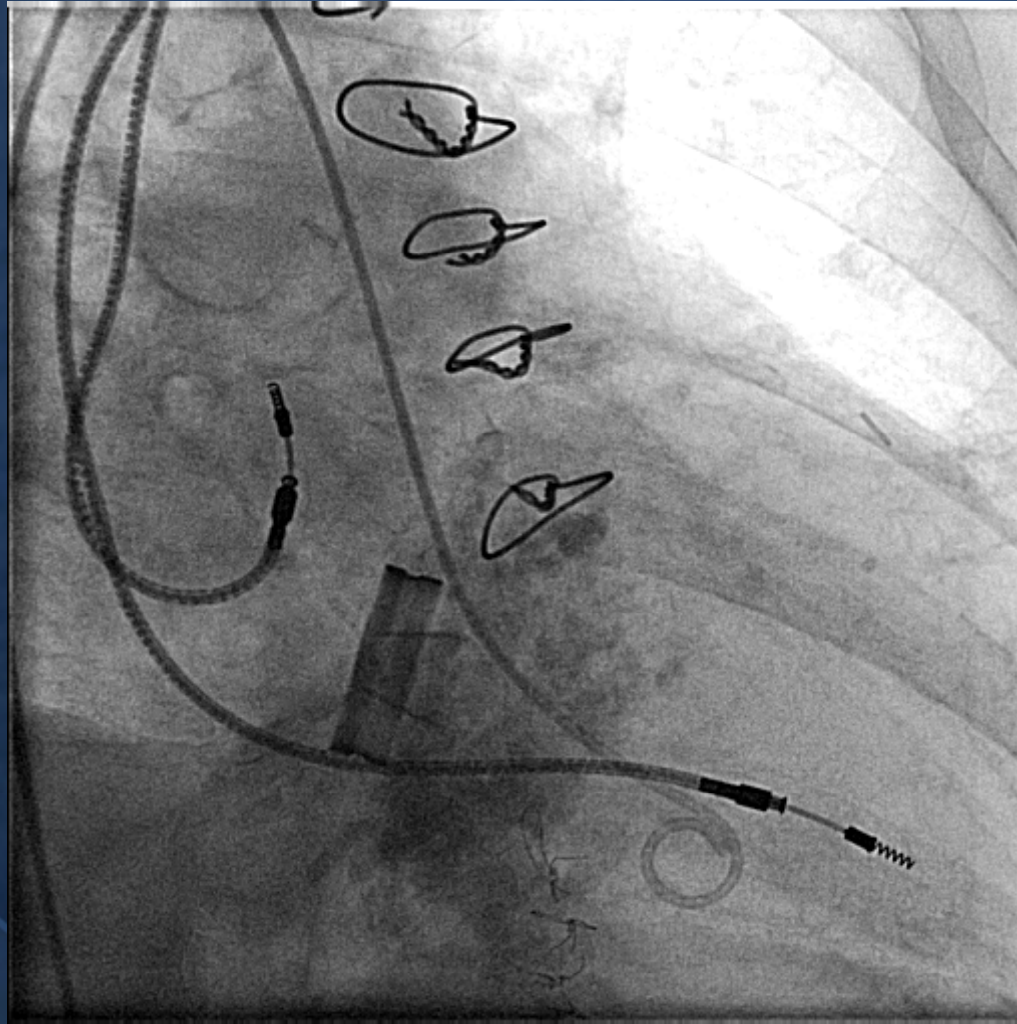
A Diagnostic Challenge



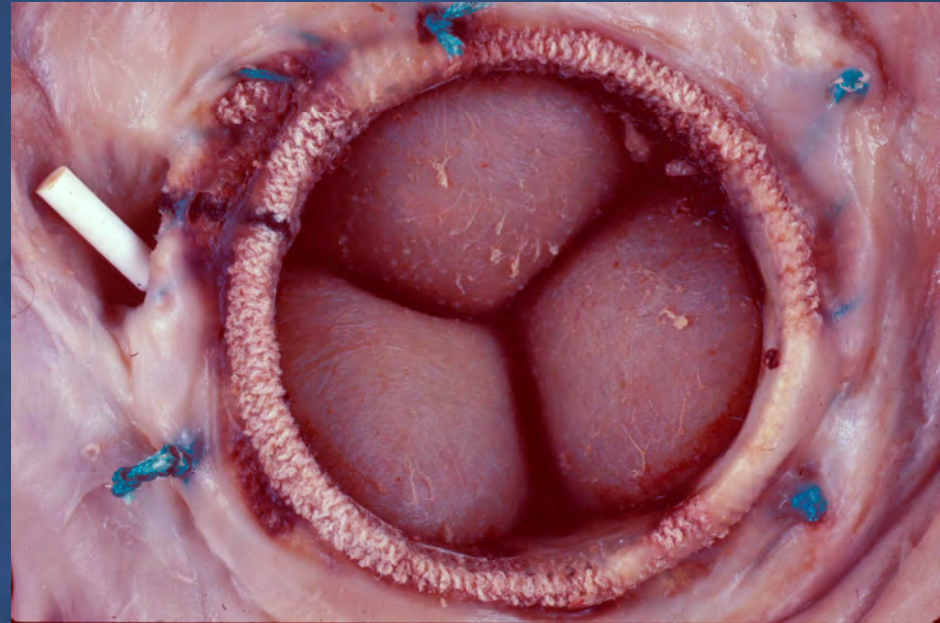
A Diagnostic Challenge



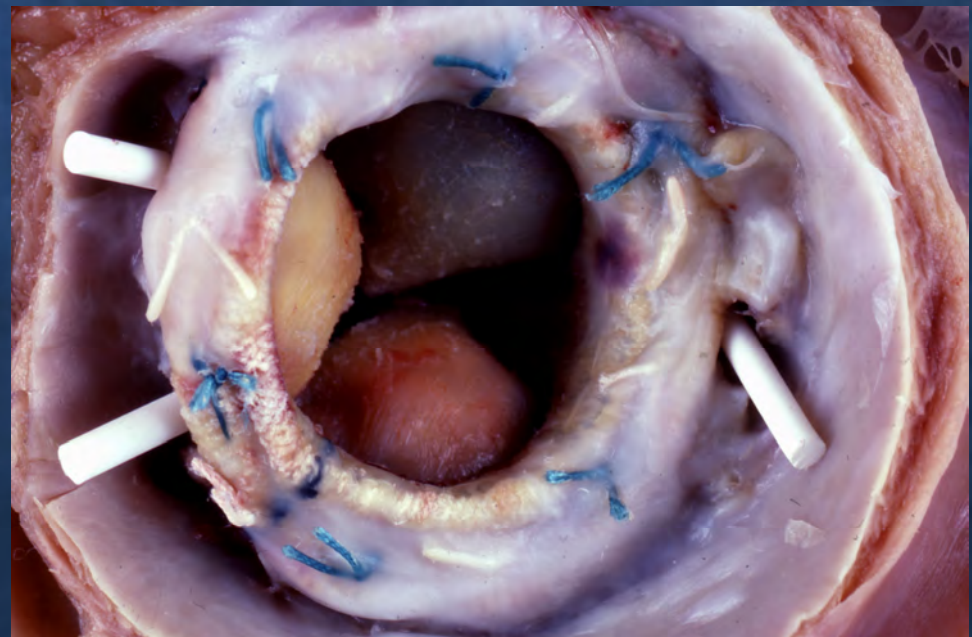
A Diagnostic Challenge



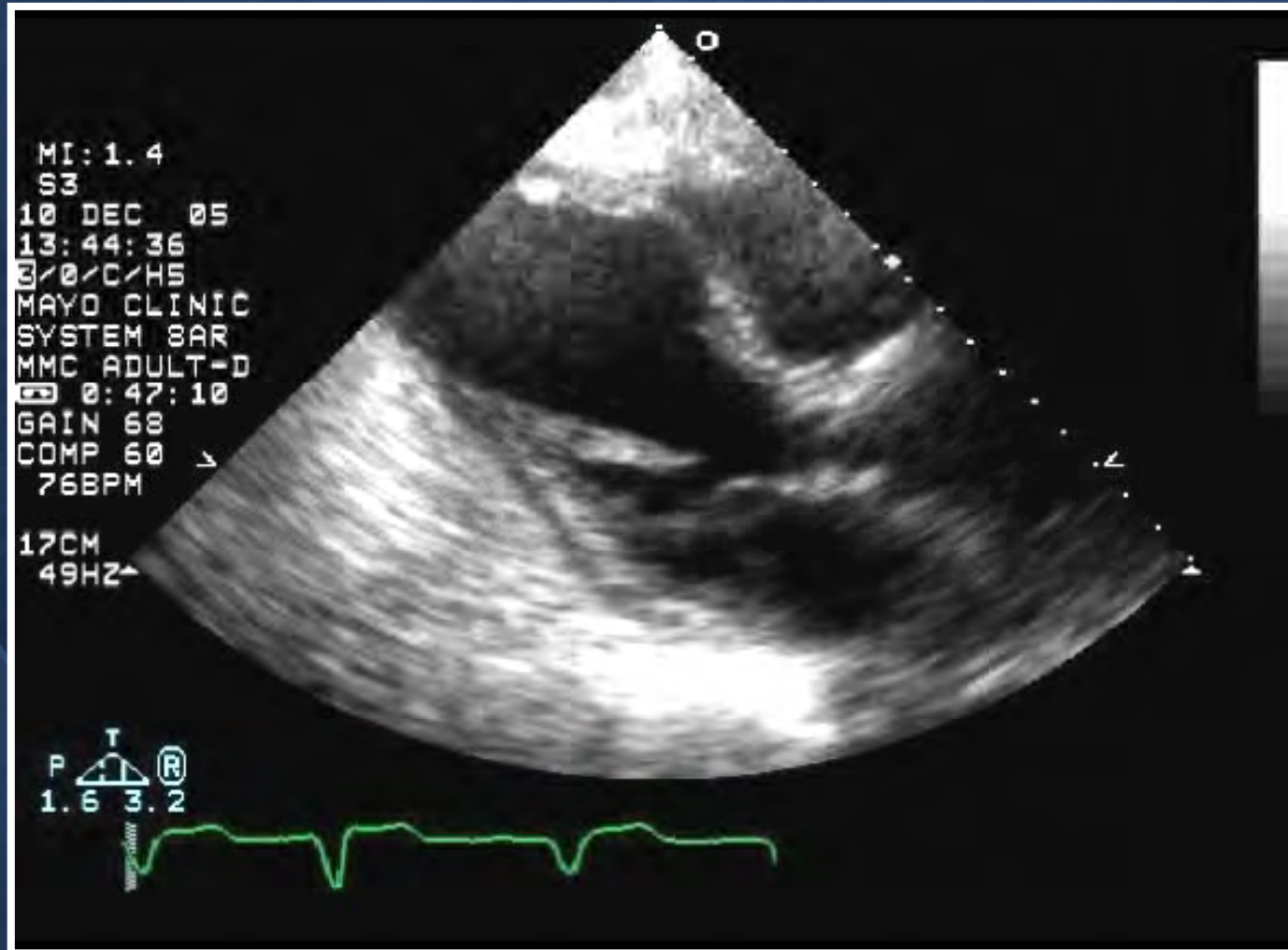
**LA View:
Single leak**



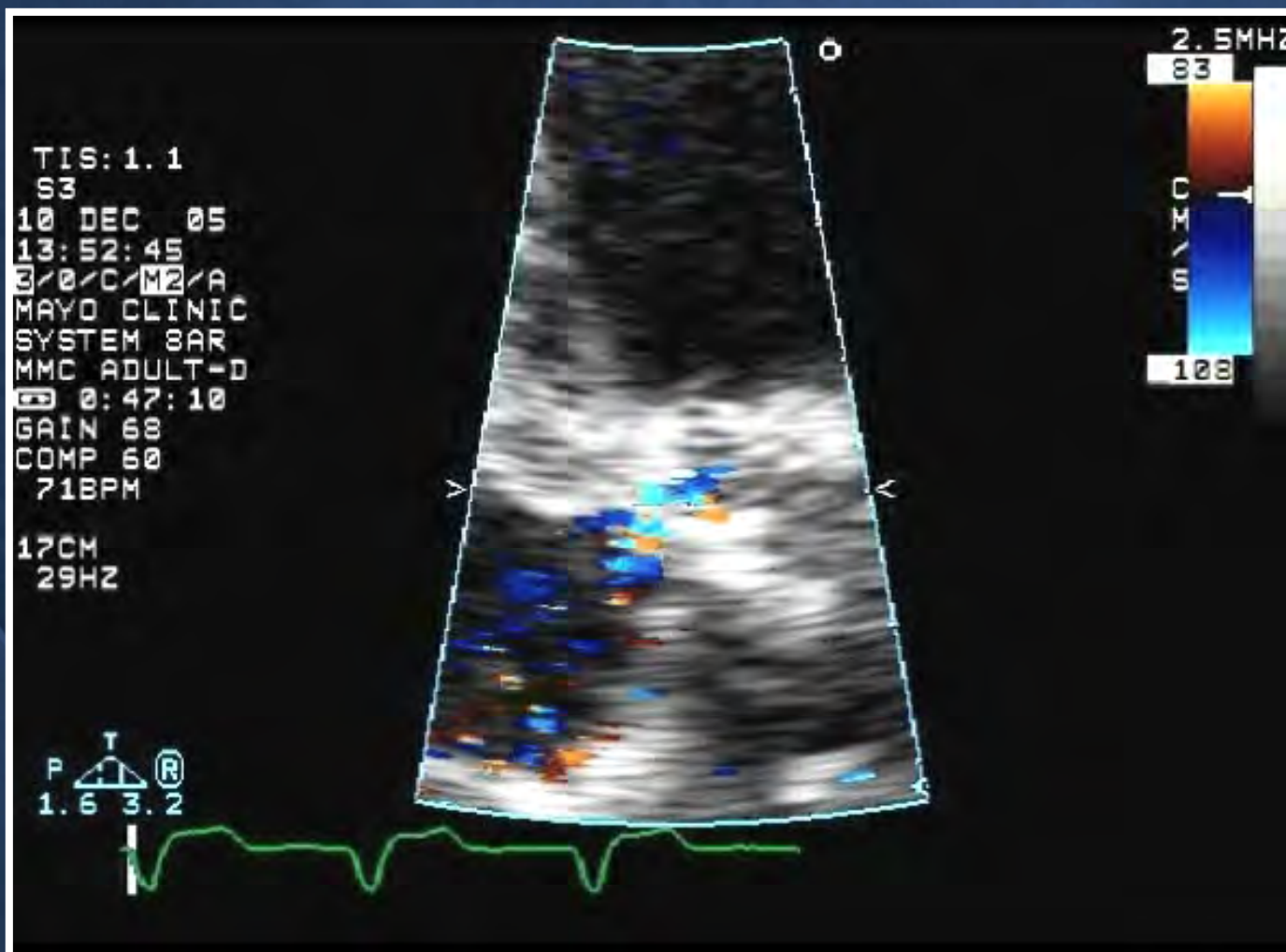
Multiple leaks



80M s/p 3 sternotomies CABG + Hancock AVR

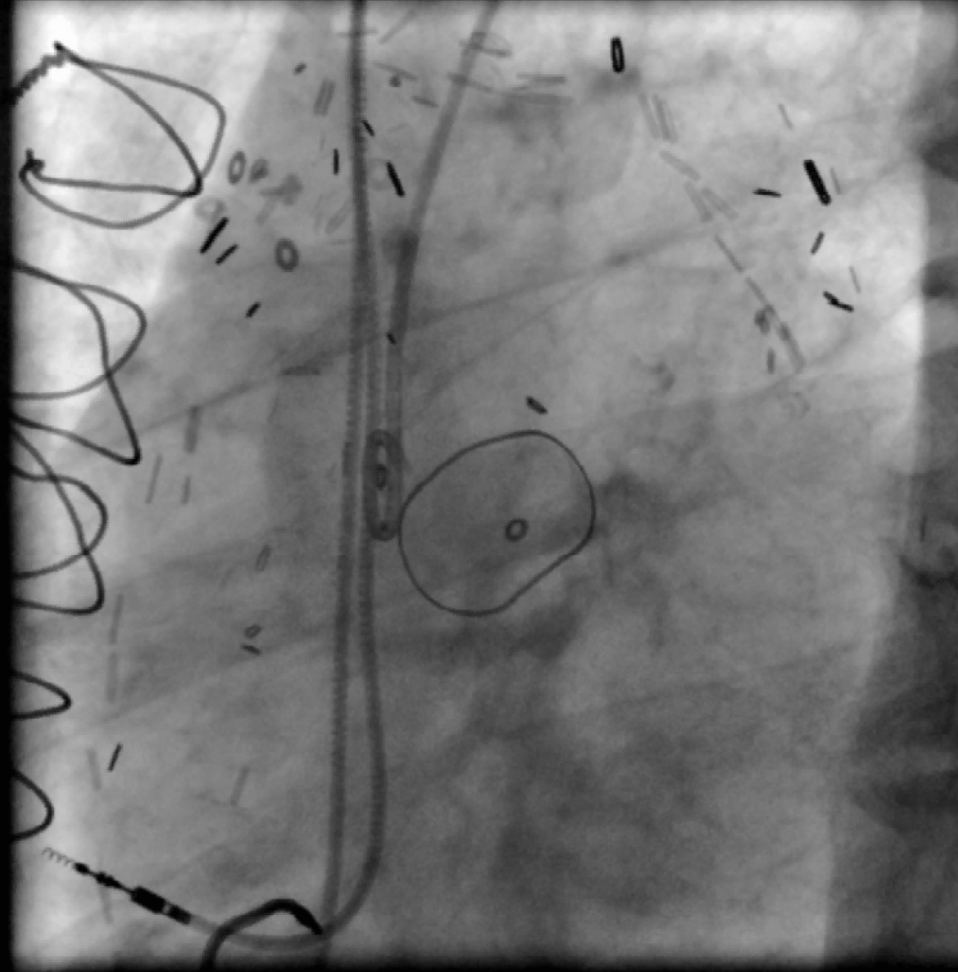


Periprosthetic Leak

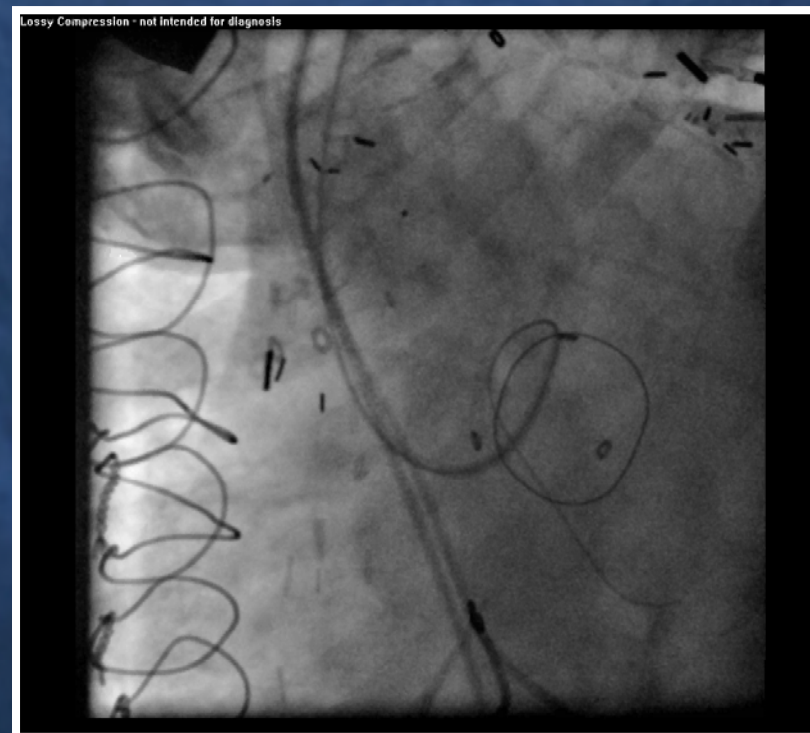
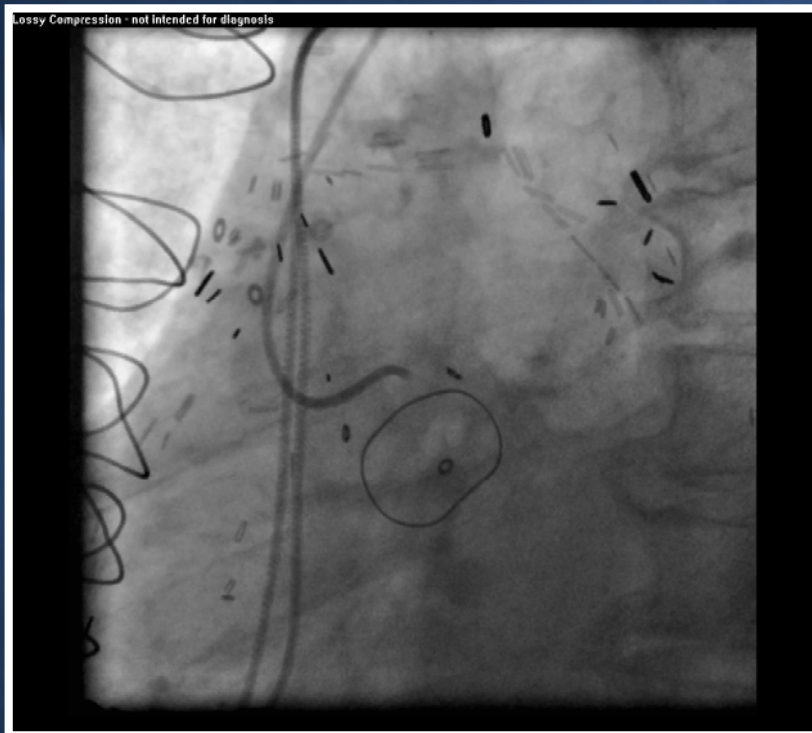


Aortogram

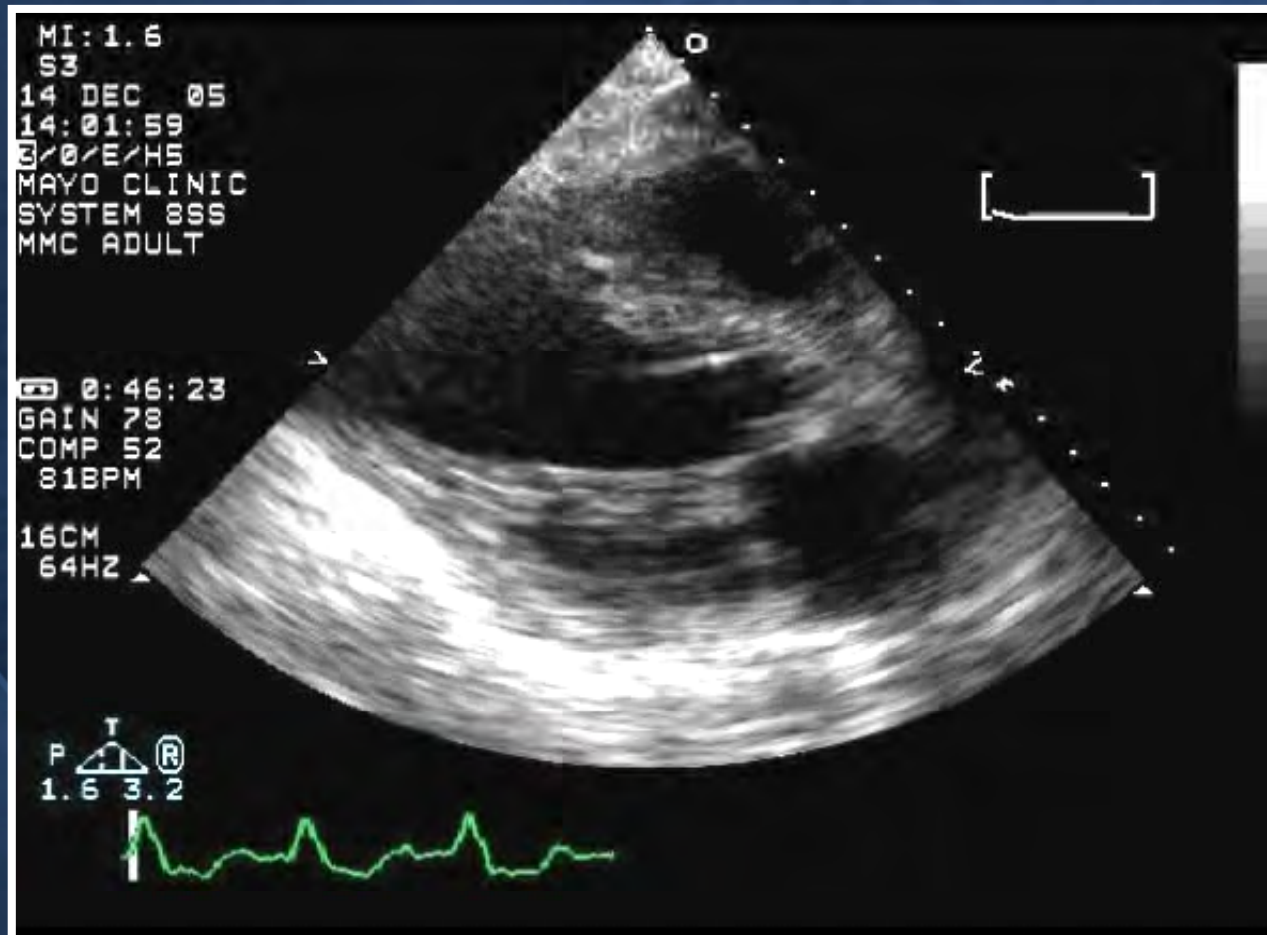
Lossy Compression - not intended for diagnosis



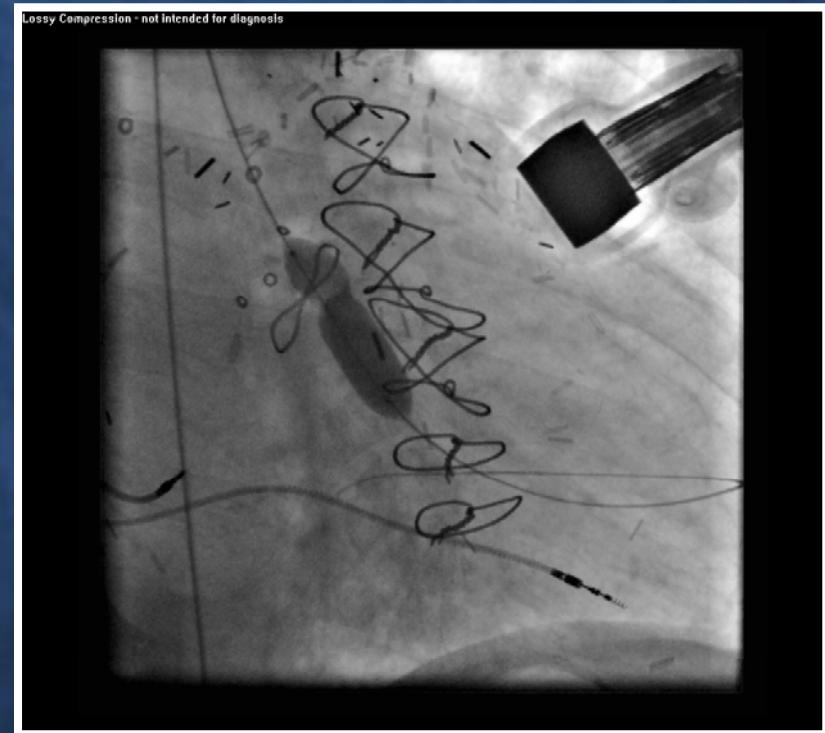
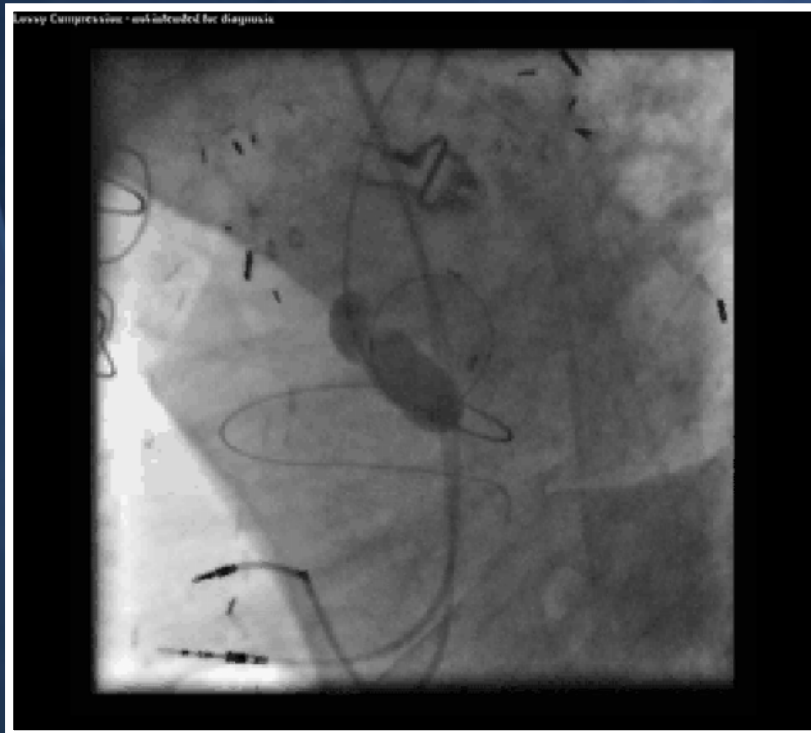
Wire Crossing



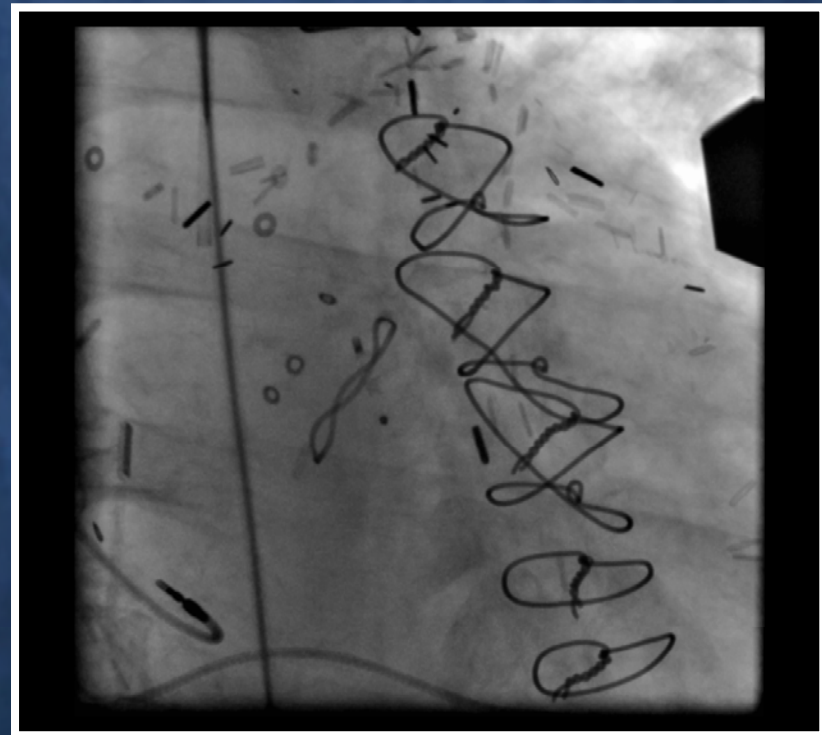

Wire Crossing



Sizing Balloon

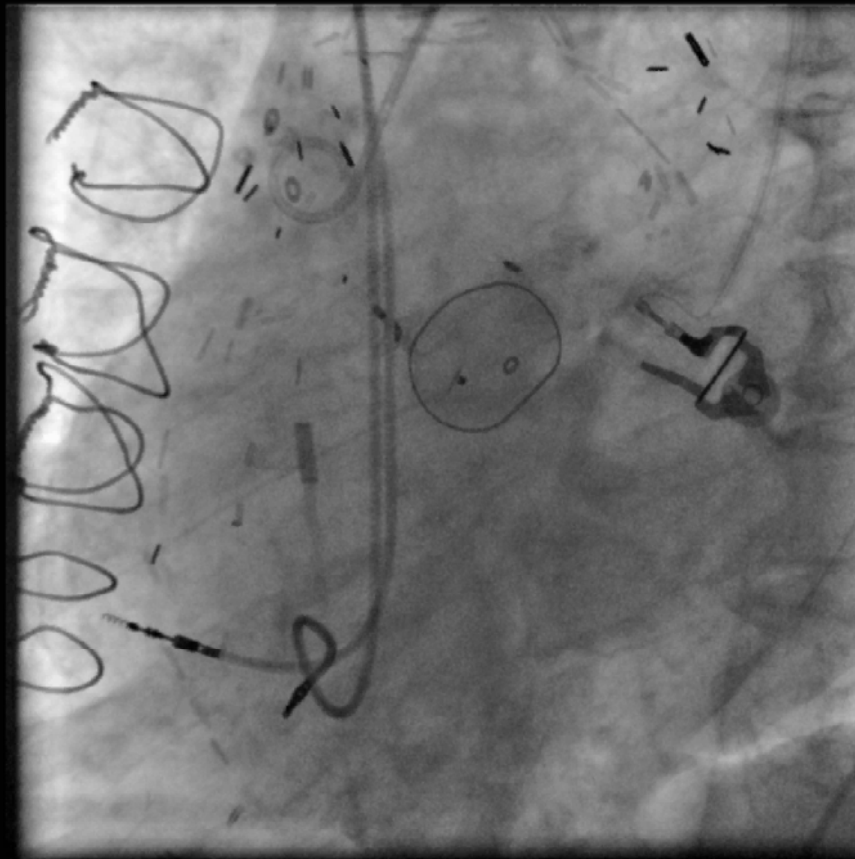


ASD Device



Post Aortogram

Lossy Compression - not intended for diagnosis



60 yo Man

- **AVR 1981 – endocarditis**
- **Starr-Edwards AVR + MVR 1989 due to endocarditis.**
- **CHF class IV. AF. ICD.**
- **Severe LV dysfunction EF 10%**
- **Severe periprosthetic leak**



11:08:32 am

TE-V5M 48Hz

5.0MHz 180mm

MAYO TEE

General /V

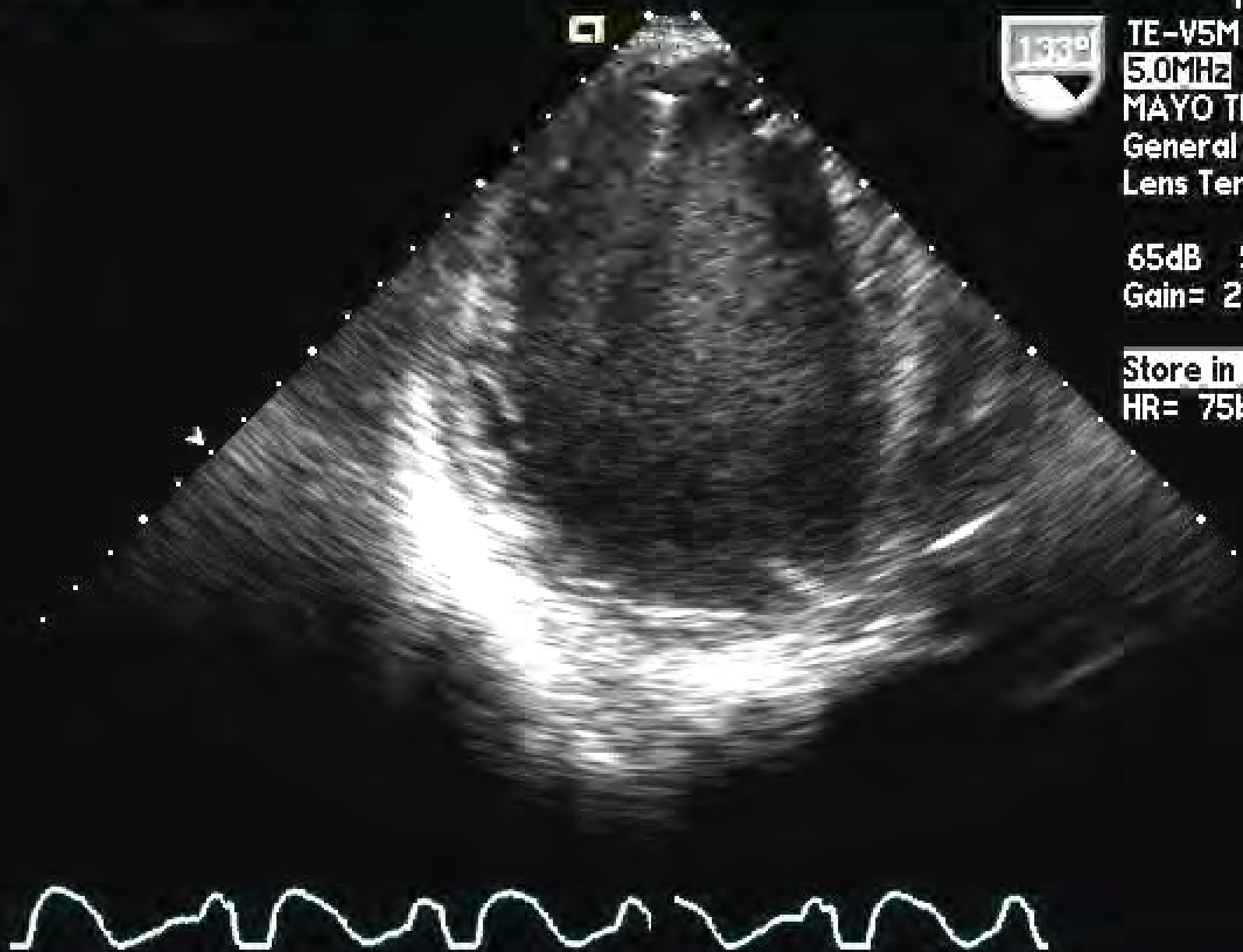
Lens Temp=38.1°C

65dB S1/ 0/1/ 6

Gain= 20dB Δ=1

Store in progress

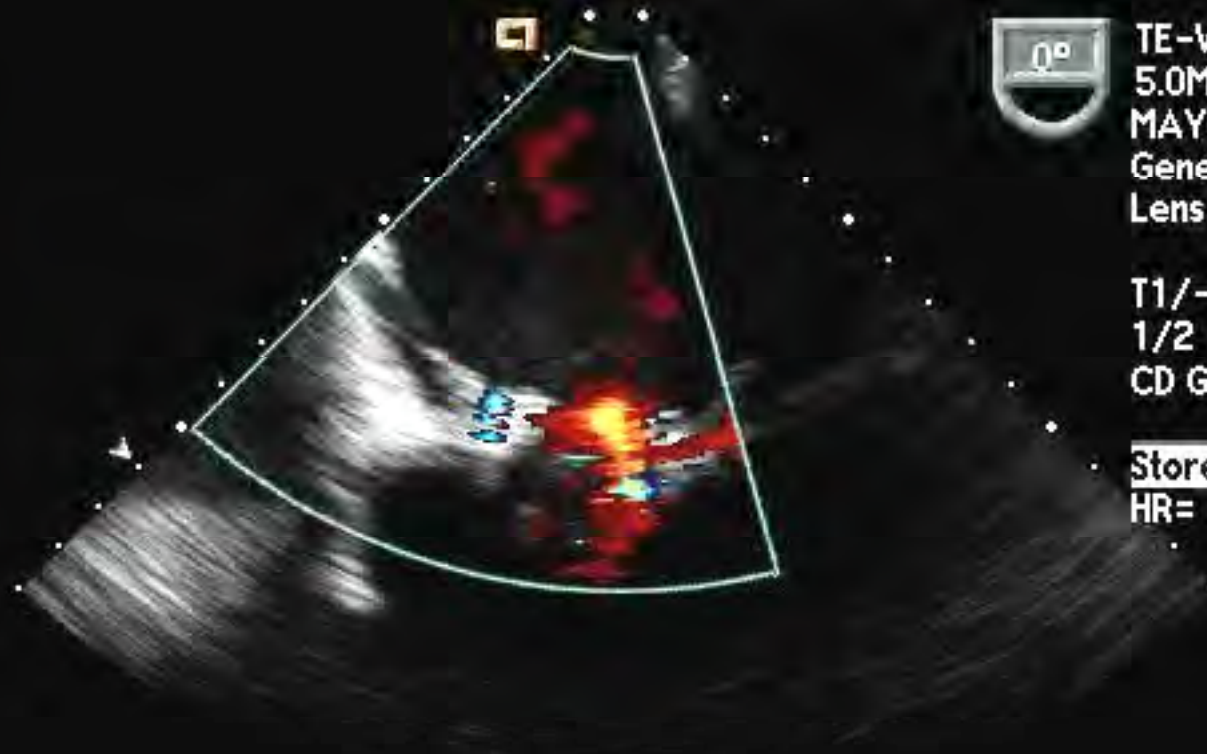
HR= 75bpm





MAYO CLINIC 3DL


20 Jan 06



11:29:46 am
 TE-V5M 15Hz
 5.0MHz 140mm
 MAYO TEE
 General /V
 Lens Temp=37.7°C

T1/-2/ 0/V:A
 1/2 **CD:3.5MHz**
 CD Gain = 54

Store in progress
 HR= 67bpm



CD Pan

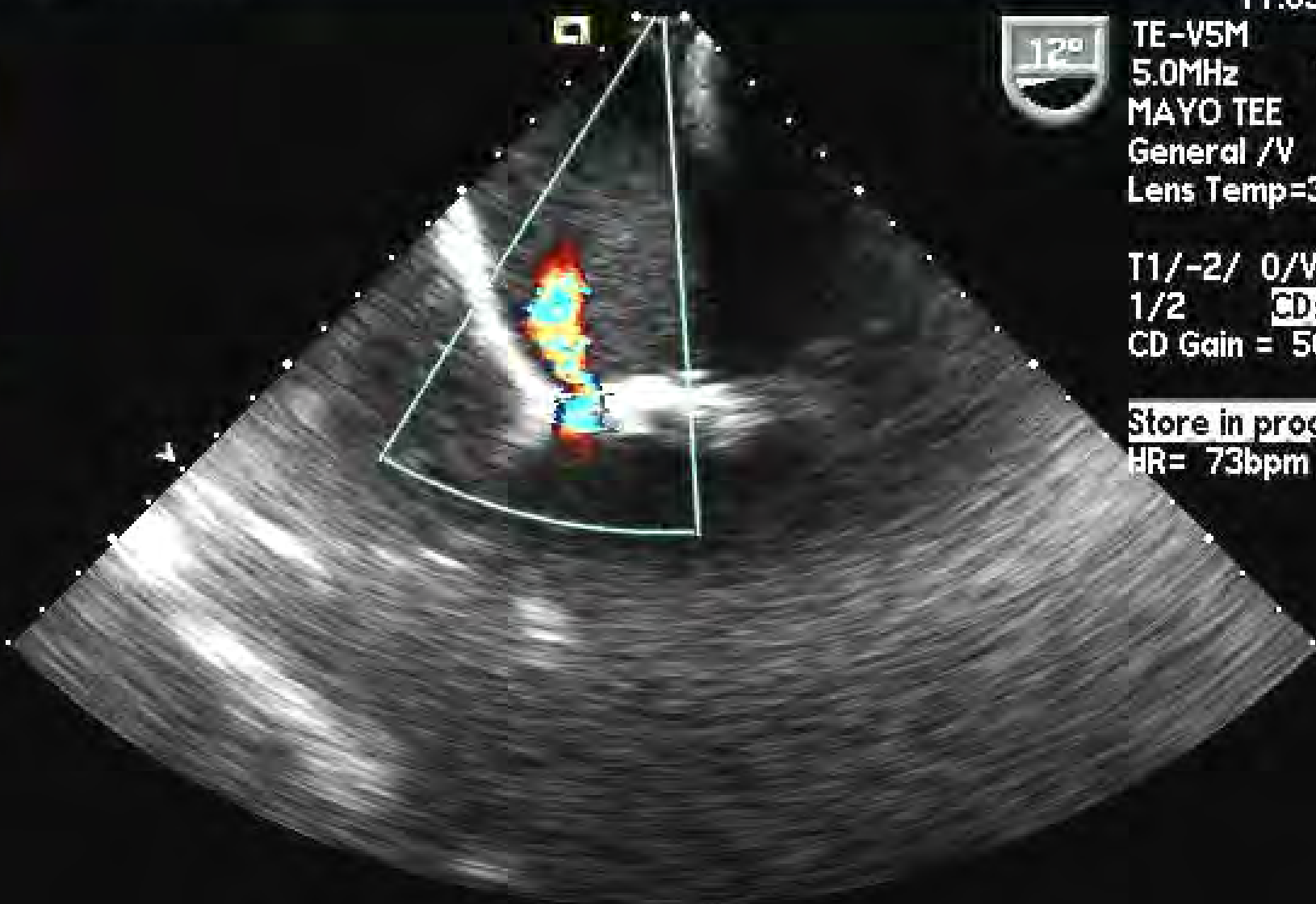
CD Pos/Size



.46



.46



11:03:15 am

TE-V5M 19Hz

5.0MHz 180mm

MAYO TEE

General /V

Lens Temp=37.6°C

T1/-2/ 0/V:A

1/2 CD:3.5MHz

CD Gain = 50


Store in progress

HR= 73bpm

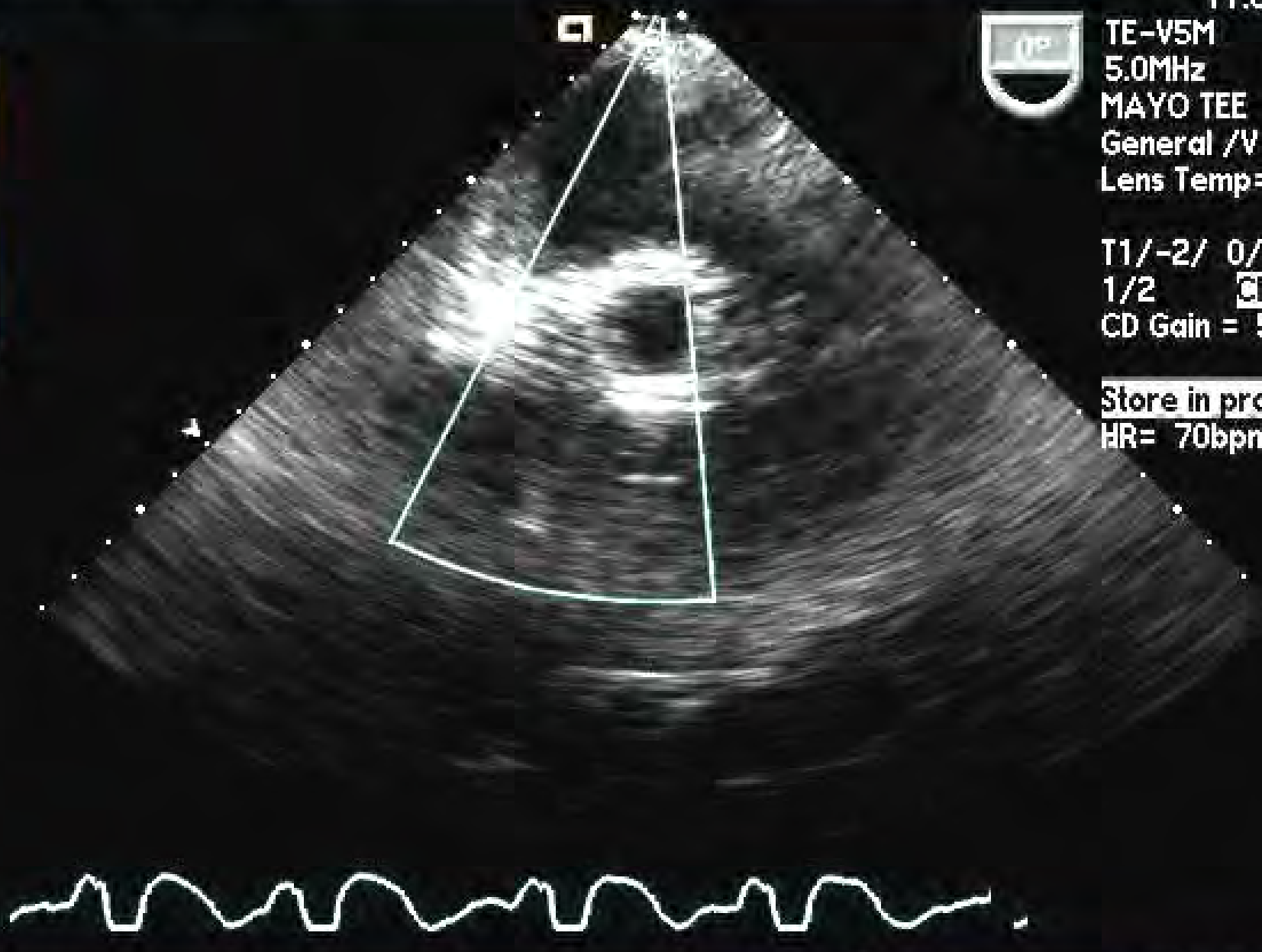




.46



.46



11:05:20 am

TE-V5M 20Hz

5.0MHz 180mm

MAYO TEE

General /V

Lens Temp=37.6°C

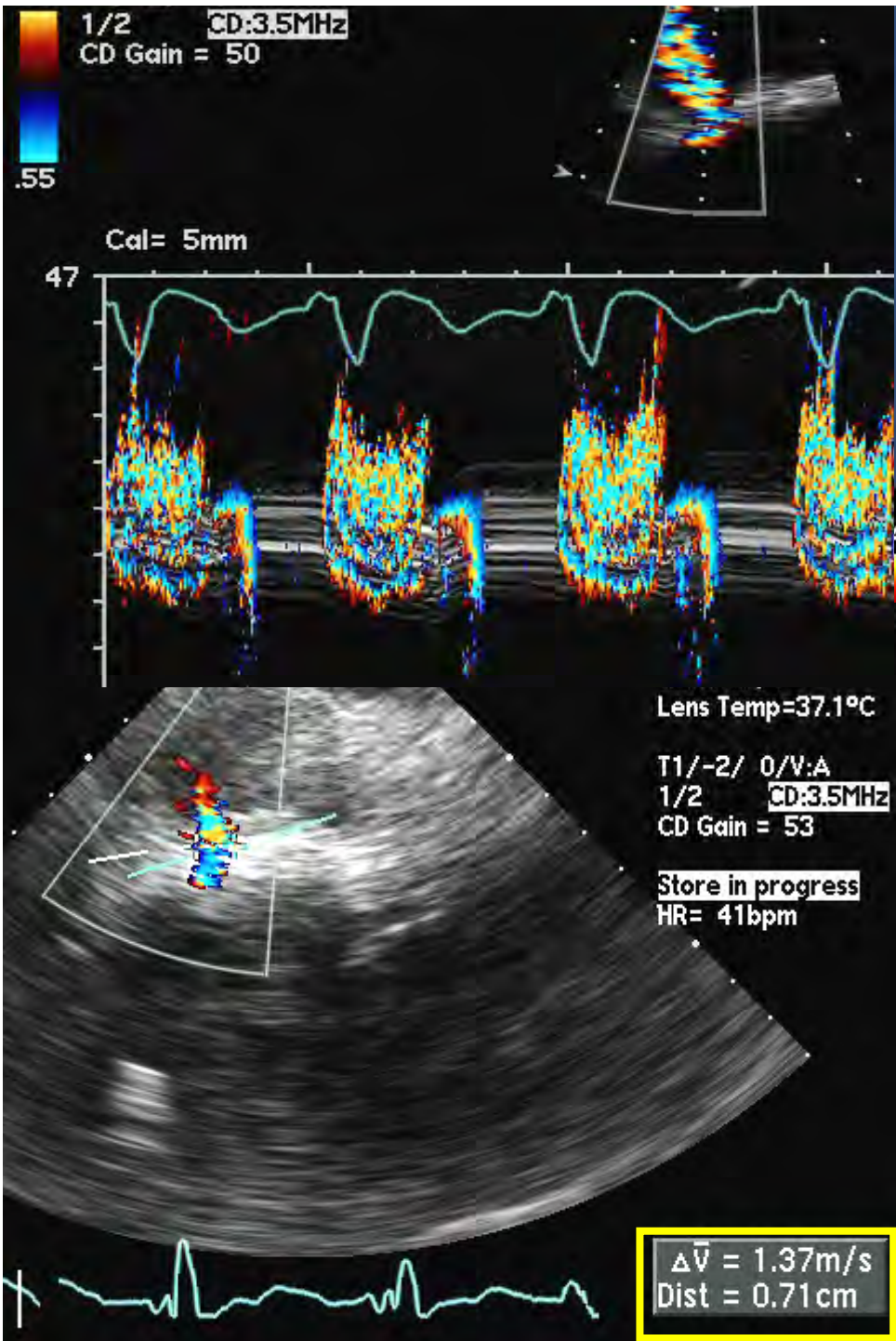
T1/-2/ 0/V:A

1/2 CD:3.5MHz

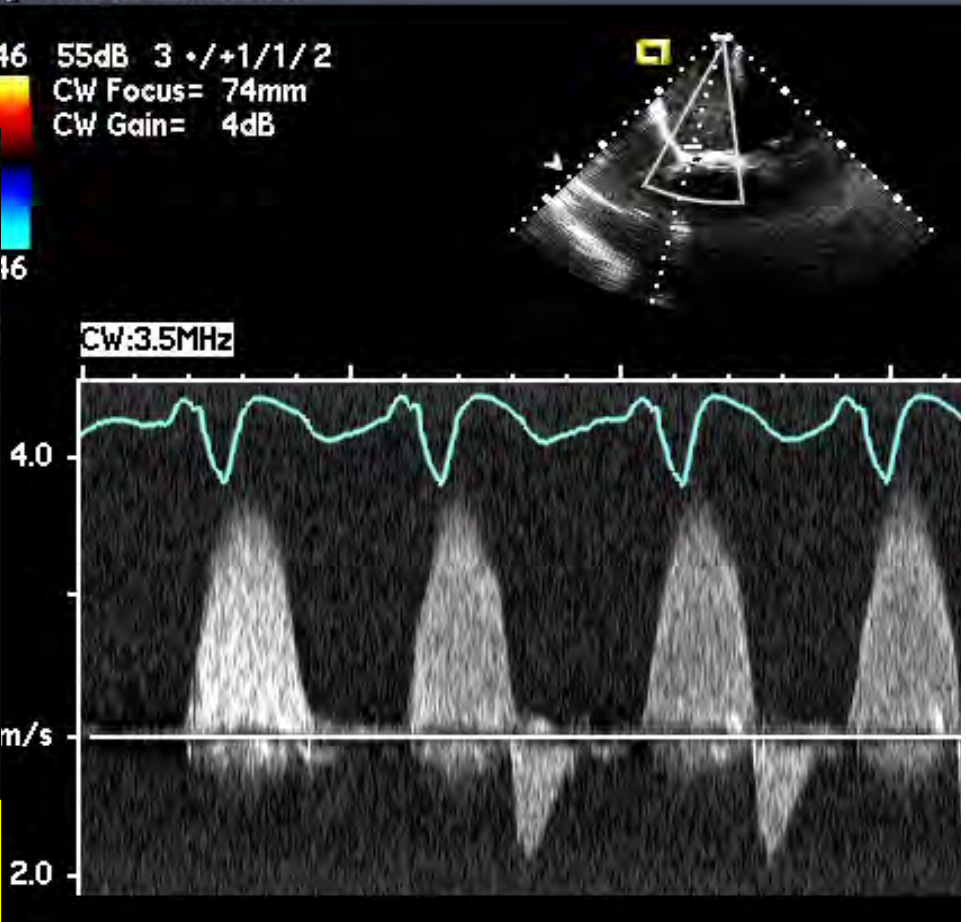
CD Gain = 50

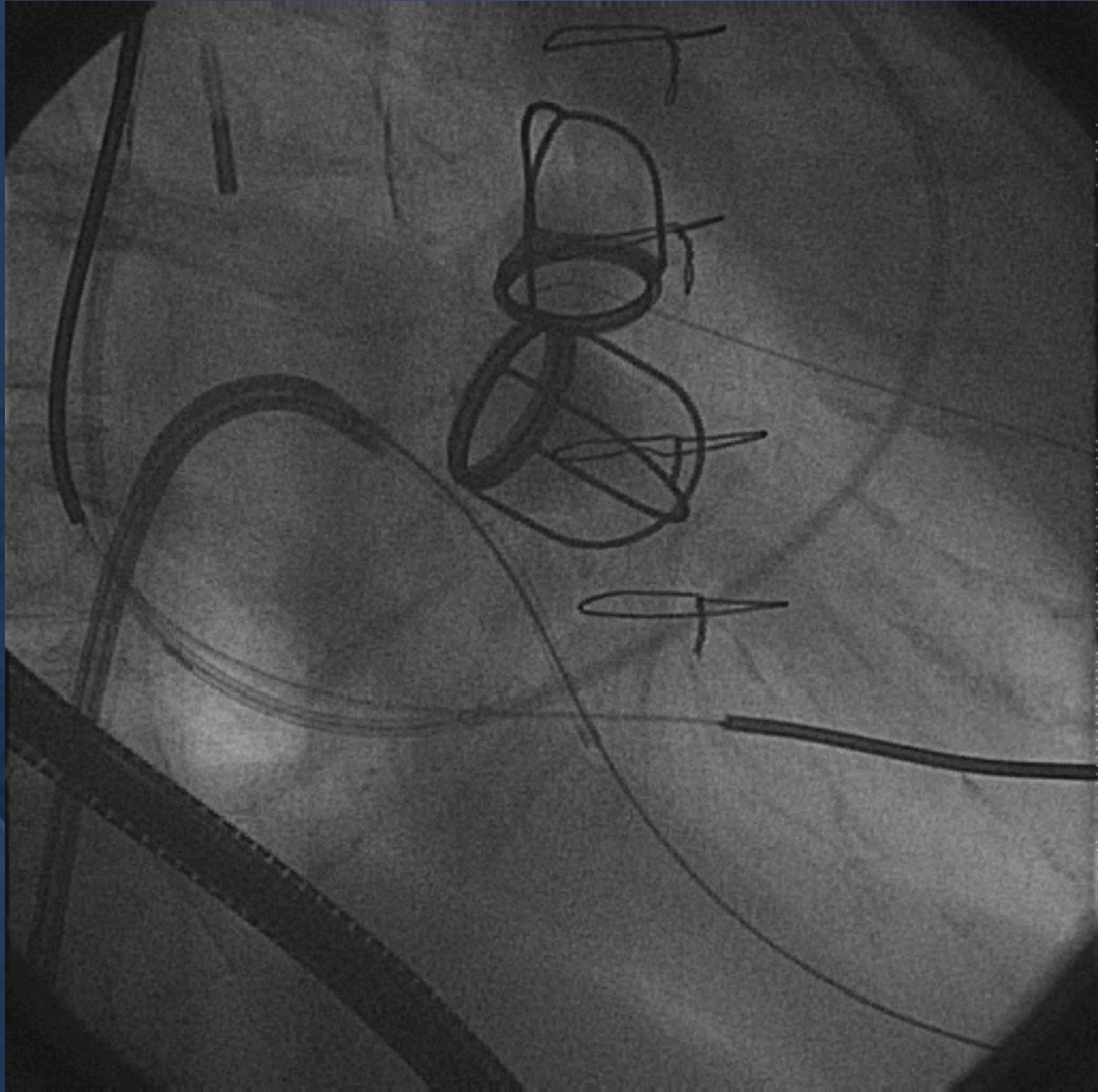
Store in progress

HR= 70bpm



Severe Periprosthetic Mitral Regurgitation with 7mm Orifice

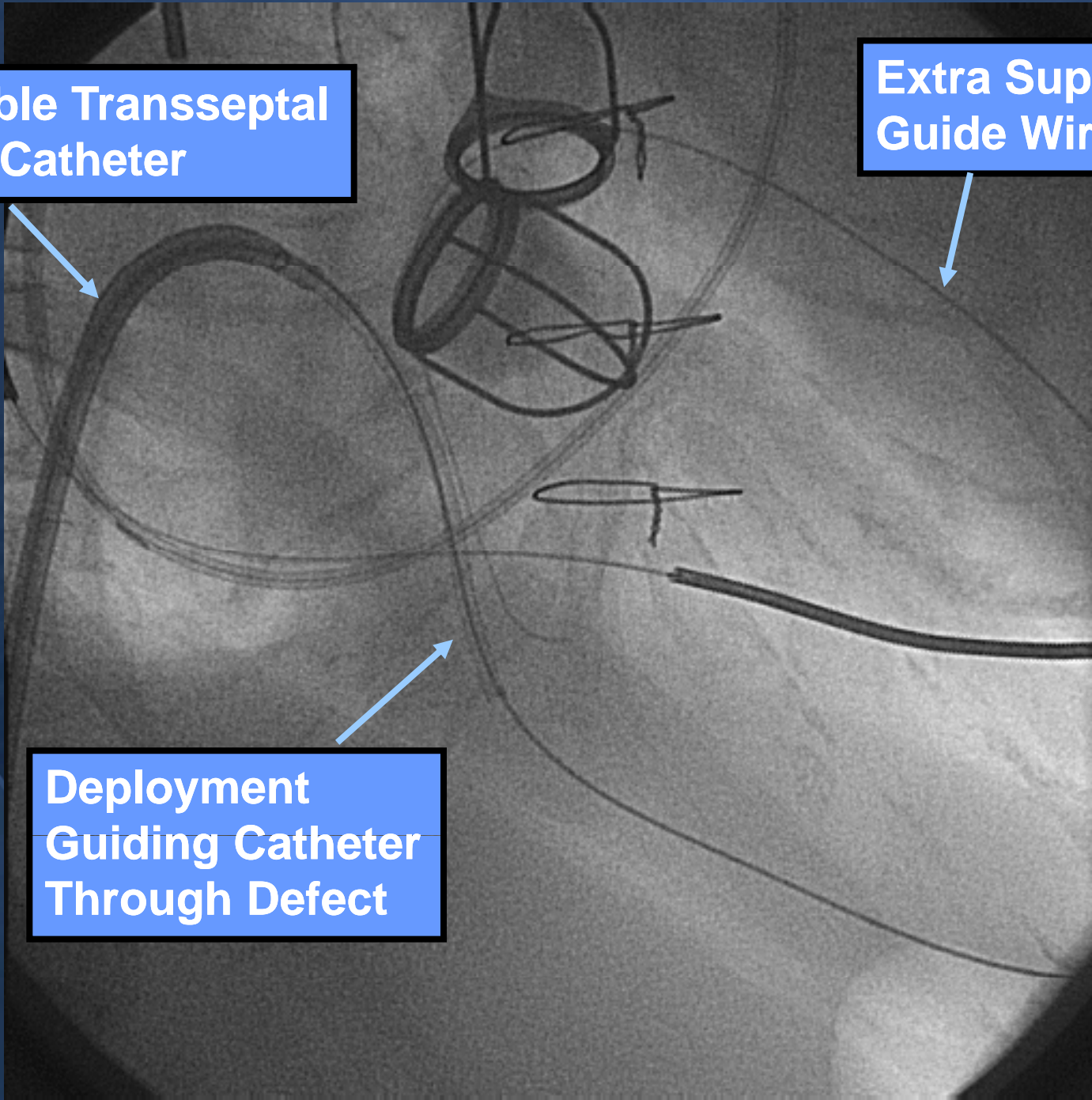




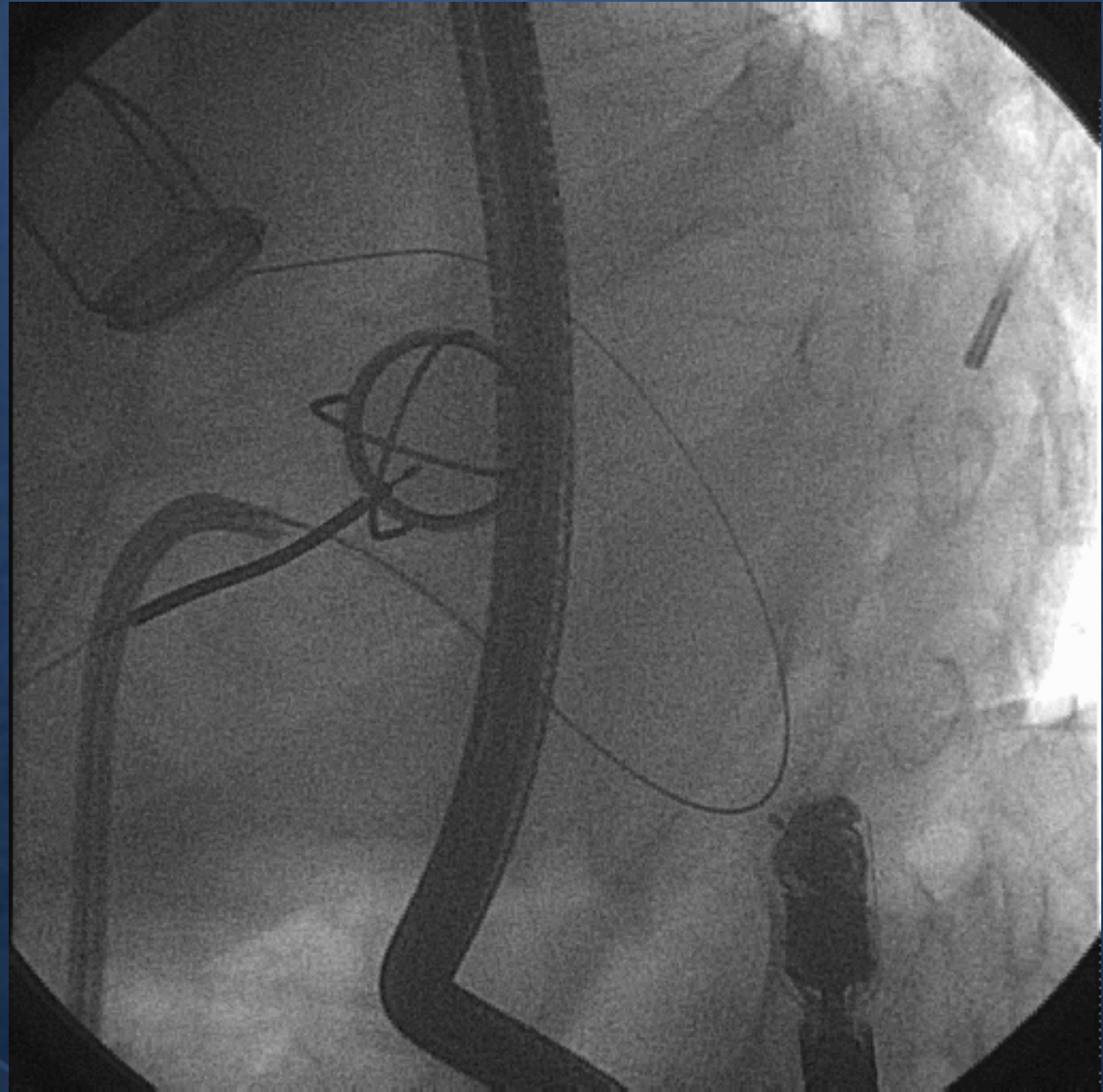
Deflectable Transseptal Guiding Catheter

Extra Support Guide Wire

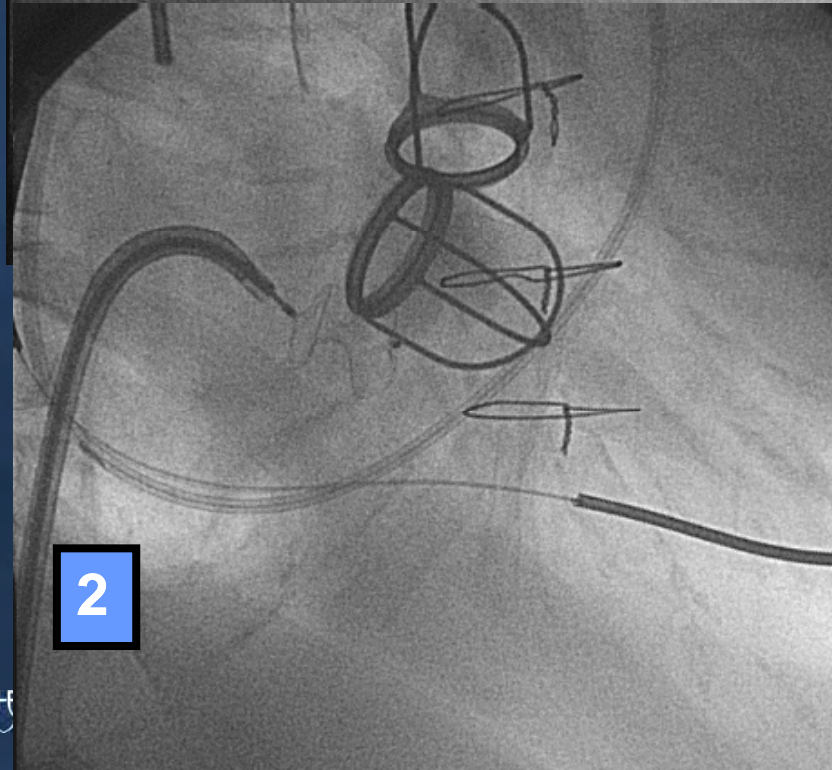
Deployment Guiding Catheter Through Defect



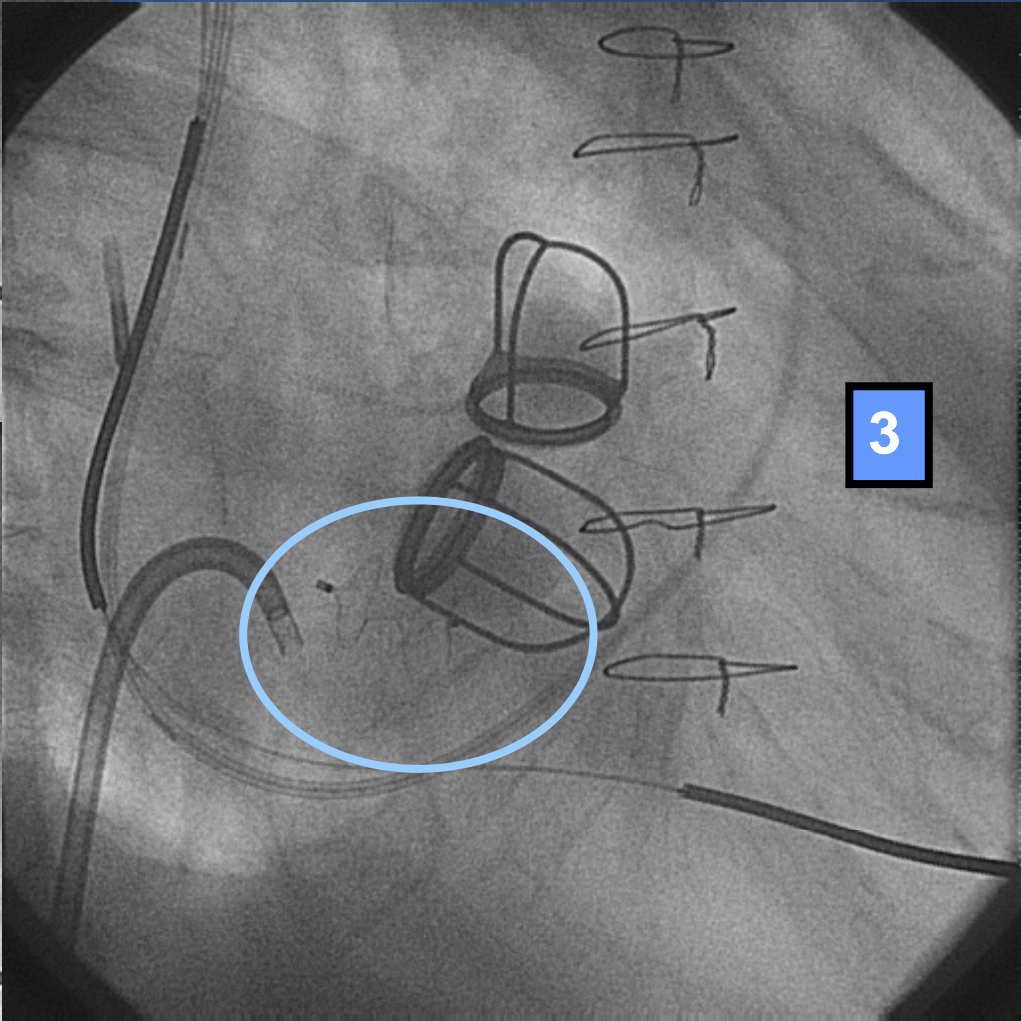
**Deployment
Guiding Catheter
Through Defect
Medial Aspect**



1

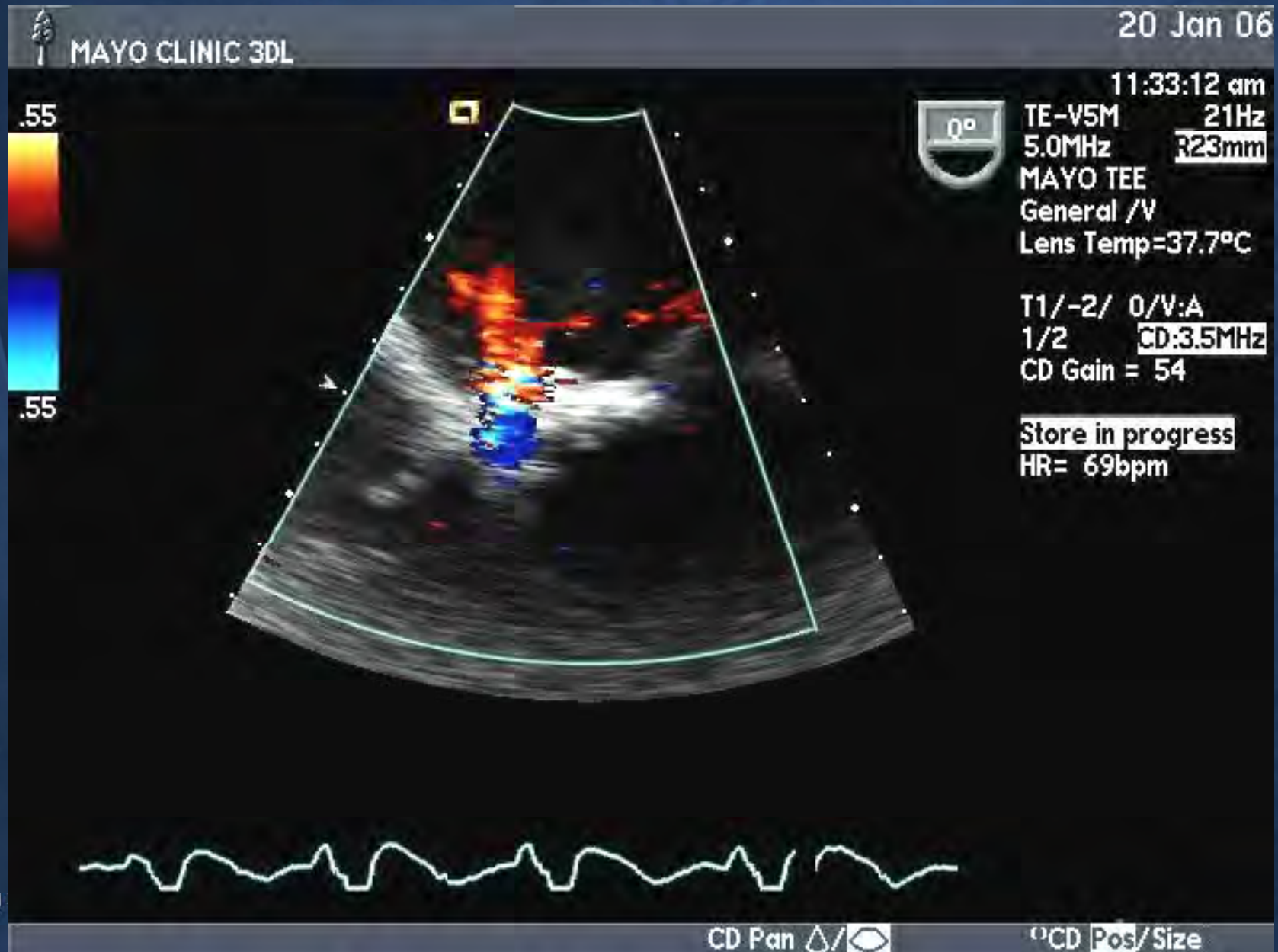


2



3

Post Deployment

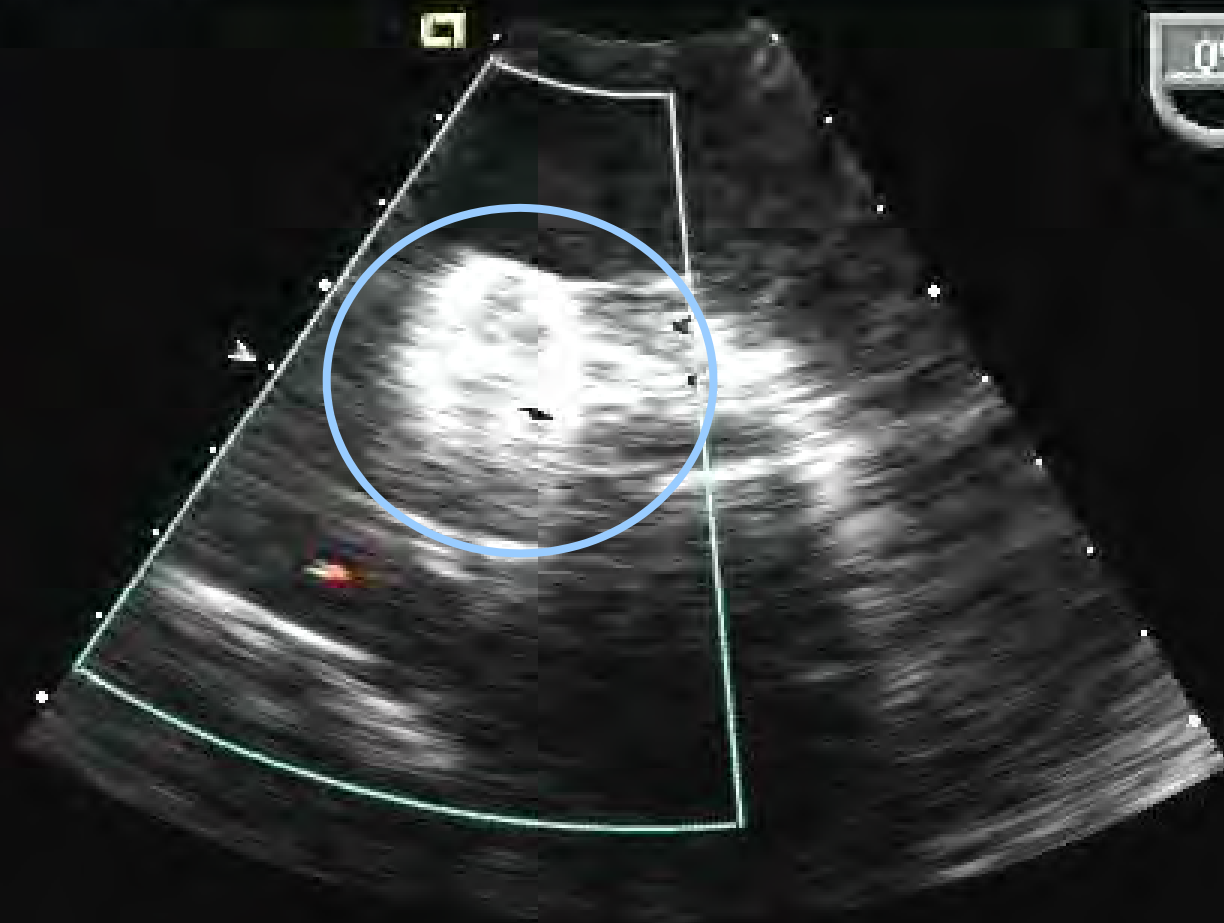




.55



.55



11:40:47 am

TE-V5M 23Hz

5.0MHz 317mm

MAYO TEE

General /V

Lens Temp=37.7°C

T1/-2/ 0/V:A

1/2 CD:3.5MHz

CD Gain = 51

Store in progress

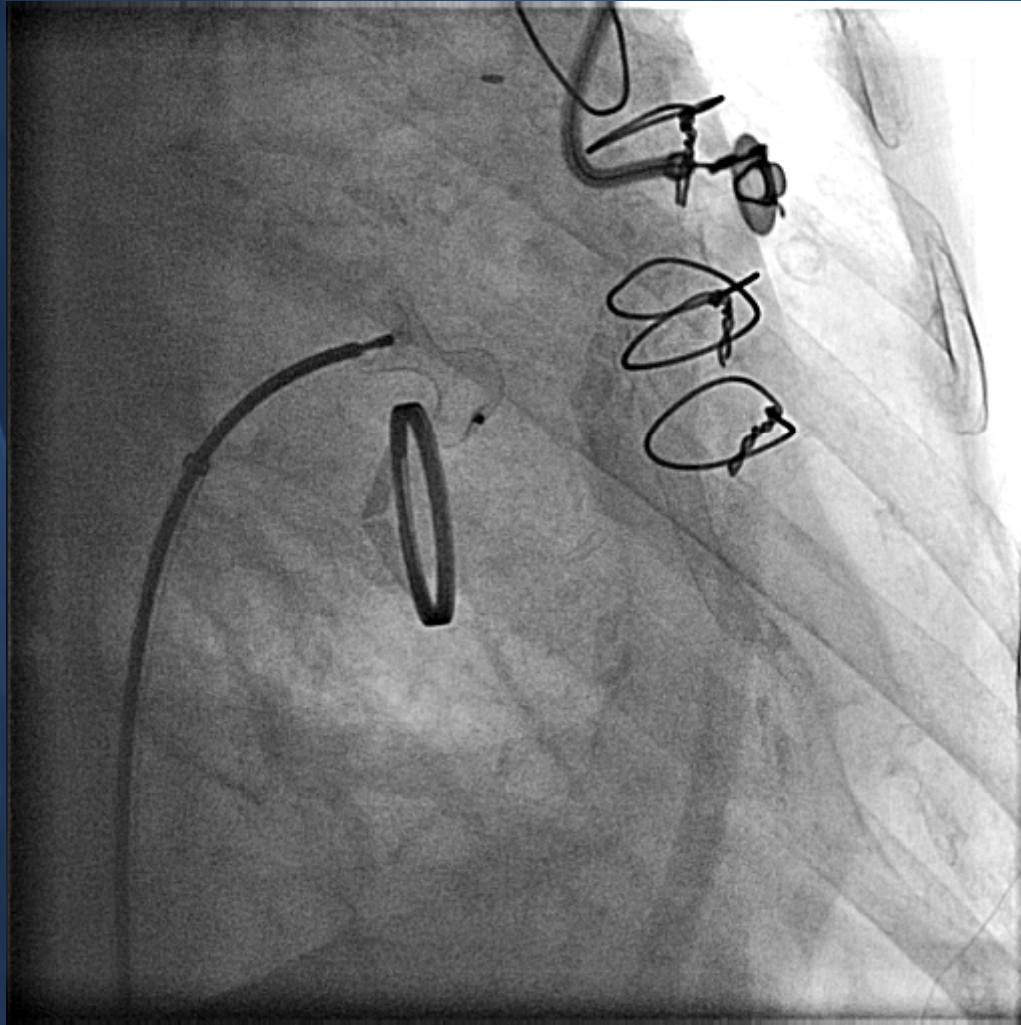
HR=201bpm



Follow-up Phone Call 1 month

“It’s a miracle”

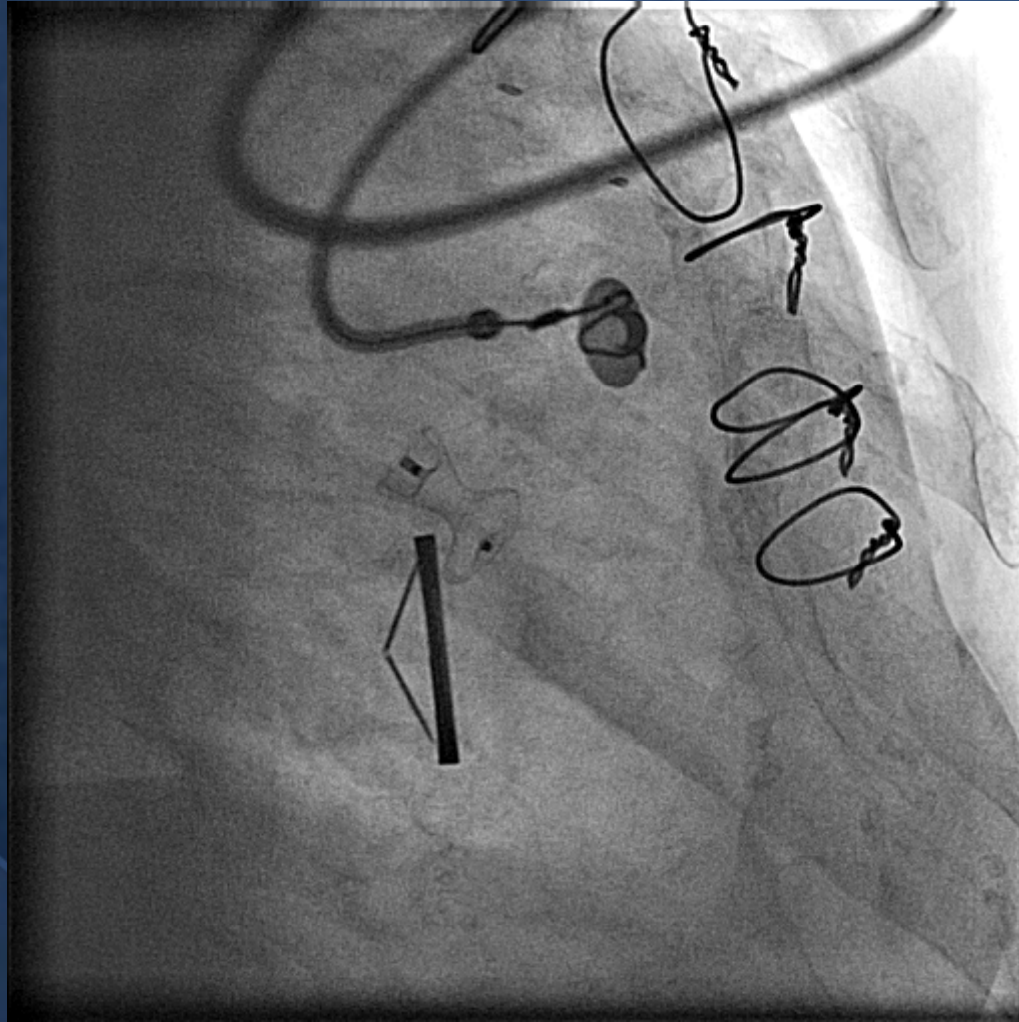
80F 27 mm St Jude



**Regurg Vol 50 ml
ERO 0.3 cm²
RVSP 60 mm Hg
NI LV function**

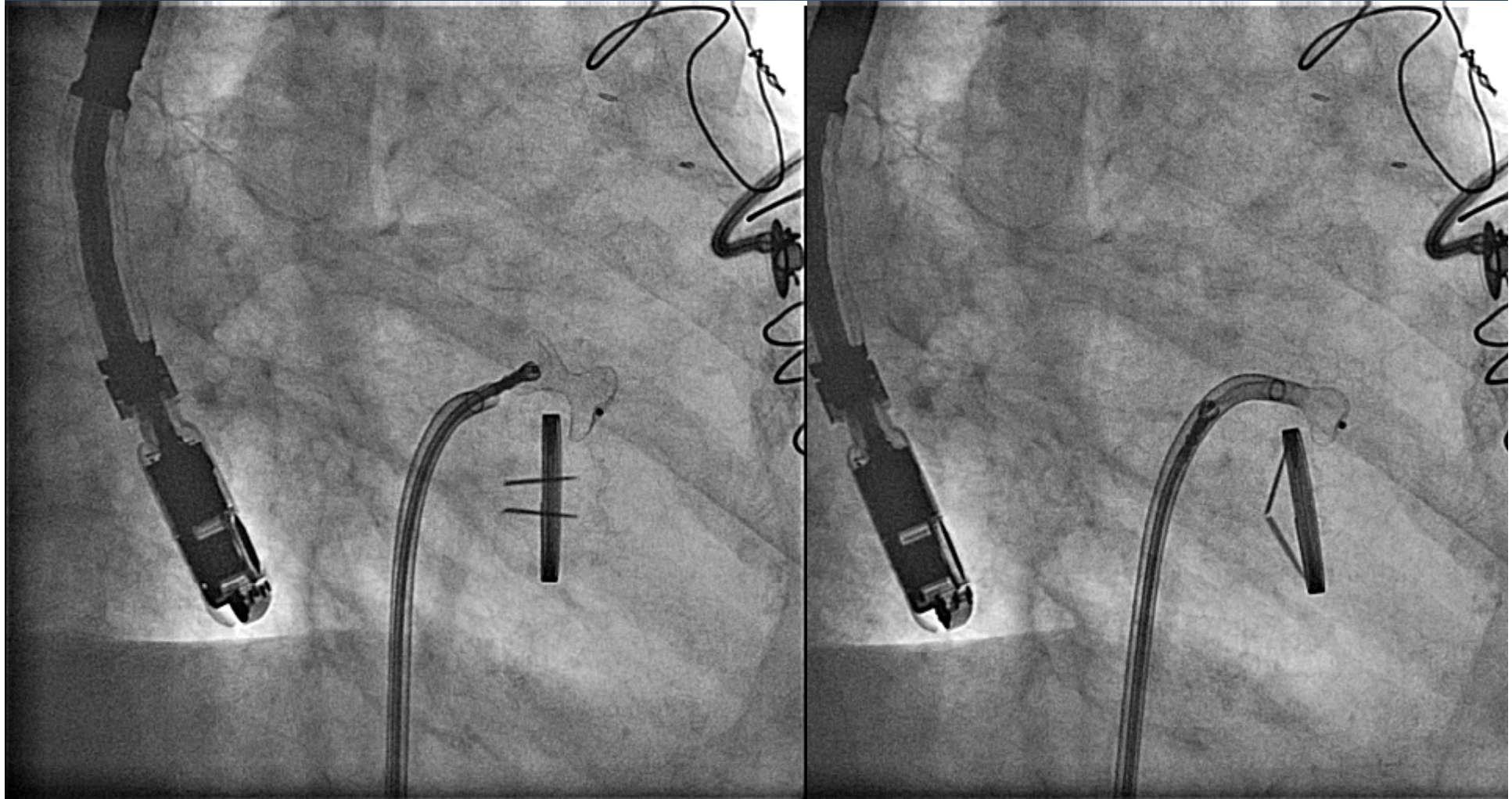
**Device placed
Quickly with good
Reduction in MR**

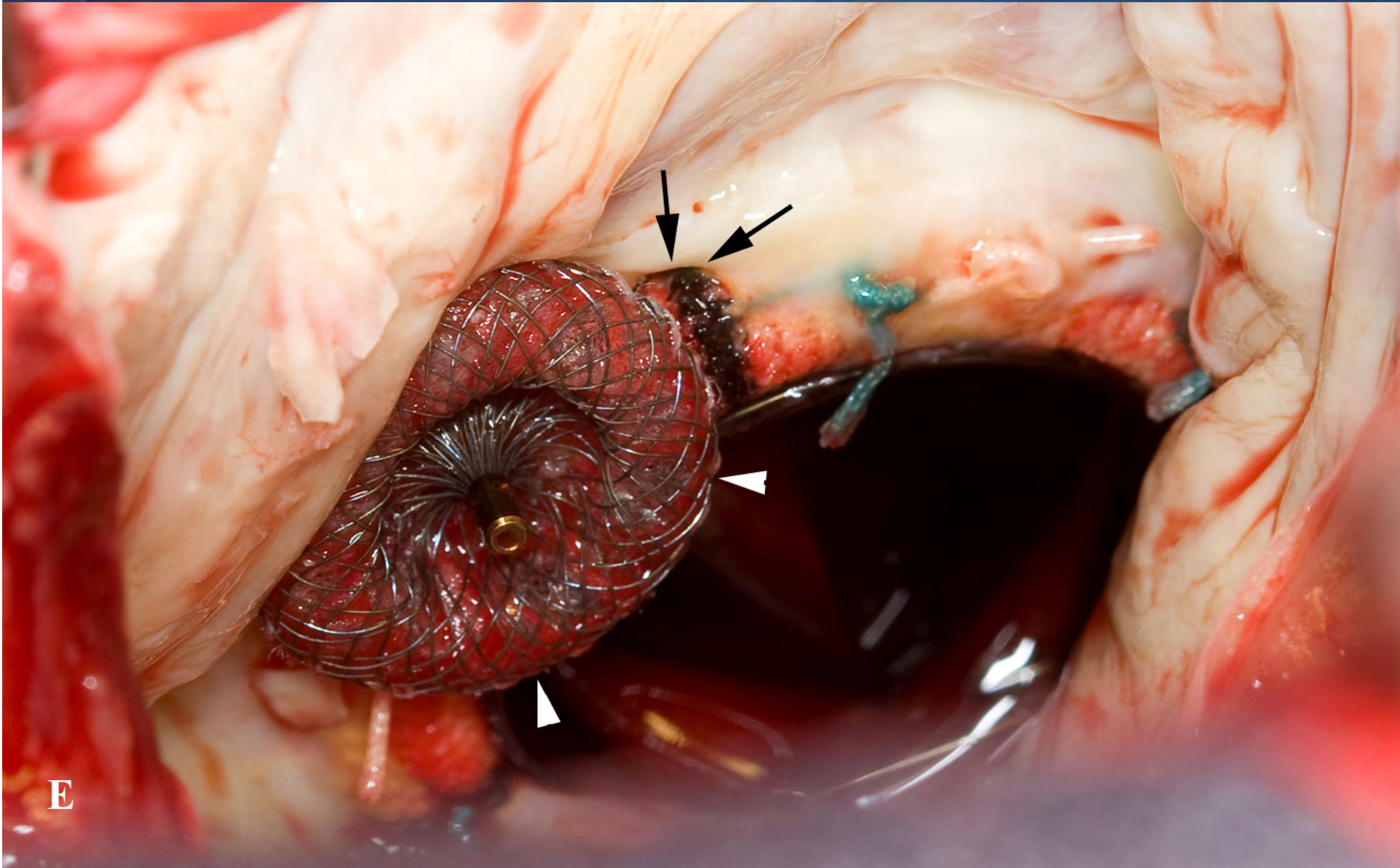
Phone call at 10 mins: “you’d better come back to the lab”



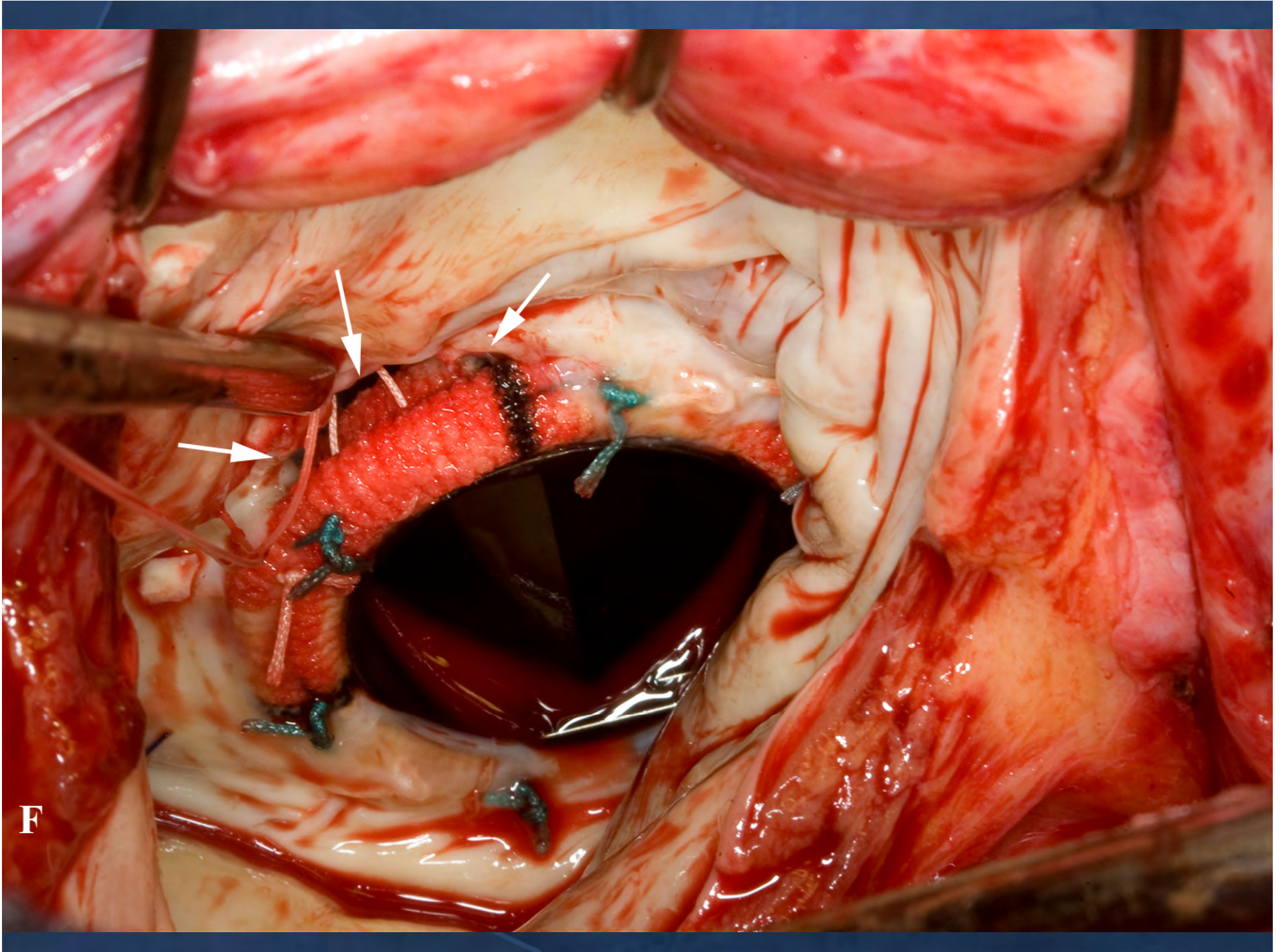
Necessity is the Mother of Invention

- Plato, The Republic






E



F

A Round Peg for a Crescentic Hole



FR 9Hz
8.4cm

Live 3D
3D 0%
3D 40dB
Gen



superior



LA
view

medial



D

10cm

Full Volume 0 130 180
3D 12%
3D 40dB



medial


LA
view



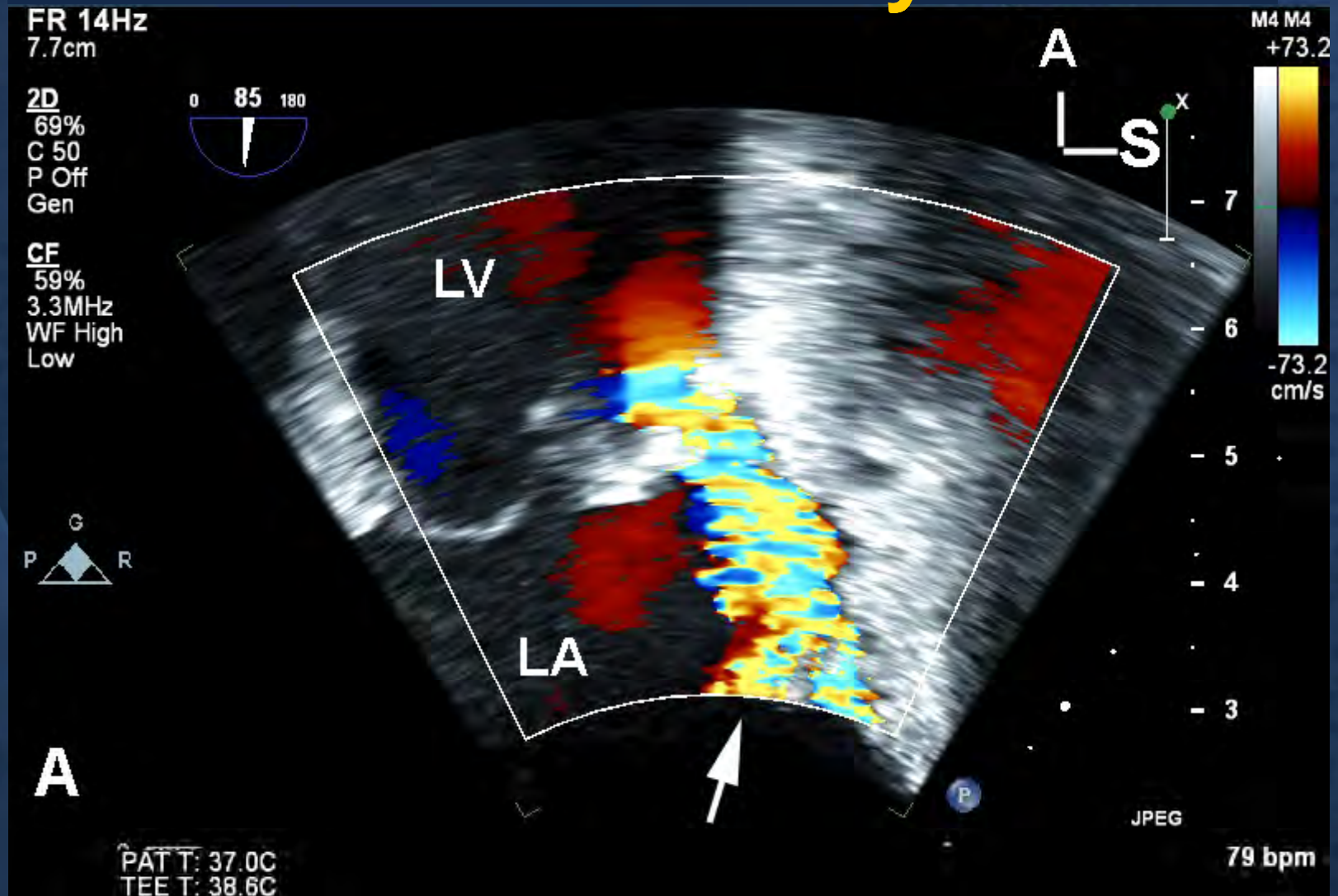
E 10 mm MVSD device with good result

JPEG

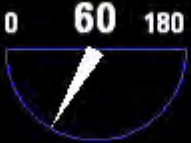PAT T: 37.0C
37.0C



86F Bioprosthetic MVR with CHF and Hemolysis



Live 3D
D 6%
D 40dB
Gen



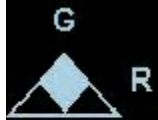Superior



12 mm AVP II
Good Result



Lateral



LA
view

B

PRINCIPLES

- **Comprehensive imaging**
- **Risk of alternatives**
- **Exclude infection**
- **Multidisciplinary approach**
- **Comfort with wide variety of techniques**

