

ECG markers of sudden death in Brugada syndrome

Leonardo Calo'

Divisione di Cardiologia
Policlinico Casilino - Roma



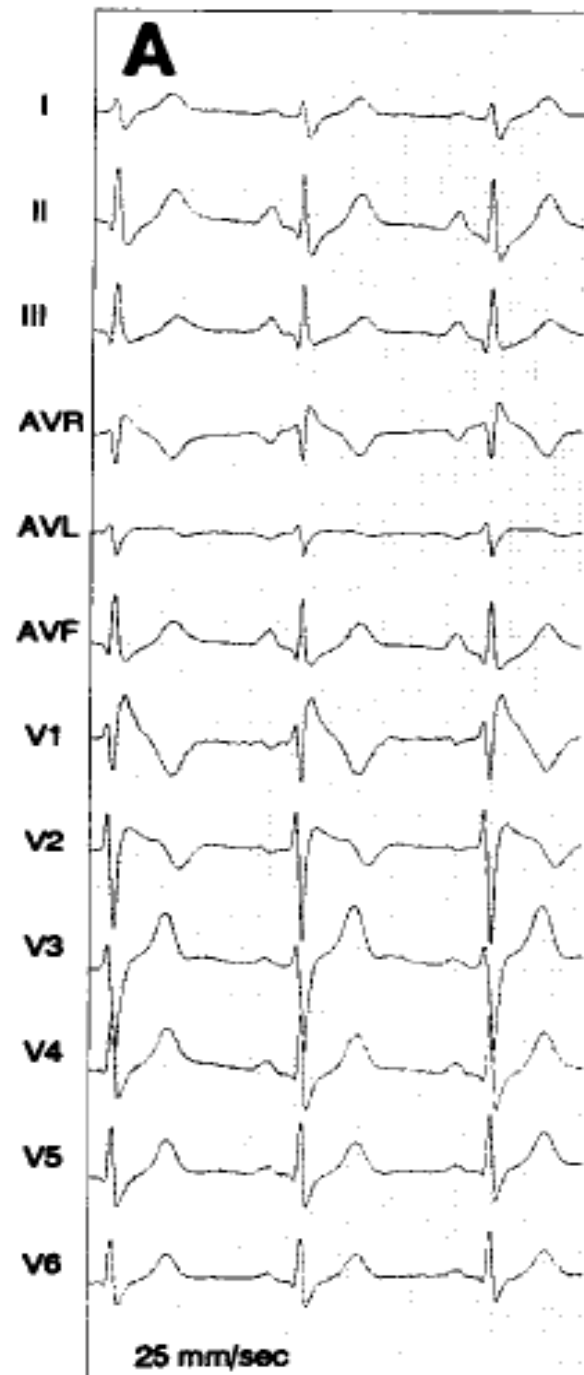
Long-Term Follow-Up of Individuals With the Electrocardiographic Pattern of Right Bundle-Branch Block and ST-Segment Elevation in Precordial Leads V₁ to V₃

Josep Brugada, MD, PhD; Ramon Brugada, MD; Charles Antzelevitch, PhD; Jeffrey Towbin, MD; Koonlawee Nademanee, MD; Pedro Brugada, MD, PhD

Background—The electrocardiographic pattern of right bundle-branch block with ST-segment elevation in leads V₁ to V₃ is increasingly recognized among patients who have aborted sudden cardiac death, but also in asymptomatic individuals, raising questions about its prognostic significance.

Methods and Results—The clinical, electrophysiological, and follow-up data of 334 patients with the Brugada phenotype were analyzed. A total of 79 women and 255 men with a mean age at diagnosis of 42 ± 16 years were studied. The abnormal ECG was recognized after a resuscitated cardiac arrest in 71 patients (group A), after a syncopal episode in 73 patients (group B), and in 190 asymptomatic individuals (group C). Sustained ventricular arrhythmias were inducible in 83%, 63%, and 33% of patients in group A, group B, and group C, respectively. During 54 ± 54 and 26 ± 36 months of follow-up, respectively, 62% of patients in group A and 19% of group B patients had a new arrhythmic event. Inducibility of ventricular arrhythmias was the only predictor of arrhythmia occurrence in both groups. During a mean follow-up of 27 ± 29 months, 8% of group C individuals had a first arrhythmic event. In these individuals, inducibility of ventricular arrhythmias and a basal abnormal ECG were predictors of arrhythmia occurrence.

Conclusions—An ECG showing right bundle-branch block and ST-segment elevation in the right precordial leads is a marker of malignant ventricular arrhythmias and sudden death. Recurrence of malignant arrhythmias is high after the occurrence of symptoms. Among asymptomatic individuals, those with a spontaneously abnormal ECG and inducible to ventricular arrhythmias have the poorer prognosis. (*Circulation*. 2002;105:73-78.)



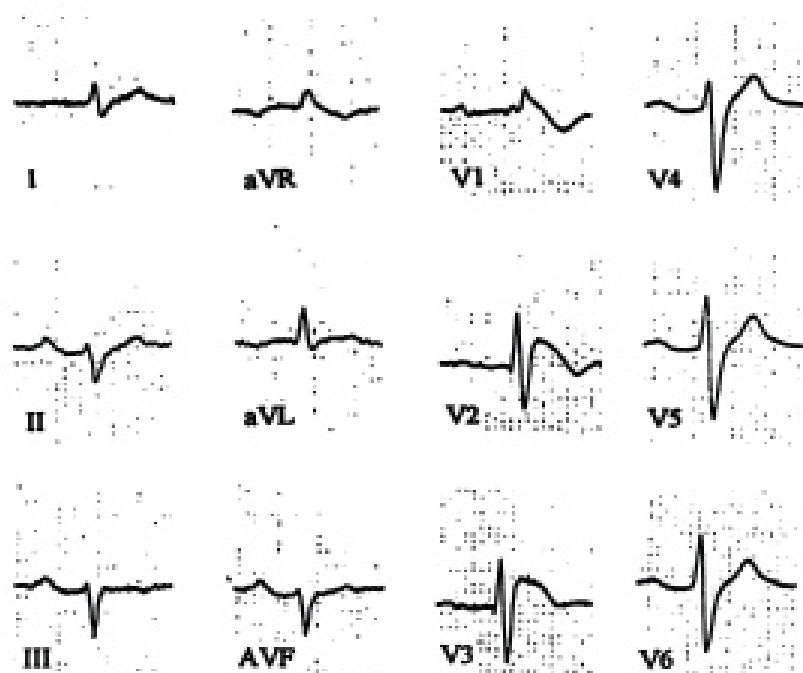
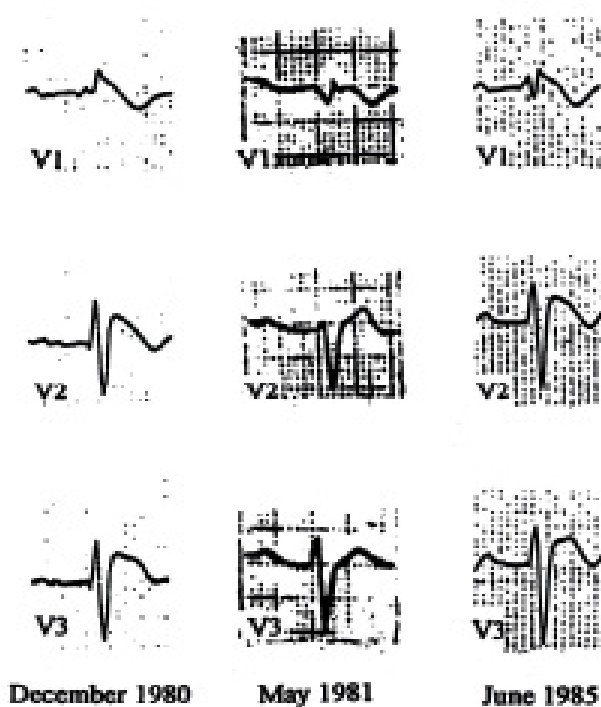
Right Bundle Branch Block, Right Precordial ST-Segment Elevation, and Sudden Death in Young People

Domenico Corrado, MD; Cristina Basso, MD, PhD; Gianfranco Buja, MD; Andrea Nava, MD;
Lino Rossi, MD; Gaetano Thiene, MD

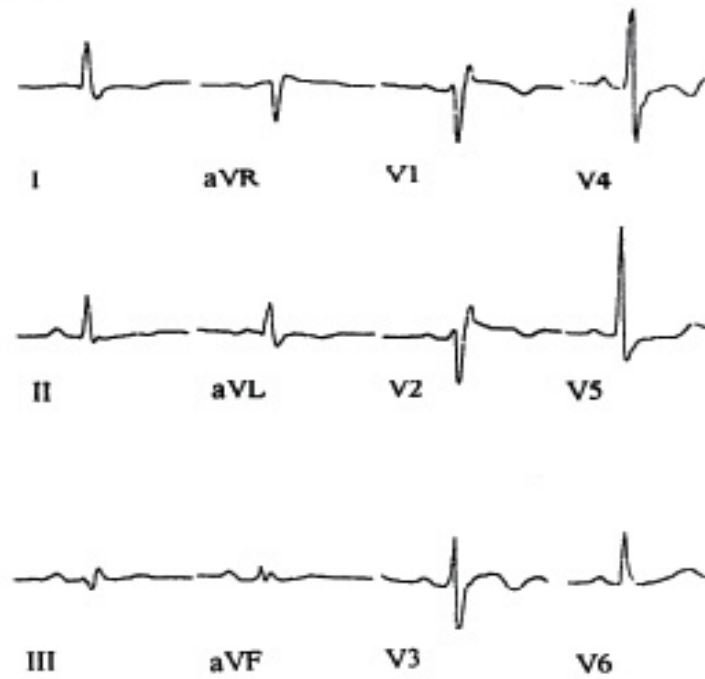
Background—Patients with the ECG pattern of right bundle branch block and right precordial ST-segment elevation may experience sudden death in the setting of either arrhythmogenic right ventricular cardiomyopathy (ARVC) or a functional electrical disorder such as Brugada syndrome.

Methods and Results—Among a series of 273 young (≤ 35 years) victims of cardiovascular sudden death who were prospectively studied from 1979 to 1998 in the Veneto Region of Italy, 12-lead ECG was available in 96 cases. Thirteen (14%; 12 males and 1 female aged 24 ± 8 years) had right precordial ST-segment elevation, either isolated (9 cases) or associated with right bundle branch block (4 cases). At autopsy, all patients had ARVC (92%) except one, who had no evidence of structural heart disease. Compared with the 19 young sudden death victims with ARVC and no ST-segment abnormalities from the same series, those with ARVC and right precordial ST-segment elevation included fewer competitive athletes (17% versus 58%; $P=0.03$), more often died suddenly at rest or during sleep (83% versus 26%; $P=0.003$), and showed serial ECG changes over time (83% versus 0; $P=0.015$), polymorphic ventricular tachycardia (33% versus 0; $P=0.016$), and predominant fatty replacement of the right ventricular anterior wall (58% versus 21%; $P=0.05$).

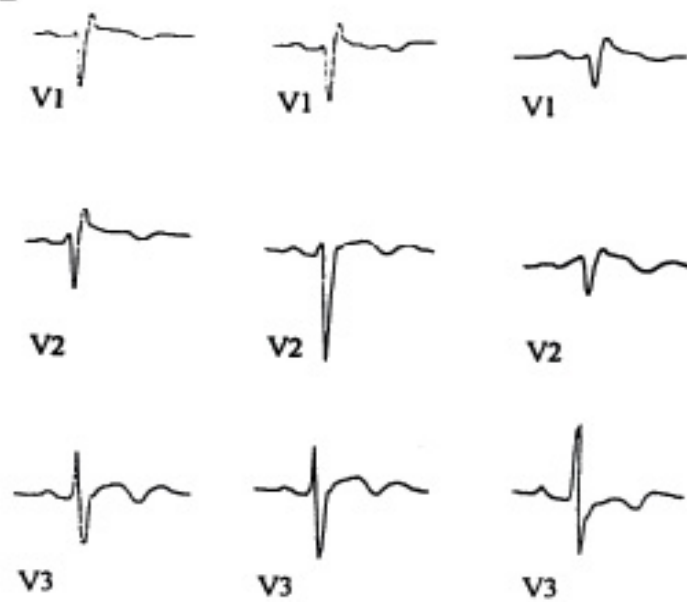
Conclusions—Right precordial ST-segment elevation was found in 14% of young sudden death victims with available ECG. It mostly reflected underlying ARVC with predominant right ventricular anterior wall involvement and characterized a subgroup of patients who share with Brugada patients the propensity to die from non-exercise-related cardiac arrest and to exhibit dynamic ECG changes and polymorphic ventricular tachycardia. (*Circulation*. 2001;103:710-717.)

A**B**

A



B



RIPOLARIZZAZIONE

Prevalence of early repolarization pattern in inferolateral leads in patients with Brugada syndrome

Konstantinos P. Letsas, MD,* Frédéric Sacher, MD,[†] Vincent Probst, MD, PhD,^{‡§¶}
Reinhold Weber, MD,* Sébastien Knecht, MD,[†] Dietrich Kalusche, MD,* Michel Haïssaguerre, MD,[†]
Thomas Arentz, MD*

*From the *Arrhythmia Service, Herz-Zentrum, Bad Krozingen, Germany, [†]Université Bordeaux II, Hôpital Cardiologique du Haut-Lévêque, Bordeaux-Pessac, and [‡]INSERM, [§]Université de Nantes, and [¶]CHU Nantes, L'Institut du Thorax, Service de Cardiologie, Nantes, France.*

BACKGROUND Recent data have shown a high incidence of the early repolarization pattern confined in inferolateral leads in patients with idiopathic ventricular fibrillation.

OBJECTIVES The purpose of the present study was to investigate the prevalence and the prognostic significance of the early repolarization pattern in inferolateral leads in patients with Brugada syndrome.

METHODS Clinical, genetic, and electrophysiologic data from 290 individuals (223 males, mean age 48.3 ± 14.2 years) with a spontaneous or drug-induced type 1 electrocardiogram (ECG) pattern of Brugada syndrome and structurally normal hearts were analyzed. Twelve-lead ECGs were evaluated for the presence of early repolarization pattern, which was defined as J-point elevation of at least 0.1 mV from baseline in at least two inferior or lateral leads. Follow-up data were obtained for all subjects.

RESULTS An early repolarization pattern manifested as notched or slurred J-point elevation mainly in lateral leads was observed in 35 subjects (12%). The prevalence of the early repolarization

pattern was significantly higher in male subjects ($P = .004$). During a mean follow-up period of 44.9 ± 27.5 months, 22 subjects (8%) displayed an arrhythmic event including sudden cardiac death. There were no significant differences regarding spontaneous ECG type of Brugada syndrome, symptoms, family history of sudden cardiac death, and positive genetic test between subjects with and without the early repolarization pattern. The presence of early repolarization pattern was not associated with arrhythmic events during follow-up (Hazard ratio [HR] 1.090; 95% confidence interval 0.349–3.403; $P = .882$).

CONCLUSION The early repolarization pattern in inferolateral leads is not an uncommon finding in Brugada syndrome. In our population, the early repolarization features were not associated with a worse outcome in subjects with Brugada syndrome.

KEYWORDS Brugada syndrome; Early repolarization syndrome; Syncope; Sudden cardiac death

(Heart Rhythm 2008;5:1685–1689) © 2008 Heart Rhythm Society. All rights reserved.

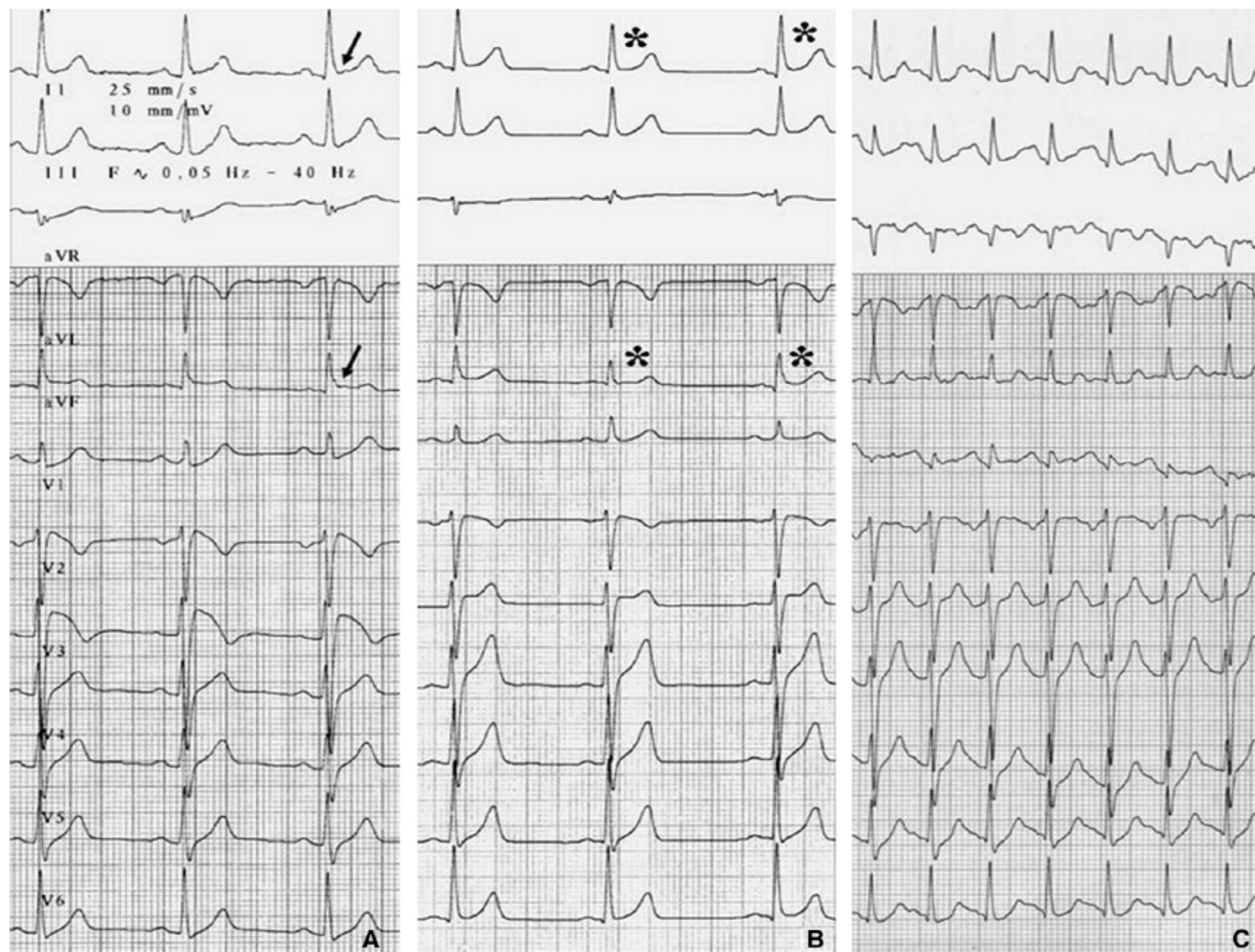


Figure 1 ECG recordings from the same subject showing (A) spontaneous type 1 ECG of BS and ER pattern in lateral leads (*arrows*); (B) beat-to-beat variations of the ER pattern (*asterisks*); and (C) elimination of the ER features during exercise testing.

$T_{\text{peak}}-T_{\text{end}}$ interval and $T_{\text{peak}}-T_{\text{end}}/\text{QT}$ ratio as markers of ventricular tachycardia inducibility in subjects with Brugada ECG phenotype

Konstantinos P. Letsas*, Reinhold Weber, Klaus Astheimer, Dietrich Kalusche, and Thomas Arentz

Abteilung Rhythmologie, Herz-Zentrum, Südring 15, 79189 Bad Krozingen, Germany

Received 12 August 2009; accepted after revision 15 October 2009; online publish-ahead-of-print 6 November 2009

Aims

The present study investigated whether several ECG markers of ventricular repolarization are associated with ventricular tachycardia/fibrillation (VT/VF) inducibility in subjects with type 1 ECG pattern of Brugada syndrome (BS).

Methods and results

The clinical data of 23 individuals (19 males, age 42.69 ± 14.63) with spontaneous ($n = 10$) or drug-induced ($n = 13$) type 1 ECG pattern of BS who underwent programmed ventricular stimulation were analysed. Sustained VT/VF was induced in 17 subjects (74%) and was significantly associated with the presence of spontaneous type 1 ECG of BS ($P = 0.012$). Among the studied ECG repolarization markers, subjects with inducible VT/VF displayed an increased $T_{\text{peak}}-T_{\text{end}}$ interval in leads V_2 (88.82 ± 15.70 vs. 78.33 ± 4.08 ms, $P = 0.02$) and V_6 (76.33 ± 10.08 vs. 66.66 ± 5.16 ms, $P = 0.04$) and a greater $T_{\text{peak}}-T_{\text{end}}/\text{QT}$ ratio in lead V_6 (0.214 ± 0.028 vs. 0.180 ± 0.014 , $P = 0.009$) compared with those without arrhythmias. Ventricular tachycardia/fibrillation inducibility was not associated with arrhythmic events during a mean follow-up period of 4.61 ± 2.14 years ($P = 0.739$).

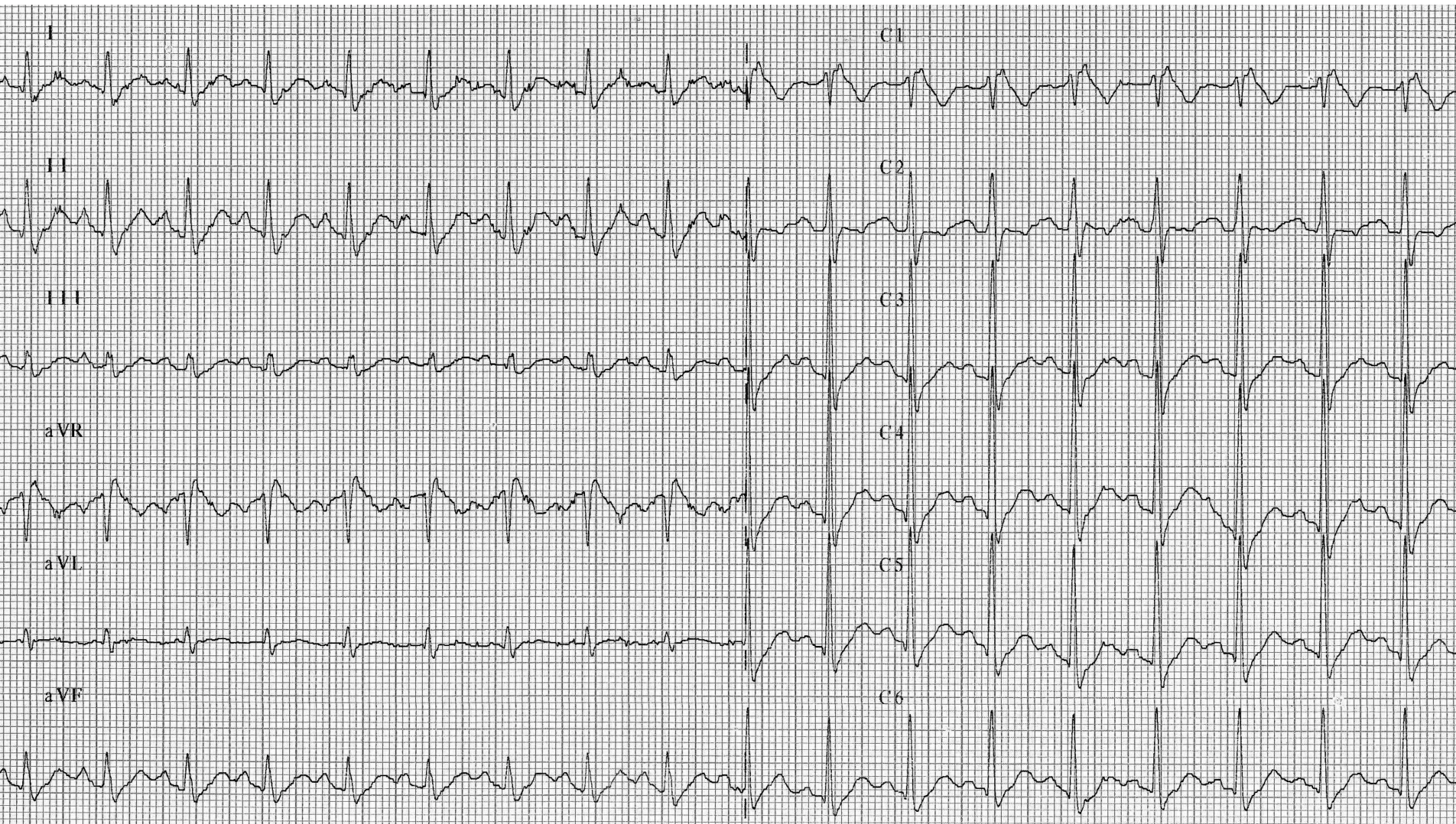
Conclusion

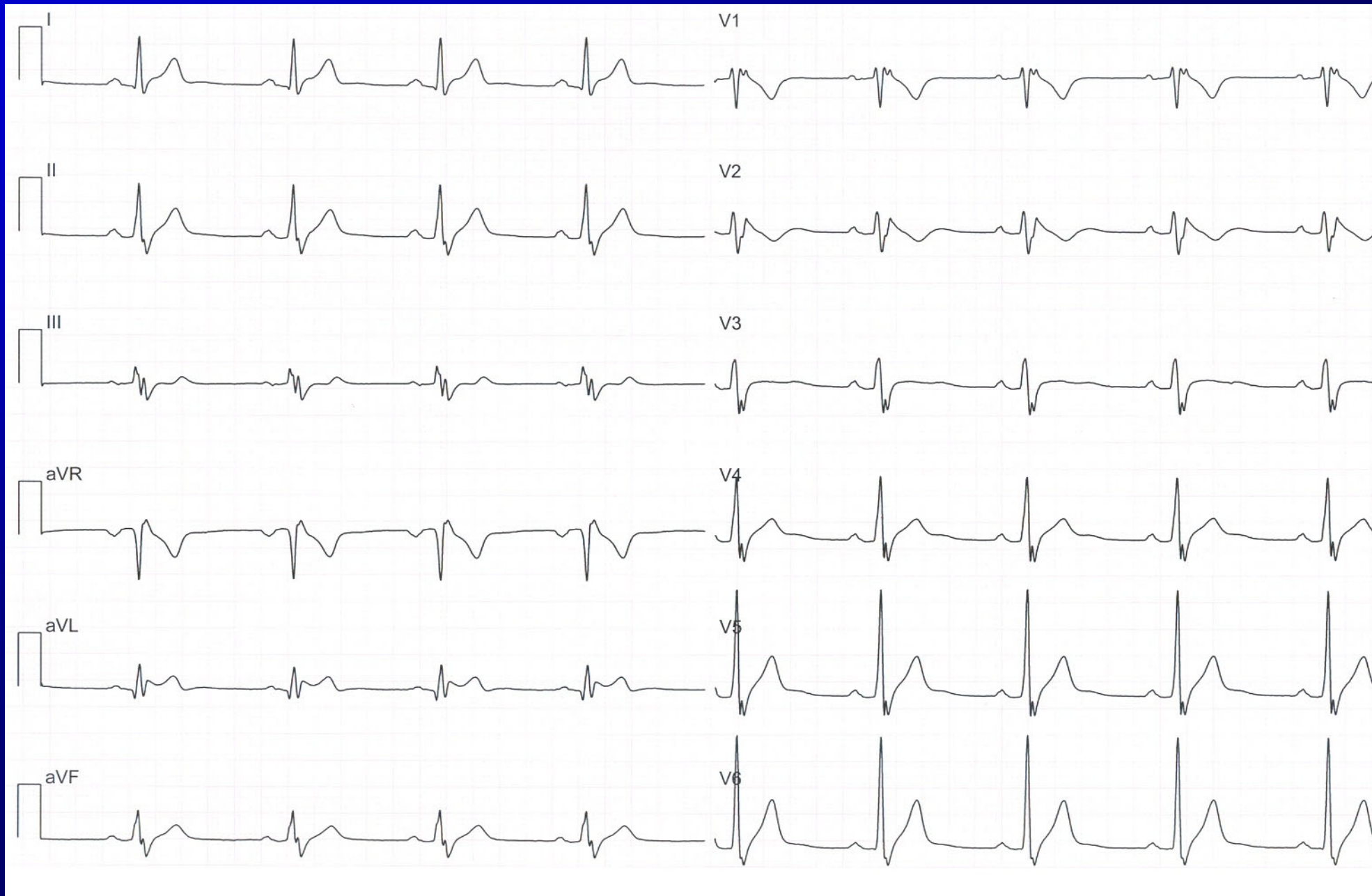
The $T_{\text{peak}}-T_{\text{end}}$ interval and $T_{\text{peak}}-T_{\text{end}}/\text{QT}$ ratio were associated with VT/VF inducibility in BS. The utility of $T_{\text{peak}}-T_{\text{end}}/\text{QT}$ ratio as a new marker of arrhythmogenesis in BS requires further studies, including a large number of patients.

Keywords

$T_{\text{peak}}-T_{\text{end}}$ interval • $T_{\text{peak}}-T_{\text{end}}/\text{QT}$ ratio • Brugada syndrome • Ventricular arrhythmias • Electrophysiological study

DEPOLARIZZAZIONE





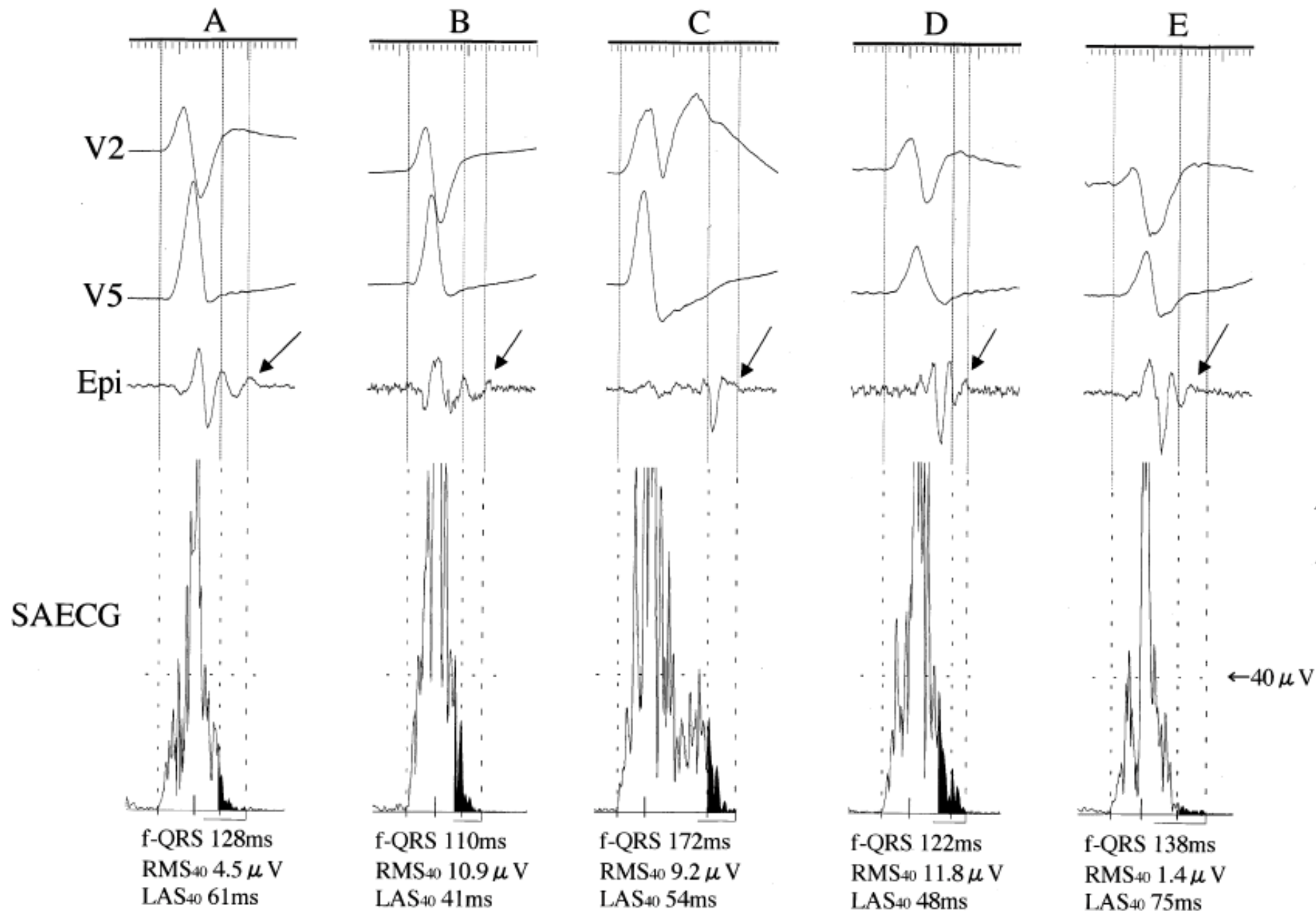
Epicardial Electrogram of the Right Ventricular Outflow Tract in Patients With the Brugada Syndrome

Using the Epicardial Lead

Satoshi Nagase, MD, Kengo Fukushima Kusano, MD, PhD, Hiroshi Morita, MD, PhD, Yoshihisa Fujimoto, MD, PhD, Mikio Kakishita, MD, PhD, Kazufumi Nakamura, MD, PhD, Tetsuro Emori, MD, Hiromi Matsubara, MD, PhD, Tohru Ohe, MD, PhD, FACC

Okayama, Japan

-
- | | |
|--------------------|---|
| OBJECTIVES | We tried to record an epicardial electrogram directly, and we examined local electrograms before and after administration of a class IC anti-arrhythmic drug in patients with the Brugada syndrome. |
| BACKGROUND | Electrical heterogeneity of the epicardium in the right ventricular outflow tract (RVOT) has been thought to be related to the Brugada syndrome. However, an epicardial abnormality has not been demonstrated in patients with the Brugada syndrome. |
| METHODS | In five patients with a Brugada-type electrocardiogram (ECG), local unipolar electrograms were recorded at the epicardium and endocardium of the RVOT. To record the epicardial electrogram directly, we introduced an electrical guidewire into the conus branch (CB) of the right coronary artery. The duration of the local electrogram after termination of the QRS complex (DP) was measured before and after class IC anti-arrhythmic drug administration. The signal-averaged electrocardiogram (SAECG) was also obtained in all patients. |
| RESULTS | A definite DP was observed at the epicardium, but not at the endocardium. After administration of a class IC anti-arrhythmic drug, the DP at the epicardium was prolonged from 38 ± 10 ms to 67 ± 24 ms. The late potential corresponding to the DP at the epicardium was observed in all patients on the SAECG. |
| CONCLUSIONS | An epicardial electrogram can be recorded from the CB. Recording from the CB enables identification of an epicardial abnormality in patients with the Brugada syndrome. These abnormal electrograms may be related to a myocardial abnormality in the epicardium of patients with the Brugada syndrome. (J Am Coll Cardiol 2002;39:1992-5) © 2002 by the American College of Cardiology Foundation |
-



Clinical Characteristics and Risk Stratification in Symptomatic and Asymptomatic Patients with Brugada Syndrome: Multicenter Study in Japan

MASAHICO TAKAGI, M.D., PH.D.,* YASUHIRO YOKOYAMA, M.D.,†
KAZUTAKA AONUMA, M.D., PH.D.,‡ NAOHIKO AIHARA, M.D.,§
and MASAYASU HIRAOKA, M.D., PH.D.,¶

for the Japan Idiopathic Ventricular Fibrillation Study (J-IVFS) Investigators

From the *Department of Internal Medicine and Cardiology, Osaka City University Graduate School of Medicine, Osaka; †Division of Cardiology, National Disaster Medical Center, Tachikawa; ‡Department of Internal Medicine, Cardiovascular Division, Institute of Clinical Medicine, University of Tsukuba, Tsukuba; §Division of Cardiology, Department of Internal Medicine, National Cardiovascular Center, Suita; and ¶Tokyo Medical and Dental University, Tokyo, Japan

Risk Stratification in Brugada Syndrome. *Background:* Neither the clinical characteristics nor risk stratification in Brugada syndrome have been clearly determined. We compared the clinical and ECG characteristics of symptomatic and asymptomatic patients with Brugada syndrome to identify new markers for high-risk patients.

Methods: A total of 188 consecutive individuals with Brugada syndrome (mean age 53 ± 14 years, 178 males) were enrolled in the Japan Idiopathic Ventricular Fibrillation Study (J-IVFS). Clinical and ECG characteristics were evaluated in three groups of patients: Ventricular fibrillation (VF) group: patients with documented VF (N = 33); Syncope (Sy) group: patients with syncope without documented VF (N = 57); and asymptomatic (As) group: subjects without symptoms (N = 98). Their prognostic parameters were evaluated over a 3-year follow-up period.

Results: (1) Clinical characteristics: incidence of past history of atrial fibrillation (AF) was significantly higher in the VF and Sy groups than in the AS group ($P = 0.04$). (2) On 12-lead ECG, r-J interval in lead V2 and QRS duration in lead V6 were longest in the VF group ($P = 0.001, 0.002$, respectively). (3) Clinical follow-up: during a mean follow-up period of 37 ± 16 months, incidences of cardiac events (sudden death and/or VF) were higher in the symptomatic (VF/Sy) groups than in the As group ($P < 0.0001$). The r-J interval in lead V2 ≥ 90 ms and QRS duration in lead V6 ≥ 90 ms were found to be possible predictors of recurrence of cardiac events in symptomatic patients.

Conclusions: Prolonged QRS duration in precordial leads was prominent in symptomatic patients. This ECG marker may be useful for distinguishing high- from low-risk patients with Brugada syndrome. (*J Cardiovasc Electrophysiol*, Vol. 18, pp. 1244-1251, December 2007.)

Differences in 12-Lead Electrocardiogram Between Symptomatic and Asymptomatic Brugada Syndrome Patients

M. JUHANI JUNTILA, M.D.,* PEDRO BRUGADA, M.D.,† KUI HONG, M.D.,‡
ERIC LIZOTTE, M.SC.,|| MARC DE ZUTTER, M.D.,† ANDREA SARKOZY, M.D.,†
JOSEP BRUGADA, M.D.,§ BEGONA BENITO, M.D.,§ JUHA S. PERKIOMAKI, M.D.,*
TIMO H. MÄKIKALLIO, M.D.,* HEIKKI V. HUIKURI, M.D.,*
and RAMON BRUGADA, M.D.||

From the *Division of Cardiology, Department of Medicine, University of Oulu, Finland; †Heart Rhythm Management Institute, UZ Brussel-VUB, Brussels, Belgium; ‡Nanchang University, Nanchang, China; §Cardiology Department, Thorax Institute, Hospital Clínic, Barcelona, Spain; and ||Montreal Heart Institute, Montreal, Canada

Differences in 12-Lead ECG Between Symptomatic and Asymptomatic BrS. *Introduction:* Brugada syndrome (BrS) is an inherited disorder that predisposes some subjects to sudden cardiac death (SCD). It is not well established which BrS patients are at risk of severe arrhythmias. Our aim was to study whether standard 12-lead electrocardiogram (ECG) would give useful information for this purpose.

Methods: This study included 200 BrS probands (142 male, 62%; mean age 42 ± 16 years). Symptoms related to BrS were defined as syncope, documented ventricular tachyarrhythmia, or SCD. We determined PR, QRS, QTc, T_{peak}, and T_{end} interval from leads II and V₂ and QRS from lead V₅, R'/S ratio from lead aVR (aVR sign), QRS axis, and J-point elevation amplitude from right precordial leads from the baseline ECGs.

Results: Sixty-six subjects (33%) had experienced symptoms related to BrS. The only significant difference between the symptomatic and asymptomatic BrS subjects was the QRS duration measured from lead II or lead V₂, for example, the mean QRS in V₂ was 115 ± 26 ms in symptomatic versus 104 ± 19 ms in asymptomatic patients ($P < 0.001$). The optimized cut-off point of V₂ QRS ≥ 120 ms gave an odds ratio (OR) of 2.5 (95% CI: 1.4–4.6, $P = 0.003$) for being symptomatic. In a multivariate analysis adjusted with gender, age, and SCN5A mutation, the OR was 2.6 (95% CI: 1.4–4.8, $P = 0.004$).

Conclusion: Prolonged QRS duration, measured from standard 12-lead ECG, is associated with symptoms and could serve as a simple noninvasive risk marker of vulnerability to life-threatening ventricular arrhythmias in BrS. (*J Cardiovasc Electrophysiol*, Vol. 19, pp. 380-383, April 2008)

Conduction Delay in Right Ventricle as a Marker for Identifying High-Risk Patients With Brugada Syndrome

ATSUSHI DOI, M.D., MASAHIKO TAKAGI, M.D., KEIKO MAEDA, M.D.,
HIROAKI TATSUMI, M.D., KENJI SHIMENO, M.D., and MINORU YOSHIYAMA, M.D.

From the Department of Internal Medicine and Cardiology, Osaka City University Graduate School of Medicine, Osaka, Japan

Conduction Delay as a Marker for Brugada Syndrome. *Objectives:* To evaluate the significance of conduction delay (CD) in the right ventricle (RV) in Brugada syndrome (BS) as a marker for risk stratification of sudden death.

Methods: Twenty-five patients with BS (7 with documented ventricular fibrillation (VF), 8 with syncope, and 10 without symptoms) and 10 control subjects were paced from the RV apex using 8 beats of drive pacing and a single extra-stimulus. CDs in the right ventricular outflow tract (RVOT) (CD-RV) and in the lateral left ventricle (L-LV) (CD-LV), and the local electrogram durations at a single extra-stimulus in RVOT (D-RV) and L-LV (D-LV) were calculated. We also evaluated changes in 12-lead ECG parameters in 16 patients with BS after pilsicainide challenge test (Pilsicainide-test).

Results: Maximal CD-RV and maximal D-RV were significantly larger than maximal CD-LV and maximal D-LV in BS (26 ± 10 and 105 ± 15 vs 20 ± 6 and 92 ± 15 ms, $P < 0.05$, respectively). Maximal CD-RV and maximal D-RV in patients with documented VF were the largest among the 3 groups. There was a significant positive correlation between maximal CD-RV or maximal D-RV and changes in QRS duration in leads V2 and V5 and in S wave duration in lead II and V5 after Pilsicainide-test (CD-RV; $r = 0.54, 0.51, 0.56$, and 0.53 ; D-RV; $r = 0.55, 0.5, 0.57$, and 0.53 , $P < 0.05$, respectively). In control subjects, there were no significant differences.

Conclusions: CD in RV was a useful marker for identifying high-risk patients with BS. CD in the RV, especially in the RVOT epicardium, may be related to arrhythmias in BS. (*J Cardiovasc Electrophysiol*, Vol. 21, pp. 688-696, June 2010)

Prevalence and Prognostic Role of Various Conduction Disturbances in Patients With the Brugada Syndrome

Philippe Maury, MD^{a,*}, Anne Rollin, MD^a, Frédéric Sacher, MD^b, Jean-Baptiste Gourraud, MD^c, Franck Raczka, MD^d, Jean-Luc Pasquié, MD^d, Alexandre Duparc, MD^a, Pierre Mondoly, MD^a, Christelle Cardin, MD^a, Marc Delay, MD^a, Nicolas Derval, MD^b, Stéphanie Chatel, PhD^c, Vanina Bongard, MD, PhD^a, Marie Sadron, MD^a, Arnaud Denis, MD^b, Jean-Marc Davy, MD^d, Méléze Hocini, MD^b, Pierre Jaïs, MD^b, Laurence Jesel, MD^b, Michel Haïssaguerre, MD^b, and Vincent Probst, MD^c

Prevalence and prognostic value of conduction disturbances in patients with the Brugada syndrome (BrS) remains poorly known. Electrocardiograms (ECGs) from 325 patients with BrS (47 ± 13 years, 258 men) with spontaneous ($n = 143$) or drug-induced ($n = 182$) type 1 ECG were retrospectively reviewed. Two hundred twenty-six patients (70%) were asymptomatic, 73 patients (22%) presented with unexplained syncope, and 26 patients (8%) presented with sudden death or implantable cardioverter-defibrillator appropriated therapies at diagnosis or during a mean follow-up of 48 ± 34 months. P-wave duration of ≥ 120 ms was present in 129 patients (40%), first degree atrioventricular block (AVB) in 113 (35%), right bundle branch block (BBB) in 90 (28%), and fascicular block in 52 (16%). Increased P-wave duration, first degree AVB, and right BBB were more often present in patients after drug challenge than in patients with spontaneous type 1 ST elevation. Left BBB was present in 3 patients. SCN5A mutation carriers had longer P-wave duration and longer PR and HV intervals. In multivariate analysis, first degree AVB was independently associated with sudden death or implantable cardioverter-defibrillator appropriated therapies (odds ratio 2.41, 95% confidence interval 1.01 to 5.73, $p = 0.046$) together with the presence of syncope and spontaneous type 1 ST elevation. In conclusion, conduction disturbances are frequent and sometimes diffuse in patients with BrS. First degree AVB is independently linked to outcome and may be proposed to be used for individual risk stratification. © 2013 Elsevier Inc. All rights reserved. (Am J Cardiol 2013;112:1384–1389)



Fragmented QRS as a Marker of Conduction Abnormality and a Predictor of Prognosis of Brugada Syndrome

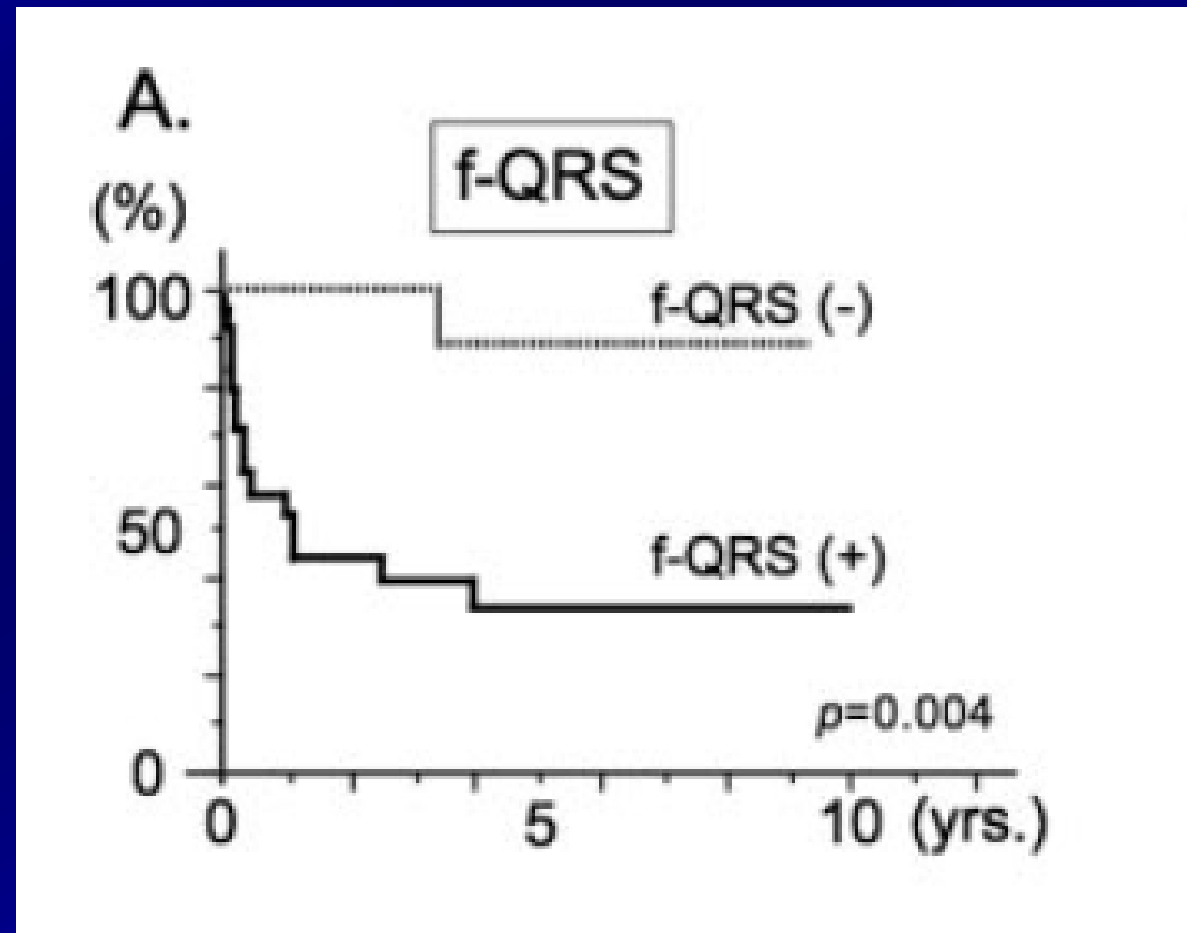
Hiroshi Morita, Kengo F. Kusano, Daiji Miura, Satoshi Nagase, Kazufumi Nakamura, Shiho T. Morita, Tohru Ohe, Douglas P. Zipes and Jiashin Wu

Circulation 2008;118:1697-1704; originally published online Oct 6, 2008;

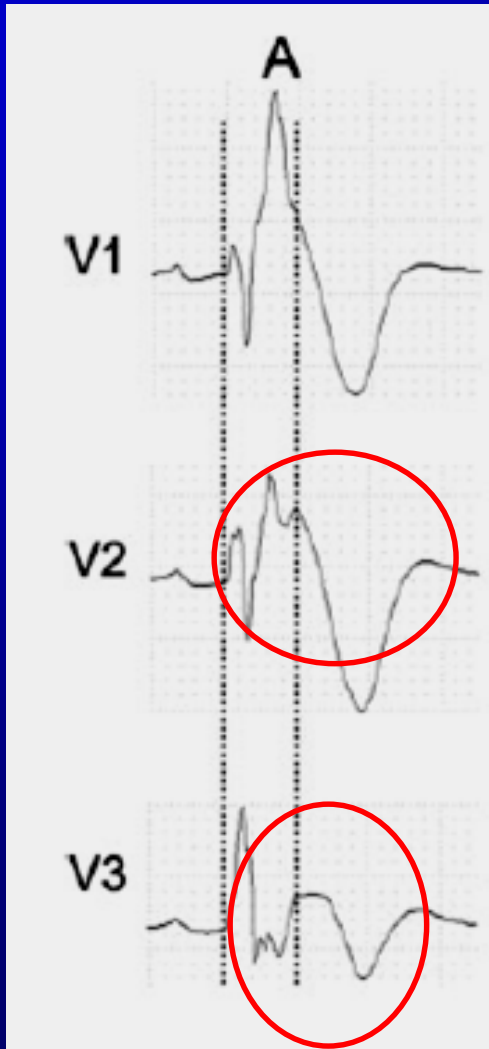
DOI: 10.1161/CIRCULATIONAHA.108.770917

Only 6% of patients without f-QRS experienced VF during follow-up.

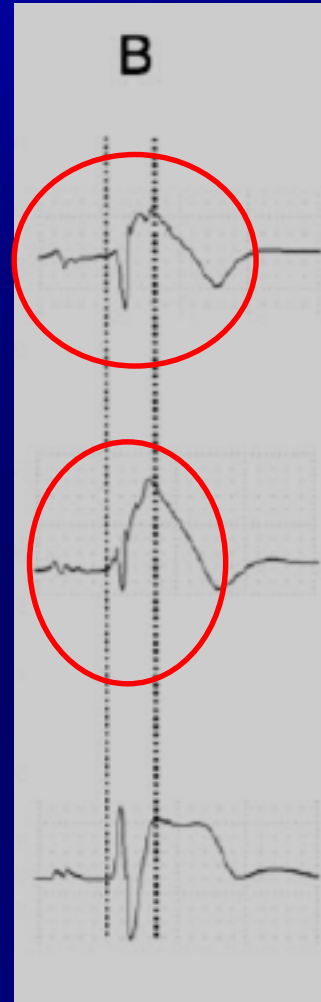
58% of patients with f-QRS had recurrent syncope due to VF ($p < 0.01$).



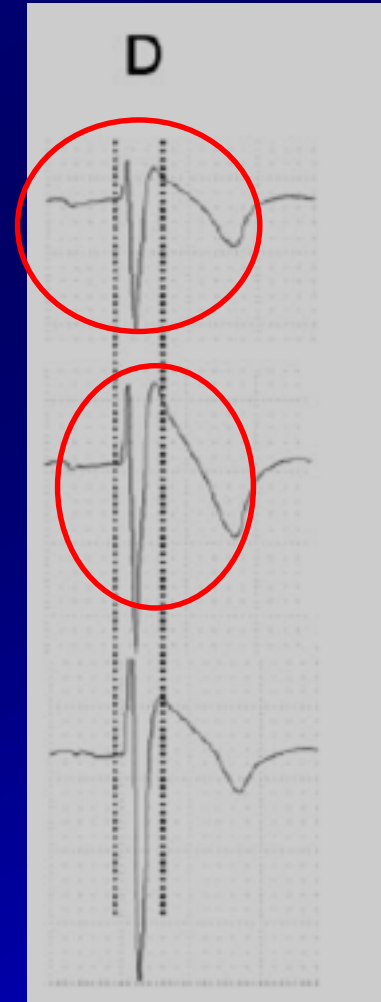
Example of f-QRS in Brugada syndrome.



Multiple spikes between the R wave and the end of the QRS complex in leads V2 and V3.



Multiple spikes observed at the upstroke of the S wave in leads V1 and V2.



No sign of f-QRS. Right precordial lead showed rSr pattern without multiple spikes in the QRS complex.

Electrocardiographic Parameters and Fatal Arrhythmic Events in Patients With Brugada Syndrome



Combination of Depolarization and Repolarization Abnormalities

Koji Tokioka, MD,* Kengo F. Kusano, MD, PhD,[†] Hiroshi Morita, MD, PhD,* Daiji Miura, PhD,* Nobuhiro Nishii, MD, PhD,* Satoshi Nagase, MD, PhD,* Kazufumi Nakamura, MD, PhD,* Kuniyoshi Kohno, MD, PhD,* Hiroshi Ito, MD, PhD,* Tohru Ohe, MD, PhD[†]

Okayama and Osaka, Japan

Objectives

This study aimed to determine the usefulness of the combination of several electrocardiographic markers on risk assessment of ventricular fibrillation (VF) in patients with Brugada syndrome (BrS).

Background

Detection of high-/low-risk BrS patients using a noninvasive method is an important issue in the clinical setting. Several electrocardiographic markers related to depolarization and repolarization abnormalities have been reported, but the relationship and usefulness of these parameters in VF events are unclear.

Methods

Baseline characteristics of 246 consecutive patients (236 men; mean age, 47.6 ± 13.6 years) with a Brugada-type electrocardiogram, including 13 patients with a history of VF and 40 patients with a history of syncope episodes, were retrospectively analyzed. During the mean follow-up period of 45.1 months, VF in 23 patients and sudden cardiac death (SCD) in 1 patient were observed. Clinical/genetic and electrocardiographic parameters were compared with VF/SCD events.

Results

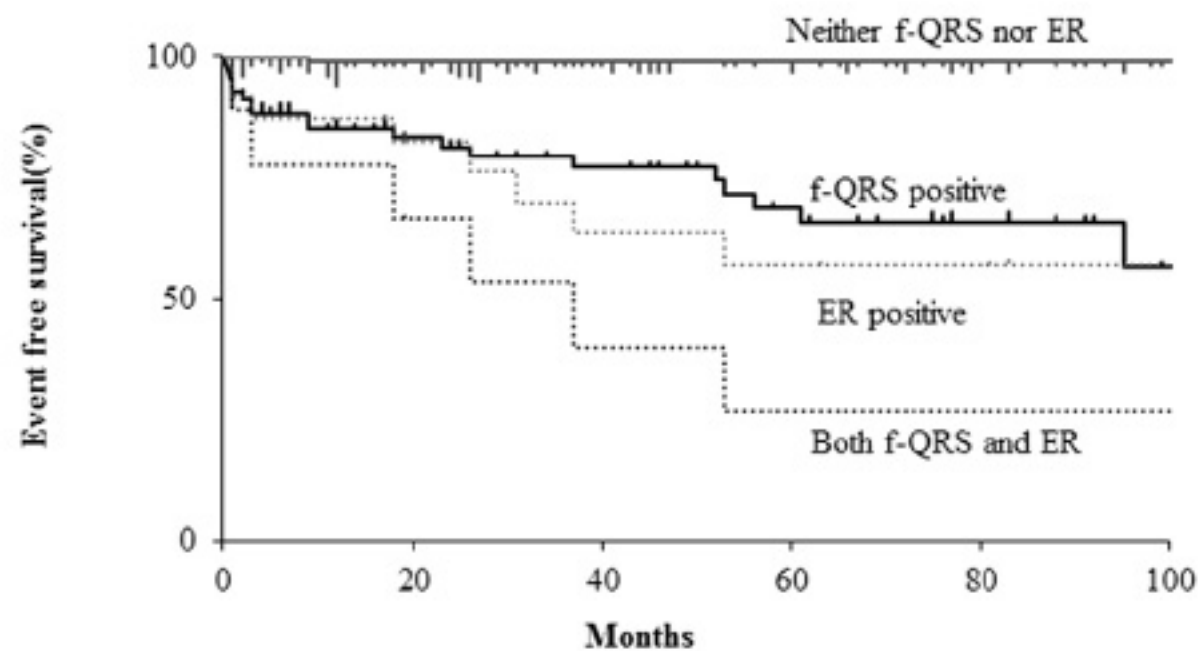
On univariate analysis, a history of VF and syncope episodes, paroxysmal atrial fibrillation, spontaneous type 1 pattern in the precordial leads, and electrocardiographic markers of depolarization abnormalities (QRS duration ≥ 120 ms, and fragmented QRS [f-QRS]) and those of repolarization abnormalities (inferolateral early repolarization [ER] pattern and QT prolongation) were associated with later cardiac events. On multivariable analysis, a history of VF and syncope episodes, inferolateral ER pattern, and f-QRS were independent predictors of documented VF and SCD (odds ratios: 19.61, 28.57, 2.87, and 5.21, respectively; $p < 0.05$). Kaplan-Meier curves showed that the presence/absence of inferolateral ER and f-QRS predicted a worse/better prognosis (log-rank test, $p < 0.01$).

Conclusions

The combination of depolarization and repolarization abnormalities in BrS is associated with later VF events. The combination of these abnormalities is useful for detecting high- and low-risk BrS patients. (J Am Coll Cardiol 2014;63:2131–8) © 2014 by the American College of Cardiology Foundation

Table 2 Characteristics of Patients With and Without VF/SCD During Follow-Up

	VF/SCD +	VF/SCD –	Univariate Analysis			Multivariate Analysis		
			OR	95% CI	p Value	HR	95% CI	p Value
Clinical/genetic parameters								
Male/female	23/1	213/9	1.029	0.125–8.490	0.649			
Age (yrs), median (IQR)	47 (15)	48 (21)			0.835			
History of syncope episodes	13 (54.2)	27 (12.2)	8.535	3.477–20.955	<0.001	28.571	6.135–142.857	<0.001
History of VF episodes	9 (37.5)	4 (1.8)	32.700	9.012–118.645	<0.001	19.608	4.115–90.909	<0.001
Paroxysmal AF	9 (37.5)	35 (15.8)	3.206	1.301–7.899	0.013			0.306
Family history of SCD	8 (33.3)	61 (27.5)	1.320	0.537–3.241	0.554			
SCN5A gene mutation	4/23 (17.4)	13/100 (13.0)	1.409	0.414–4.799	0.396			
VF induction during EP study	17/24 (70.8)	54/131 (41.2)	3.463	1.344–8.293	0.007			0.562
Spontaneous type 1 ECG pattern	22 (91.7)	134 (60.4)	7.224	1.657–31.491	0.002			0.114
Depolarization parameters								
Positive f-QRS	20 (83.3)	58 (26.1)	14.138	4.638–43.093	<0.001	5.208	1.689–16.129	0.004
Positive LP	20/24 (83.3)	146/211 (69.2)	2.226	0.732–6.772	0.150			
PQ interval >200 ms	8 (33.3)	40 (18.0)	2.275	0.911–5.681	0.069			
QRS interval ≥120 ms	8 (33.3)	29 (13.1)	3.328	1.307–8.469	0.015			0.908
Repolarization parameters								
ER pattern	8 (33.3)	17 (7.7)	6.029	2.258–16.103	<0.001	2.874	1.160–7.143	0.023
QTc >440 ms	7 (29.2)	28 (12.6)	2.853	1.087–7.490	0.036			0.608



N. of patients						
Neither	152	83	55	39	22	11
fQRS pos.	78	43	35	23	12	5
ER pos.	25	15	10	9	8	5
Both	9	5	3	2	2	2

Figure 3 Kaplan-Meier Analysis of VF/SCD Events

SUBSTRATO STRUTTURALE

Right Ventricular Fibrosis and Conduction Delay in a Patient With Clinical Signs of Brugada Syndrome

A Combined Electrophysiological, Genetic, Histopathologic, and Computational Study

Ruben Coronel, MD, PhD; Simona Casini, MSc; Tamara T. Koopmann, BSc;
Francien J.G. Wilms-Schopman, RA; Arie O. Verkerk, PhD; Joris R. de Groot, MD, PhD;
Zahurul Bhuiyan, MD, PhD; Connie R. Bezzina, PhD; Marieke W. Veldkamp, PhD;
André C. Linnenbank, PhD; Allard C. van der Wal, MD, PhD; Hanno L. Tan, MD, PhD;
Pedro Brugada, MD, PhD; Arthur A.M. Wilde, MD, PhD; Jacques M.T. de Bakker, PhD

Background—The mechanism of ECG changes and arrhythmogenesis in Brugada syndrome (BS) patients is unknown.

Methods and Results—A BS patient without clinically detected cardiac structural abnormalities underwent cardiac transplantation for intolerable numbers of implantable cardioverter/defibrillator discharges. The patient's explanted heart was studied electrophysiologically and histopathologically. Whole-cell currents were measured in HEK293 cells expressing wild-type or mutated sodium channels from the patient. The right ventricular outflow tract (RVOT) endocardium showed activation slowing and was the origin of ventricular fibrillation without a transmural repolarization gradient. Conduction restitution was abnormal in the RVOT but normal in the left ventricle. Right ventricular hypertrophy and fibrosis with epicardial fatty infiltration were present. HEK293 cells expressing a G1935S mutation in the gene encoding the cardiac sodium channel exhibited enhanced slow inactivation compared with wild-type channels. Computer simulations demonstrated that conduction slowing in the RVOT might have been the cause of the ECG changes.

Conclusions—In this patient with BS, conduction slowing based on interstitial fibrosis, but not transmural repolarization differences, caused the ECG signs and was the origin of ventricular fibrillation. (*Circulation*. 2005;112:2769-2777.)

Cardiac Histological Substrate in Patients With Clinical Phenotype of Brugada Syndrome

Andrea Frustaci, MD*; Silvia G. Priori, MD, PhD*; Maurizio Pieroni, MD, PhD;
Cristina Chimenti, MD, PhD; Carlo Napolitano, MD, PhD; Ilaria Rivolta, PhD; Tommaso Sanna, MD;
Fulvio Bellocci, MD; Matteo Antonio Russo, MD

Background—The role of structural heart disease and sodium channel dysfunction in the induction of electrical instability in Brugada syndrome is still debated.

Methods and Results—We studied 18 consecutive patients (15 males, 3 females; mean age 42.0 ± 12.4 years) with clinical phenotype of Brugada syndrome and normal cardiac structure and function on noninvasive examinations. Clinical presentation was ventricular fibrillation in 7 patients, sustained polymorphic ventricular tachycardia in 7, and syncope in 4. All patients underwent cardiac catheterization, coronary and ventricular angiography, biventricular endomyocardial biopsy, and DNA screening of the *SCN5A* gene. Biopsy samples were processed for histology, electron microscopy, and molecular screening for viral genomes. Microaneurysms were detected in the right ventricle in 7 patients and also in the left ventricle in 4 of them. Histology showed a prevalent or localized right ventricular myocarditis in 14 patients, with detectable viral genomes in 4; right ventricular cardiomyopathy in 1 patient; and cardiomyopathic changes in 3. Genetic studies identified 4 carriers of *SCN5A* gene mutations that cause in vitro abnormal function of mutant proteins. In these patients, myocyte cytoplasm degeneration was present at histology, whereas terminal dUTP nick end-labeling assay showed a significant increase of apoptotic myocytes in right and left ventricle versus normal controls ($P=0.014$ and $P=0.013$, respectively).

Conclusions—Despite an apparently normal heart at noninvasive evaluation, endomyocardial biopsy detected structural alterations in all 18 patients with Brugada syndrome. Mutations in the *SCN5A* gene, identified in 4 of the 18 patients, may have induced concealed structural abnormalities of myocardiocytes that accounted for paroxysmal arrhythmic manifestations. (*Circulation*. 2005;112:3680-3687.)

33/M – VT - Type I
No SCN5A mutation
Family history negative

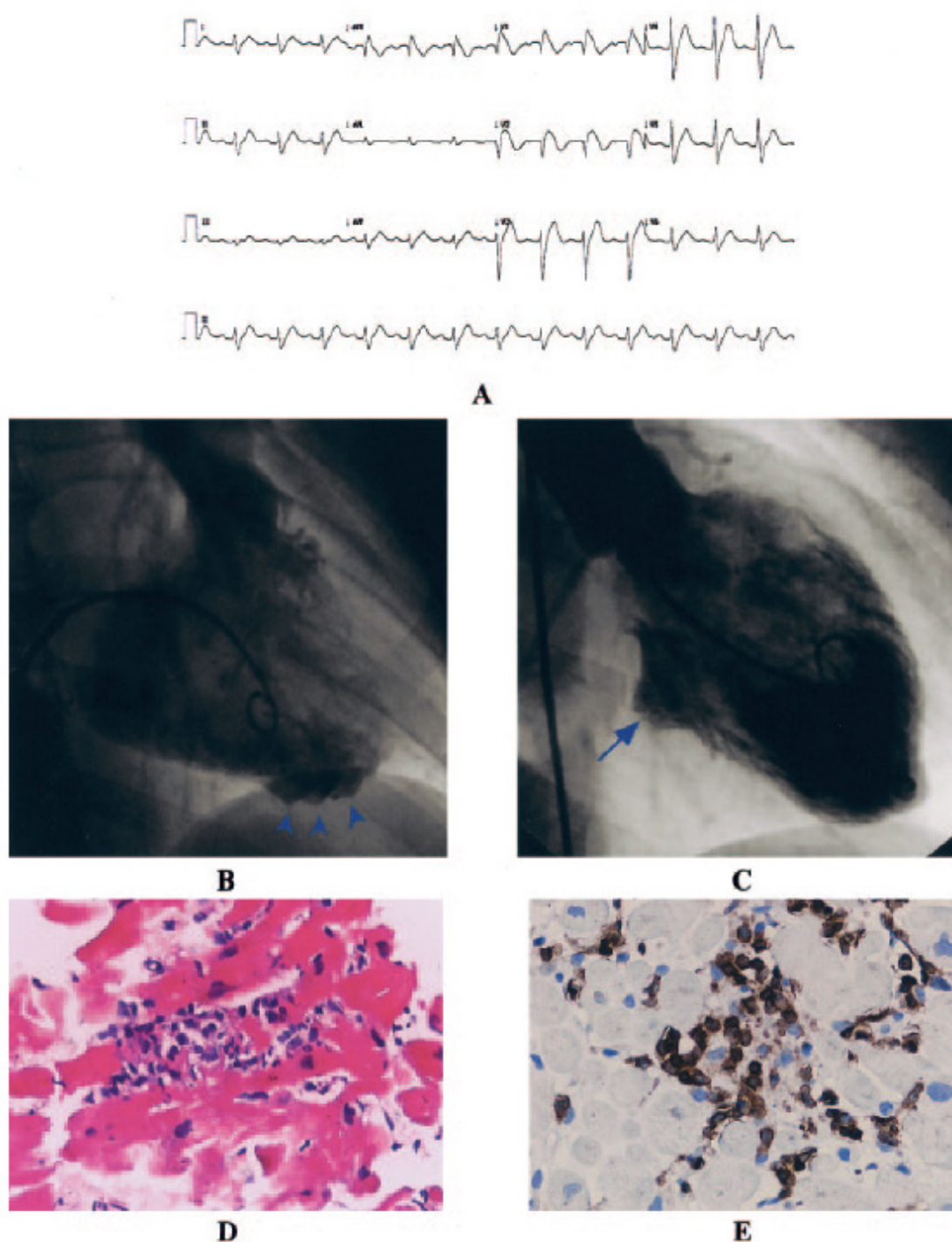


Figure 1. Baseline ECG (A) from patient 7 showing ST-segment elevation in the right precordial leads consistent with type I Brugada pattern. End-diastolic frames of right (B) and left (C) ventricular angiography from the same patient showing multiple small aneurysms of the inferior-apical wall (arrowheads) and a localized microaneurysm of the postero-basal segment of the left ventricle (arrow). Right (D) and left (E) ventricular endomyocardial biopsy sample from the same patient showing active lymphocytic myocarditis. D, Hematoxylin and eosin. E, Immunohistochemistry with mouse anti-human CD45RO antibody. Original magnification $\times 250$.

Slow and Discontinuous Conduction Conspire in Brugada Syndrome

A Right Ventricular Mapping and Stimulation Study

Pieter G. Postema, MD; Pascal F.H.M. van Dessel, MD, PhD; Jacques M.T. de Bakker, PhD;
Lukas R.C. Dekker, MD, PhD; Andre C. Linnenbank, PhD; Mark G. Hoogendijk, MD;
Ruben Coronel, MD, PhD; Jan G.P. Tijssen, PhD;
Arthur A.M. Wilde, MD, PhD; Hanno L. Tan, MD, PhD

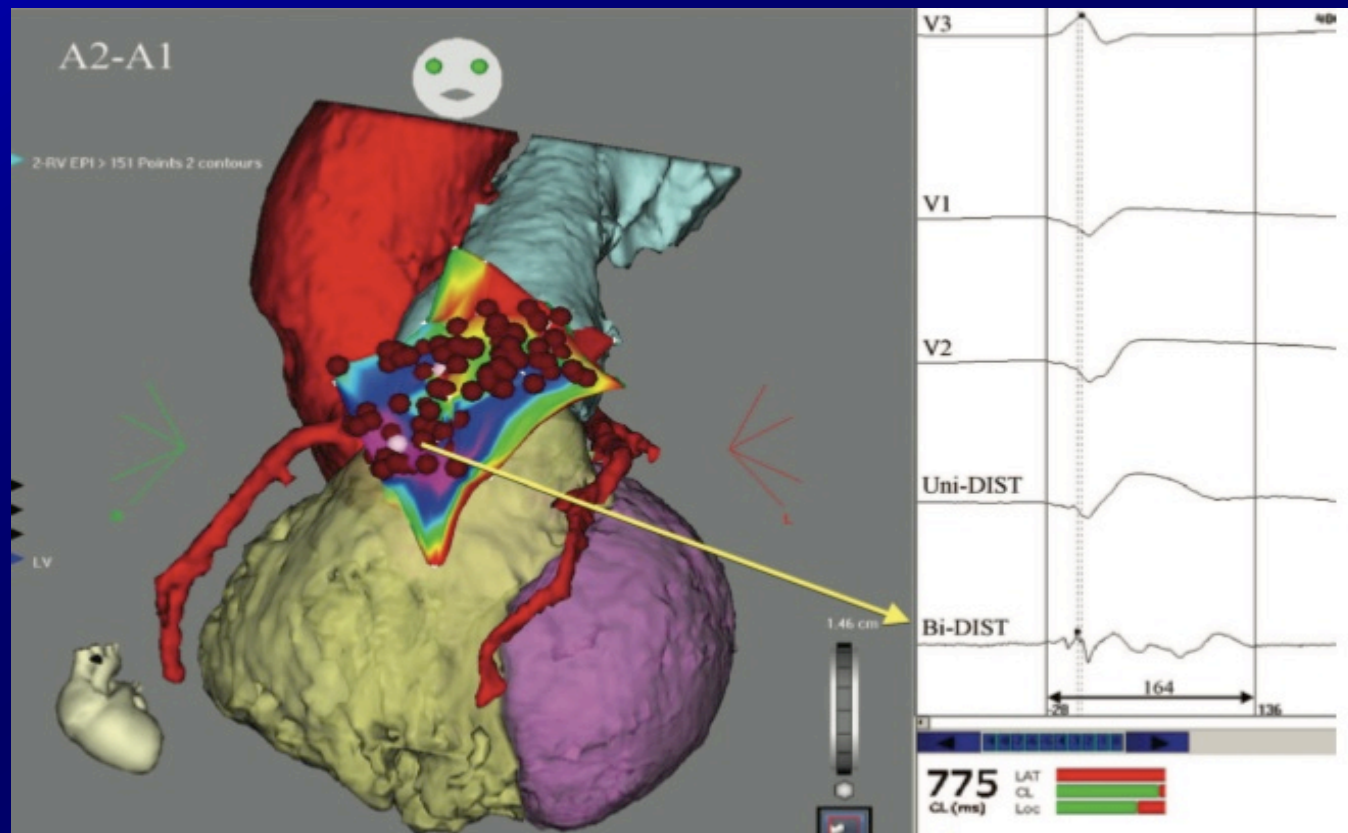
Background—Brugada syndrome (BrS) is associated with lethal arrhythmias, which are linked to specific ST-segment changes (type-1 BrS-ECG) and the right ventricle (RV). The pathophysiological basis of the arrhythmias and type-1 BrS-ECG is unresolved. We studied the electrophysiological characteristics of the RV endocardium in BrS.

Methods and Results—RV endocardial electroanatomical mapping and stimulation studies were performed in controls (n=12) and BrS patients with a type-1 (BrS-1, n=10) or type-2 BrS-ECG (BrS-2, n=12) during the studies. BrS-1 patients had prominent impairment of RV endocardial impulse propagation when compared with controls, as represented by: (1) prolonged activation-duration during sinus rhythm (86 ± 4 versus 65 ± 3 ms), (2) increased electrogram fractionation (1.36 ± 0.04 versus 1.15 ± 0.01 deflections per electrogram), (3) longer electrogram duration (83 ± 3 versus 63 ± 2 ms), (4) activation delays on premature stimulation (longitudinal: 160 ± 26 versus 86 ± 9 ms; transversal: 112 ± 5 versus 58 ± 6 ms), and (5) abnormal transversal conduction velocity restitution (42 ± 8 versus 18 ± 2 ms increase in delay at shortest coupling intervals). Wider and more fractionated electrograms were also found in BrS-2 patients. Repolarization was not different between groups.

Conclusions—BrS-1 and BrS-2 patients are characterized by wide and fractionated electrograms at the RV endocardium. BrS-1 patients display additional conduction slowing during sinus rhythm and premature stimulation along with abnormal transversal conduction velocity restitution. These patients may thus exhibit a substrate for slow and discontinuous conduction caused by abnormal active membrane processes and electric coupling. Our findings support the emerging notion that BrS is not solely attributable to abnormal electrophysiological properties but requires the conspiring effects of conduction slowing and tissue discontinuities. (*Circ Arrhythmia Electrophysiol.* 2008;1:379-386.)

Prevention of Ventricular Fibrillation Episodes in Brugada Syndrome by Catheter Ablation Over the Anterior Right Ventricular Outflow Tract Epicardium

Koonlawee Nademanee, MD; Gumpanart Veerakul, MD; Pakorn Chandanamattha, MD; Lertlak Chaothawee, MD; Aekarach Ariyachaipanich, MD; Kriengkrai Jirasirojanakorn, MD; Khanchit Likittanasombat, MD; Kiertijai Bhuripanyo, MD; Tachapong Ngarmukos, MD

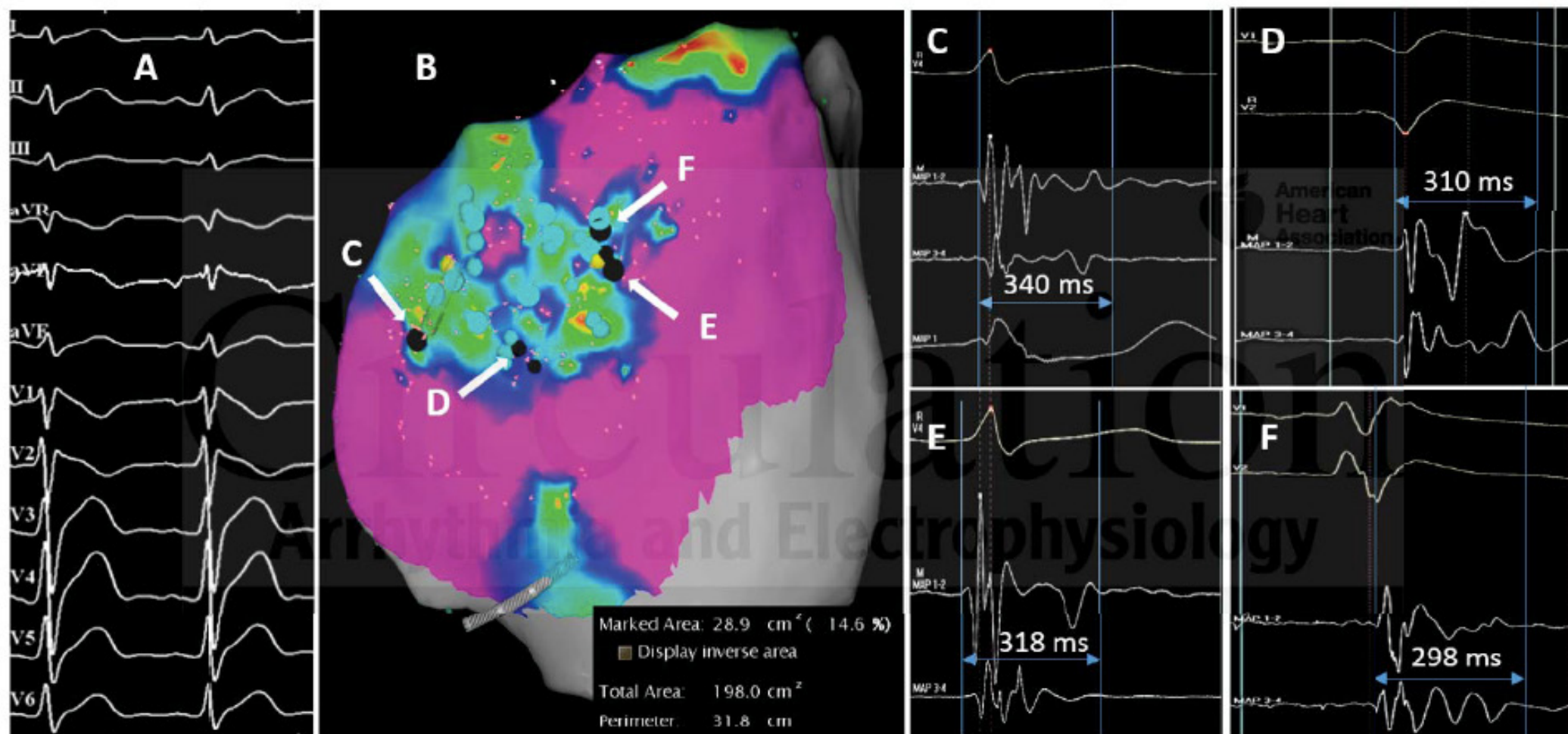


K. Nademanee, et al. Circulation 2011

Brugada Syndrome Phenotype Elimination by Epicardial Substrate Ablation

Josep Brugada, Carlo Pappone, Antonio Berrueto, Gabriele Vicedomini, Francesco Manguso, Giuseppe Ciconte, Luigi Giannelli and Vincenzo Santinelli

Circ Arrhythm Electrophysiol. published online August 19, 2015;



Fibrosis, Connexin-43, and Conduction Abnormalities in the Brugada Syndrome



Koonlawee Nademanee, MD,* Hariharan Raju, PhD,† Sofia V. de Noronha, PhD,† Michael Papadakis, MD,† Laurence Robinson, MBBS,† Stephen Rothery, BSc,† Naomasa Makita, MD,§ Shinya Kowase, MD,|| Nakorn Boonmee, MD,¶ Vorapot Vitayakritsirikul, MD,¶ Samreng Ratanarapee, MD,# Sanjay Sharma, MD,† Allard C. van der Wal, MD,** Michael Christiansen, MD,†† Hanno L. Tan, MD,** Arthur A. Wilde, MD,**†† Akihiko Nogami, MD,§§ Mary N. Sheppard, MD,† Gumpant Veerakul, MD,¶ Elijah R. Behr, MD†

ABSTRACT

BACKGROUND The right ventricular outflow tract (RVOT) is acknowledged to be responsible for arrhythmogenesis in Brugada syndrome (BrS), but the pathophysiology remains controversial.

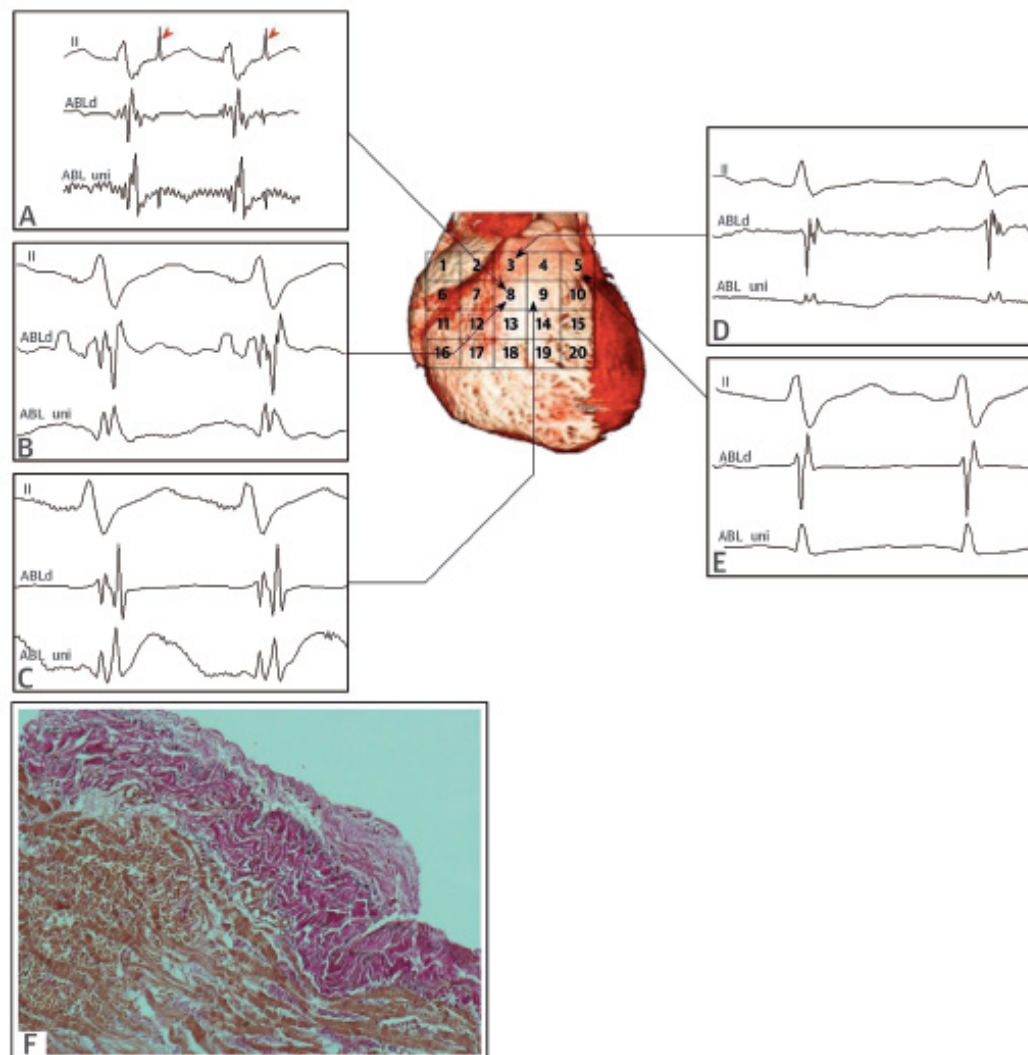
OBJECTIVES This study assessed the substrate underlying BrS at post-mortem and in vivo, and the role for open thoracotomy ablation.

METHODS Six whole hearts from male post-mortem cases of unexplained sudden death (mean age 23.2 years) with negative specialist cardiac autopsy and familial BrS were used and matched to 6 homograft control hearts by sex and age (within 3 years) by random risk set sampling. Cardiac autopsy sections from cases and control hearts were stained with picrosirius red for collagen. The RVOT was evaluated in detail, including immunofluorescent stain for connexin-43 (Cx43). Collagen and Cx43 were quantified digitally and compared. An in vivo study was undertaken on 6 consecutive BrS patients (mean age 39.8 years, all men) during epicardial RVOT ablation for arrhythmia via thoracotomy. Abnormal late and fractionated potentials indicative of slowed conduction were identified, and biopsies were taken before ablation.

RESULTS Collagen was increased in BrS autopsy cases compared with control hearts (odds ratio [OR]: 1.42; $p = 0.026$). Fibrosis was greatest in the RVOT (OR: 1.98; $p = 0.003$) and the epicardium (OR: 2.00; $p = 0.001$). The Cx43 signal was reduced in BrS RVOT (OR: 0.59; $p = 0.001$). Autopsy and in vivo RVOT samples identified epicardial and interstitial fibrosis. This was collocated with abnormal potentials in vivo that, when ablated, abolished the type 1 Brugada electrocardiogram without ventricular arrhythmia over 24.6 ± 9.7 months.

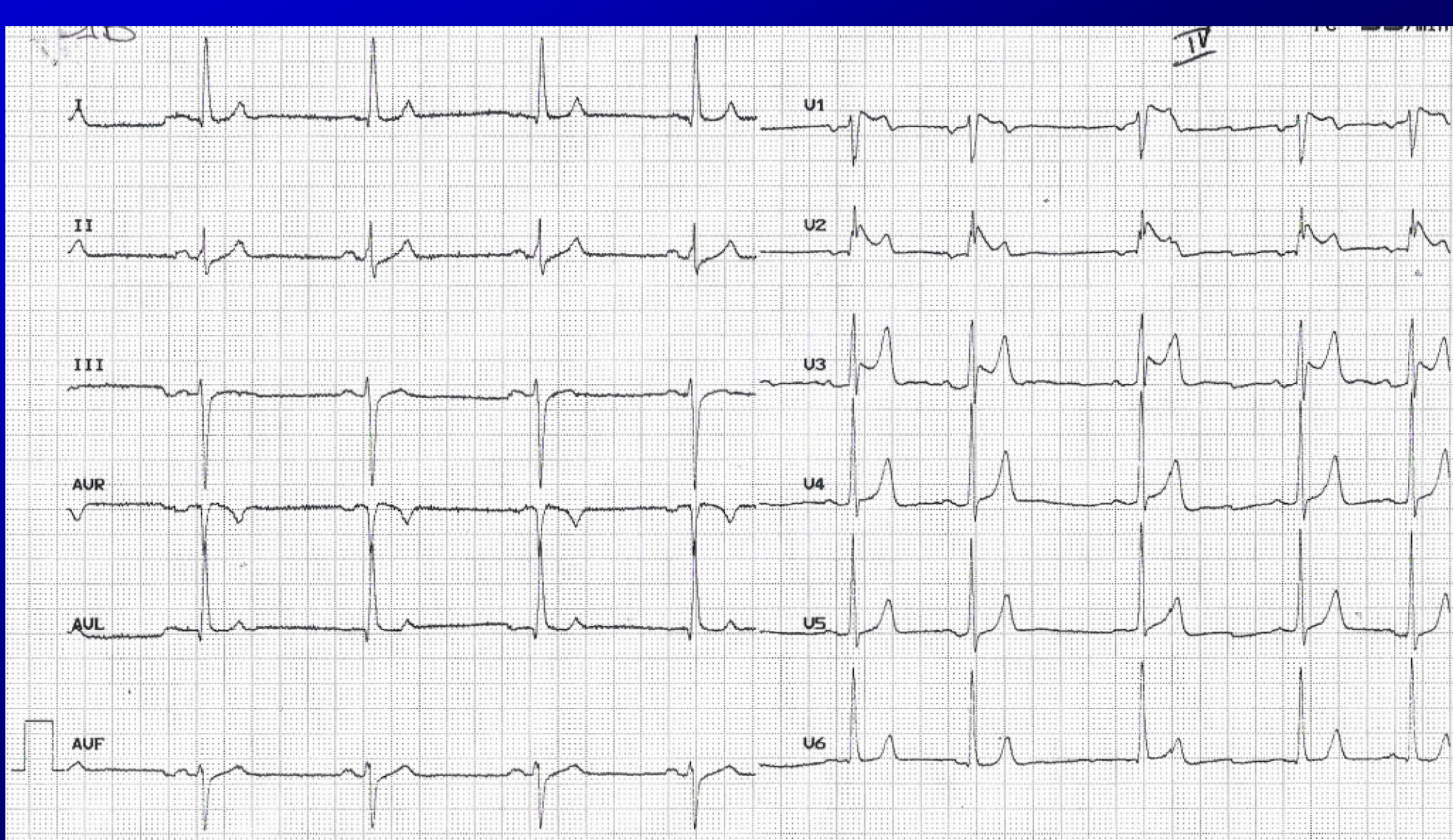
CONCLUSIONS BrS is associated with epicardial surface and interstitial fibrosis and reduced gap junction expression in the RVOT. This collocates to abnormal potentials, and their ablation abolishes the BrS phenotype and life-threatening arrhythmias. BrS is also associated with increased collagen throughout the heart. Abnormal myocardial structure and conduction are therefore responsible for BrS. (J Am Coll Cardiol 2015;66:1976–86) © 2015 by the American College of Cardiology Foundation.

FIGURE 2 Computed Tomography Scan, Epicardial Electrograms, and Histology of RVOT of In Vivo BrS Patient

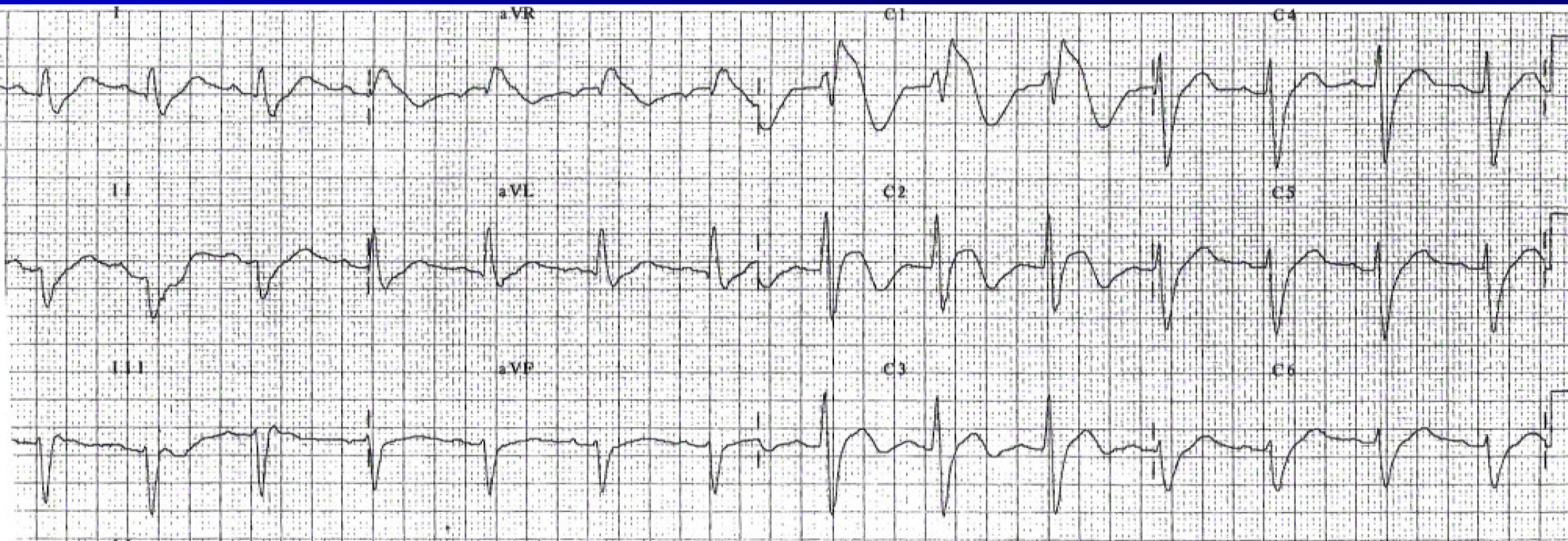


Computed tomography scan of the heart (center) of in vivo BrS patient V2 showing an anatomical grid over the anterior RVOT. ECG lead II and a distal bipolar (0.4 mV/cm voltage scale at 30- to 300-Hz filter settings) and unipolar (5 mV/cm voltage scale at 0.05- to 300-Hz filter settings) electrogram at labeled sites are given in surrounding panels, with pacing stimuli indicated by red arrowheads. Abnormal fractionated electrograms are on the (A to C) left and normal electrograms on the (D to E) right. (F) Epicardial biopsy and histology (PSR) at the site of the abnormal electrogram shows epicardial fibrosis with focal finger-like projections of collagen into myocardium. ABL d = distal bipolar ablation catheter electrogram; ABL uni = unipolar ablation catheter electrogram; BrS = Brugada syndrome; RVOT = right ventricular outflow tract; other abbreviations as in Figure 1.

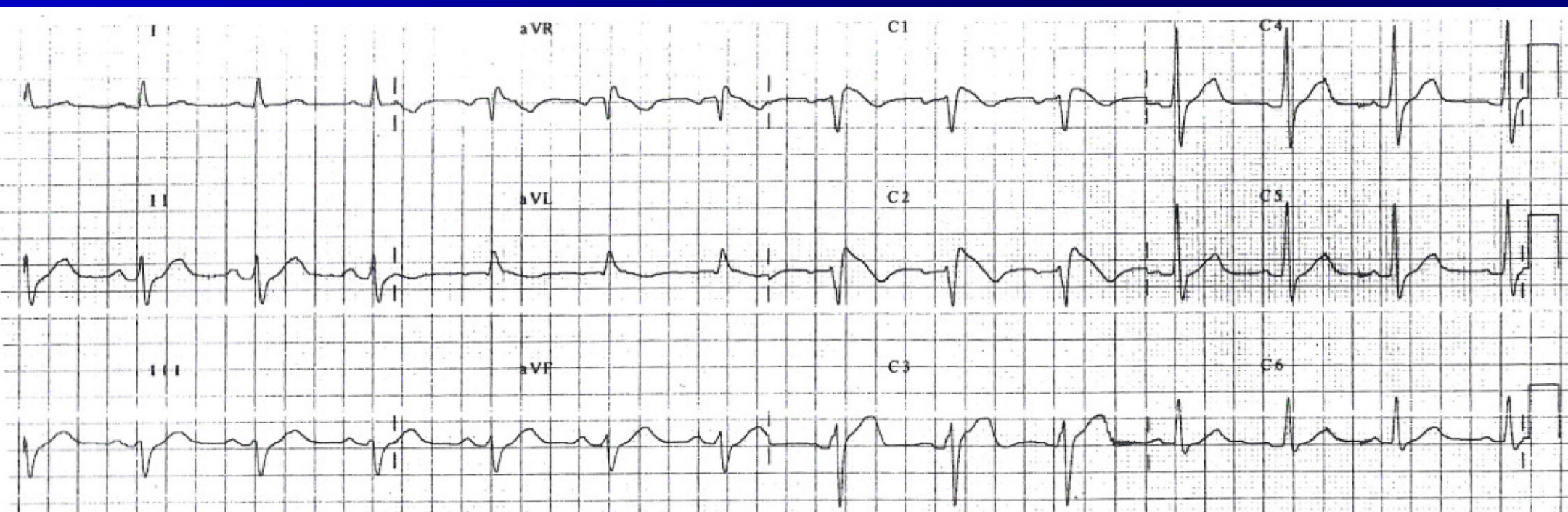
OUR EXPERIENCE



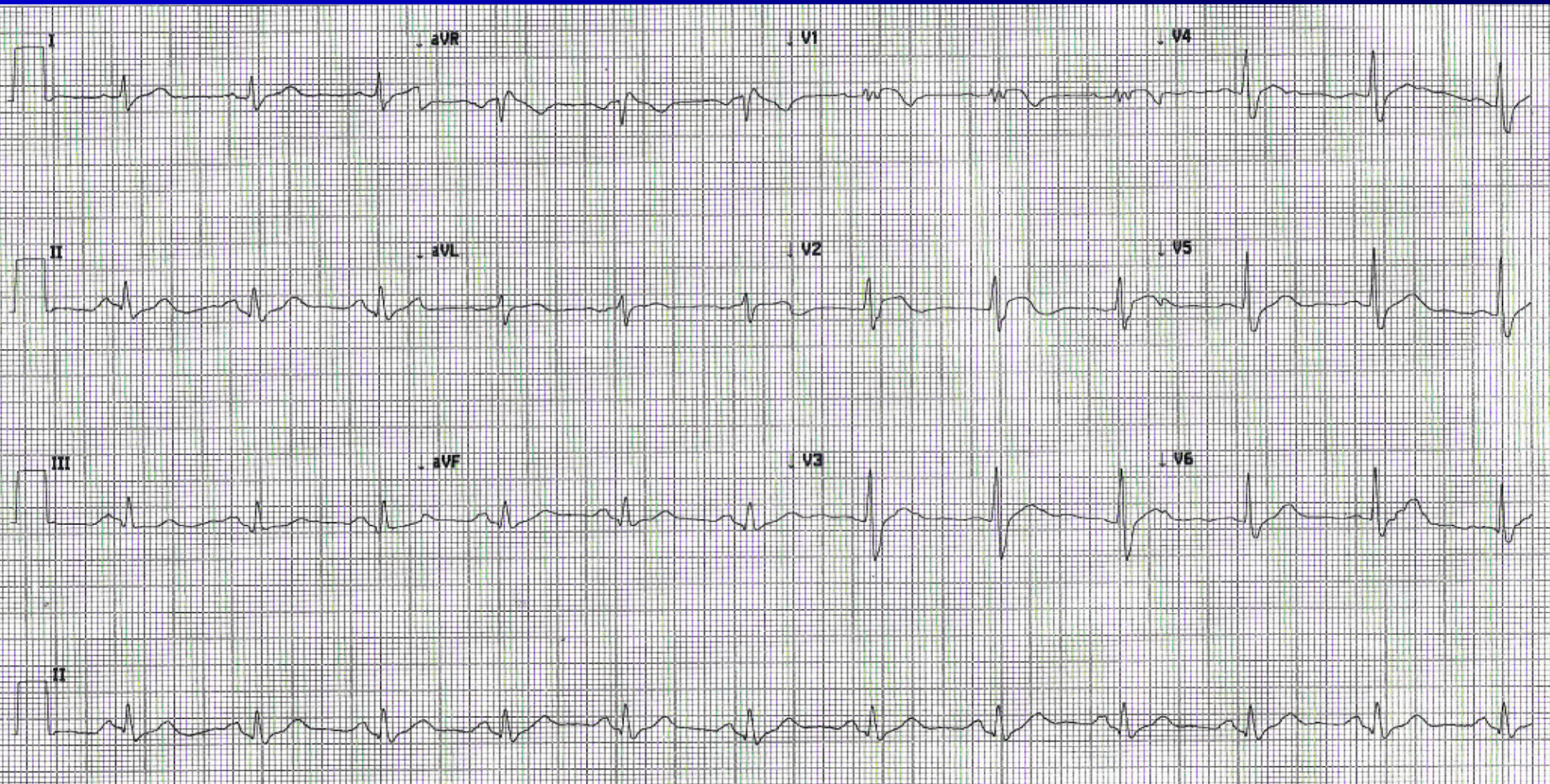
Bram. No eventi



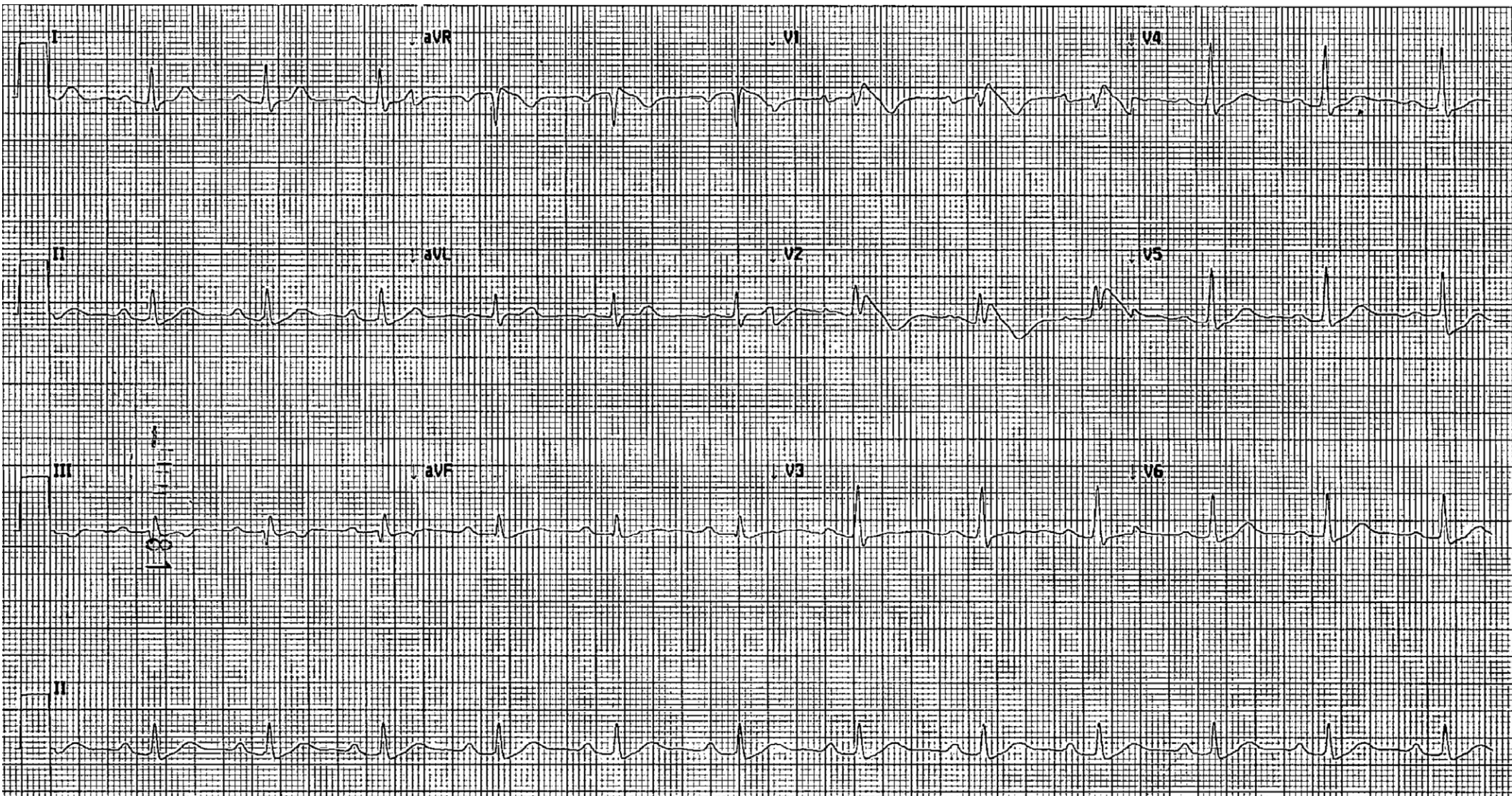
Cost. Arresto cardiaco



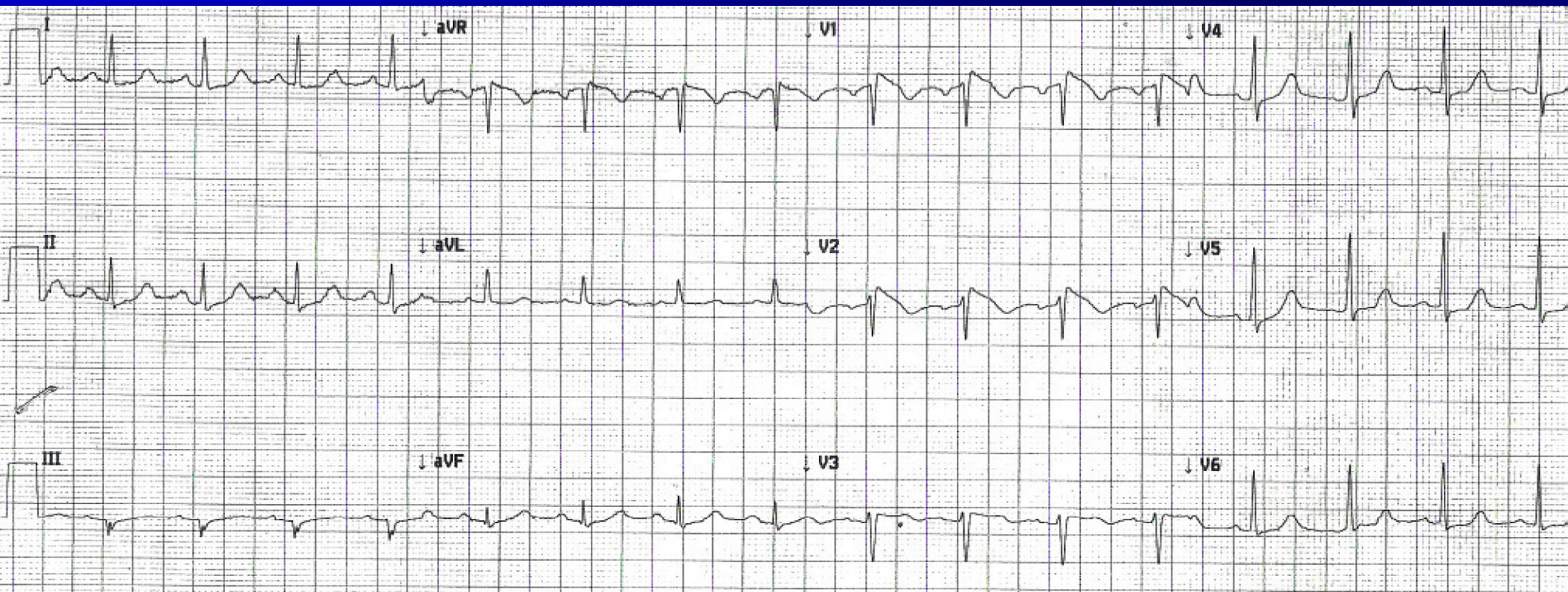
Gagl. No eventi



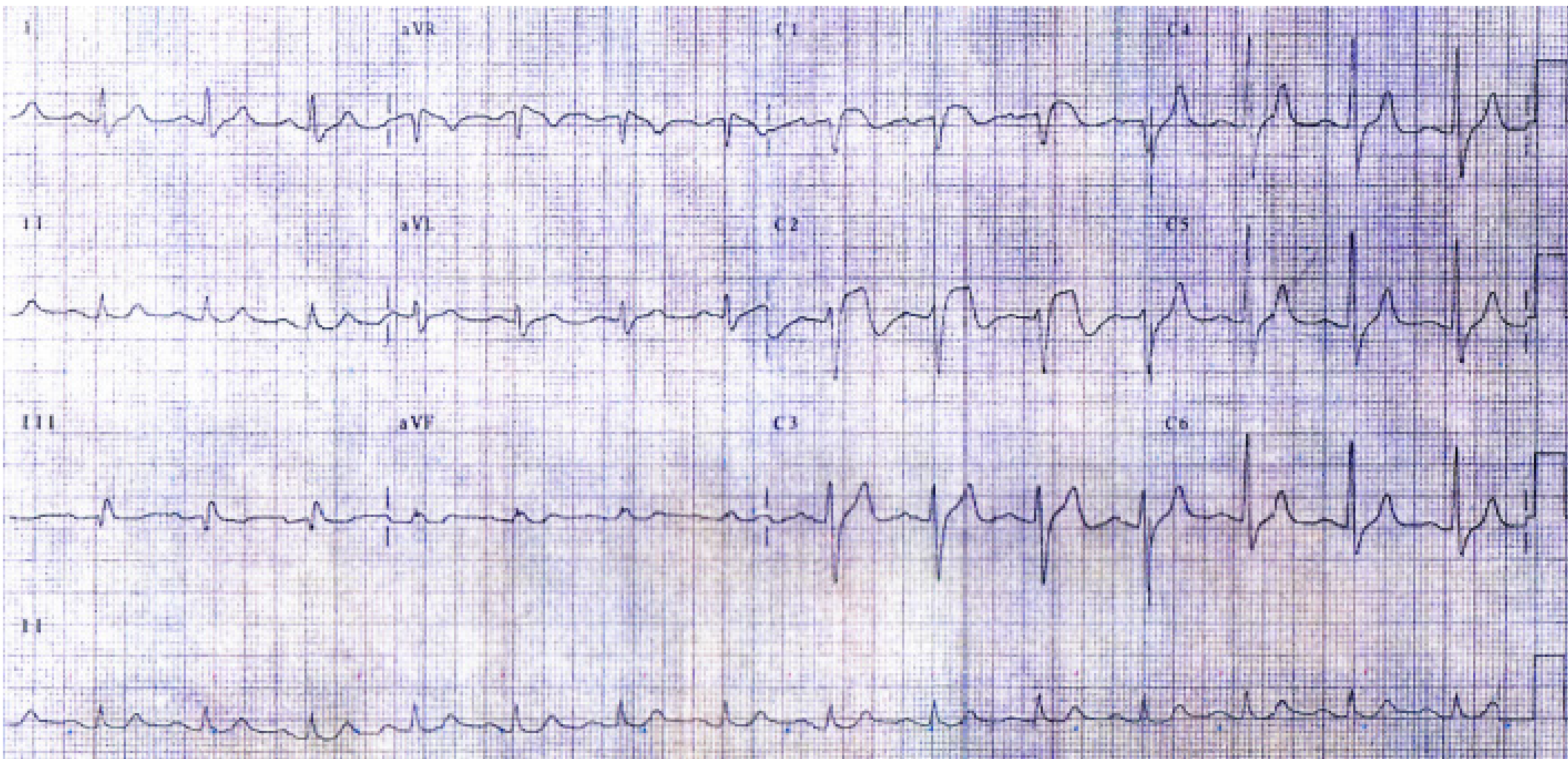
Pac. Arresto card



Pel. Arresto card



Pro. No eventi



Ast. Arresto card

A New Electrocardiographic Marker of Sudden Death in Brugada Syndrome



The S-Wave in Lead I

Leonardo Calò, MD,^a Carla Giustetto, MD,^b Annamaria Martino, MD,^a Luigi Sciarra, MD,^a Natascia Cerrato, MD,^b Marta Marziali, MD,^a Jessica Rauzino, MD,^c Giulia Carlino, MD,^d Ermenegildo de Ruvo, MD,^a Federico Guerra, MD,^e Marco Rebecchi, MD,^a Chiara Lanzillo, MD, PhD,^a Matteo Anselmino, MD,^b Antonio Castro, MD,^f Federico Turreni, MD,^f Maria Penco, MD,^d Massimo Volpe, MD,^c Alessandro Capucci, MD,^e Fiorenzo Gaita, MD^b

ABSTRACT

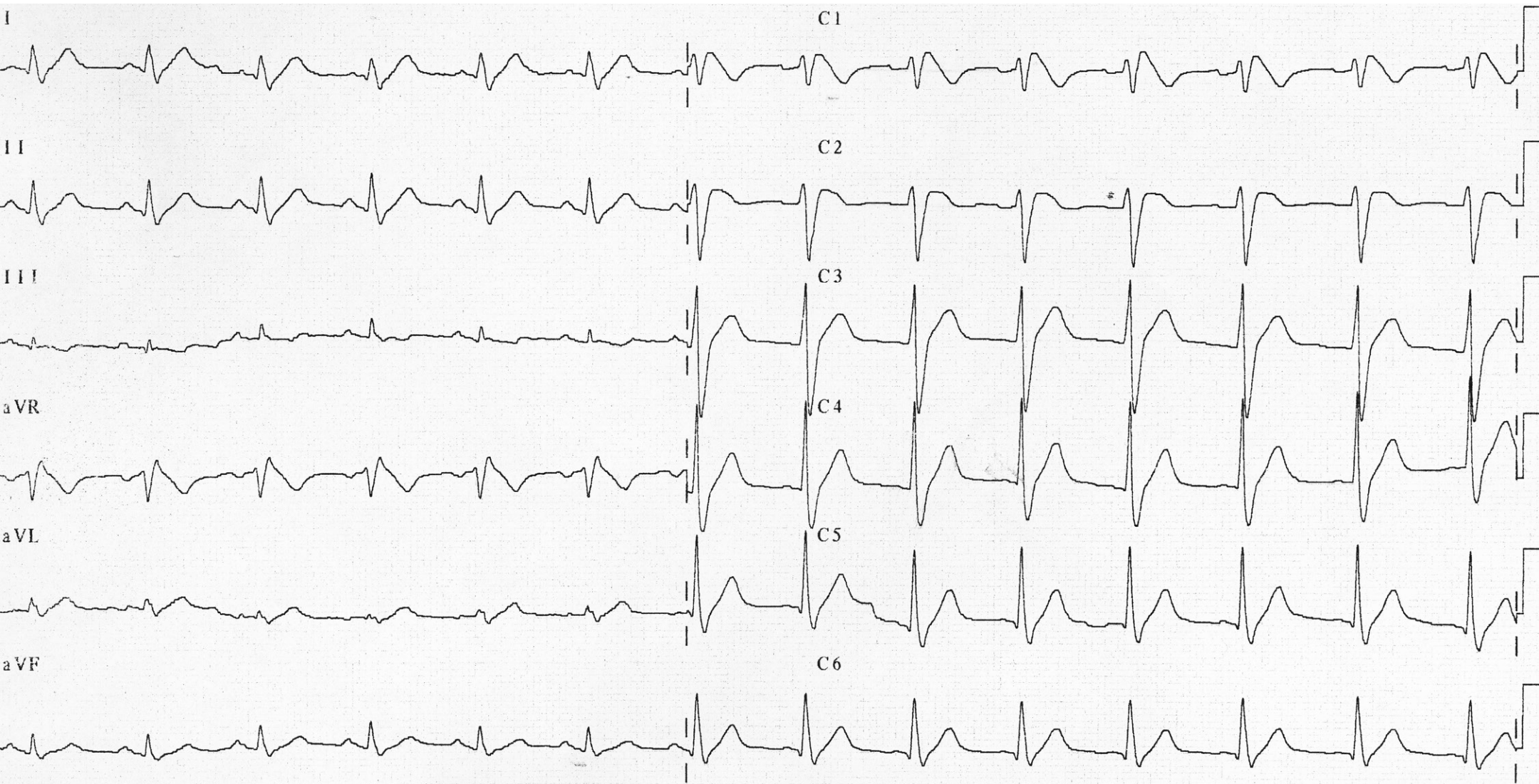
BACKGROUND Risk stratification in asymptomatic patients remains by far the most important yet unresolved clinical problem in the Brugada syndrome (BrS).

OBJECTIVES This study sought to analyze the usefulness of electrocardiographic parameters as markers of sudden cardiac death (SCD) in BrS.

METHODS This study analyzed data from 347 consecutive patients (78.4% male; mean age 45 ± 13.1 years) with spontaneous type 1 BrS by ECG parameters but with no history of cardiac arrest (including 91.1% asymptomatic at presentation, 5.2% with a history of atrial fibrillation [AF], and 4% with a history of arrhythmic syncope). Electrocardiographic characteristics at the first clinic visit were analyzed to predict ventricular fibrillation (VF)/SCD during follow-up.

RESULTS During the follow-up (48 ± 38 months), 276 (79.5%) patients remained asymptomatic, 39 (11.2%) developed syncope, and 32 (9.2%) developed VF/SCD. Patients who developed VF/SCD had a lower prevalence of *SCN5A* gene mutations ($p = 0.009$) and a higher prevalence of positive electrophysiological study results ($p < 0.0001$), a family history of SCD ($p = 0.03$), and AF ($p < 0.0001$). The most powerful marker for VF/SCD was a significant S-wave (≥ 0.1 mV and/or ≥ 40 ms) in lead I. In the multivariate analysis, the duration of S-wave in lead I ≥ 40 ms (hazard ratio: 39.1) and AF (hazard ratio: 3.7) were independent predictors of VF/SCD during follow-up. Electroanatomic mapping in 12 patients showed an endocardial activation time significantly longer in patients with an S-wave in lead I, mostly because of a significant delay in the anterolateral right ventricular outflow tract.

CONCLUSIONS The presence of a wide and/or large S-wave in lead I was a powerful predictor of life-threatening ventricular arrhythmias in patients with BrS and no history of cardiac arrest at presentation. However, the prognostic value of a significant S-wave in lead I should be confirmed by larger studies and by an independent confirmation cohort of healthy subjects. (J Am Coll Cardiol 2016;67:1427–40) © 2016 by the American College of Cardiology Foundation.



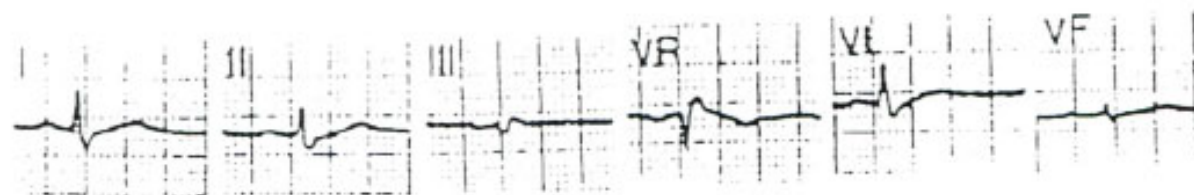
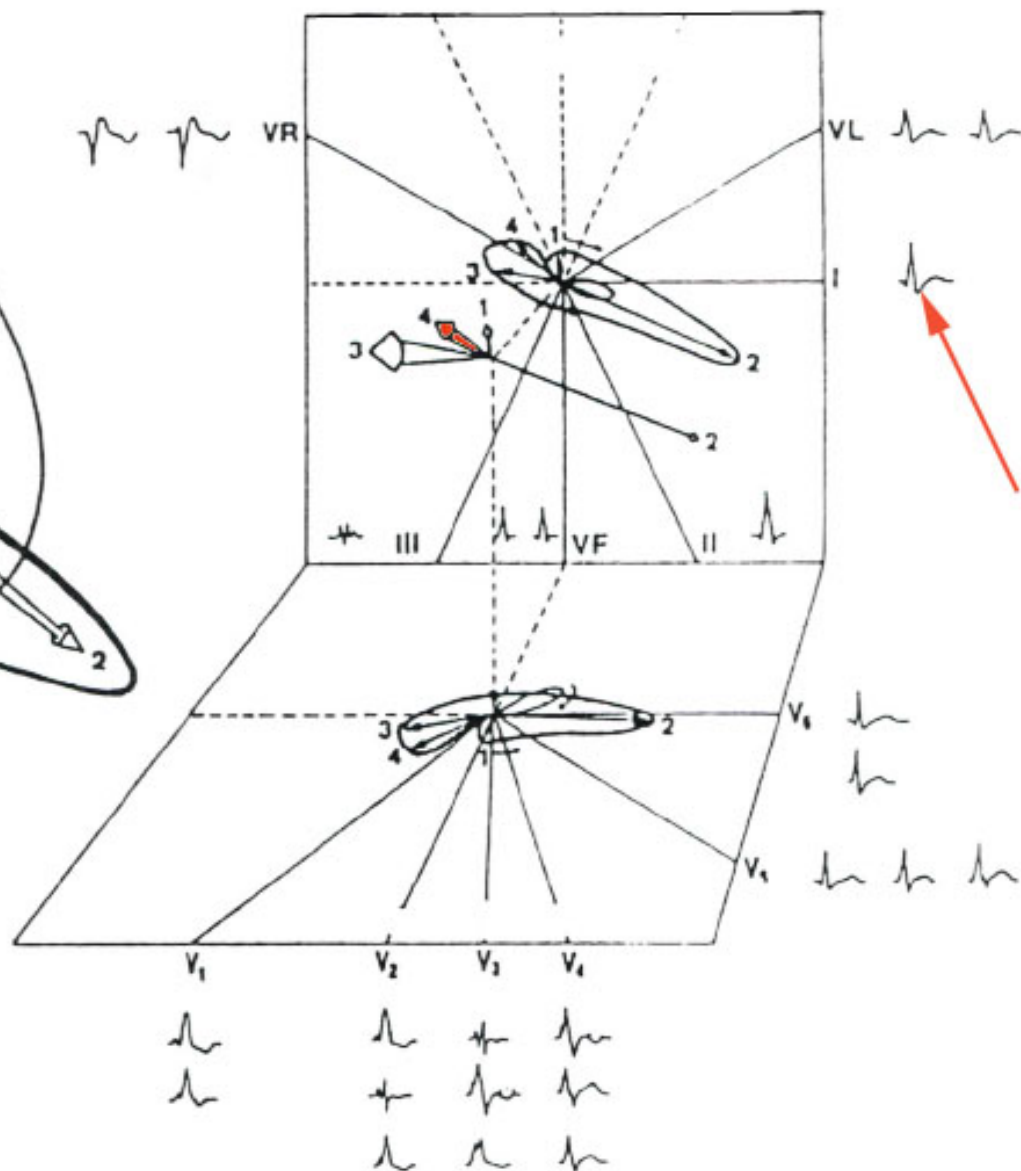
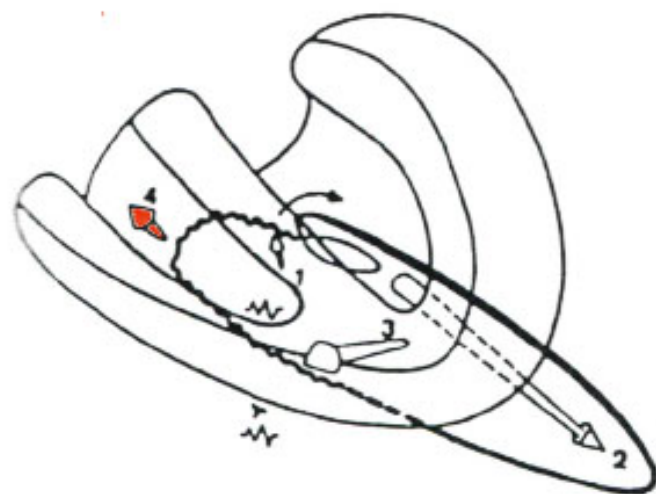


Table 1. Clinical characteristics of study population

Male/female	272/75
Age (years)	45 ± 13.1
Family history of SCD	71 (20.5)
SCN5A gene mutation (analyzed: n = 107)	32 (29.9)
Positive EPS (performed: n = 186)	77 (41.4)
History of AF	18 (5.2)
Asymptomatic	276 (79.5)
ICD recipients	98 (28.2)

Values are expressed as n, n (%) or mean ± SD. AF, atrial fibrillation; EPS, electrophysiological study; ICD, implantable cardioverter defibrillator; SCD, sudden cardiac death.

Table 2. Clinical characteristics in subgroups according to symptoms.

Parameters	Asymptomatic (N=276)	Syncope (N= 39)	FV/SCD (N=32)	<i>P</i>
Male (%)	217 (78.6)	27 (69.2)	28 (87.5)	<i>NS</i>
Age (years)	45.1 ± 13.8	44.7 ± 15.3	40.6 ± 14.2	<i>NS</i>
Family history of SCD	50 (18.1)	14 (35.9)	7 (21.8)	<i>0.03</i>
SCN5A gene mutation	22/78 (28.2)	8/17 (47)	2/12 (16.6) *†	<i>0.009</i>
Positive EPS	47/139 (33.8)	19/30 (63.3)	11/17 (64.7) §	<i><0.001</i>
VF/Fast polymorphic VT	40/7	16/3	9/2	
ICD recipients	46 (16.7)	25 (64.1)	27 (84.4) ‡	<i><0.001</i>
ICD recipients with appropriate shock (VF)	0 (0)	0 (0)	15 (46.8) ‡§	<i><0.001</i>
AF	8 (2.9)	3 (7.7)	7 (21.9) §	<i><0.001</i>
Quinidine administration	2 (0.7)	1 (2.6)	12 (37.5) ‡§	<i><0.001</i>

Values are expressed as n, n (%), n/n tested or mean ± SD. *P* refers to distribution of ECG parameters among the three groups (ANOVA for quantitative variables; Chisquare test for qualitative variables). **P* < 0.05 for FV/SCD vs syncope; †*P* < 0.05 for FV/SCD vs asymptomatic; ‡*P* < 0.001 for FV/SCD vs syncope; § *P* < 0.001 for FV/SCD vs asymptomatic. AF, atrial fibrillation; EPS, electrophysiological study; ICD, implantable cardioverter defibrillator; SCD, sudden cardiac death; VT, ventricular tachycardia; VF, ventricular fibrillation.

Table 3. Electrocardiographic parameters.

Parameters	Asymptomatic (N= 276)	Syncope (N=39)	FV/SCD (N=32)	P
First degree AV block	38 (13.8)	7 (17.9)	6 (18.8)	NS
QRS duration in lead II (ms)	94.5 ± 20.3	99.1 ± 19.6	97.8 ± 19.6	NS
QRS duration in lead V2 (ms)	109 ± 20.3	115.1 ± 19.6	115.6 ± 19.6 †	NS
Complete RBBB	23 (8.3)	6 (15.4)	4 (12.5)	NS
Incomplete RBBB	26 (9.4)	5 (12.8)	6 (18.7)	NS
LAFB	47 (17)	5 (12.8)	1 (3.1)	NS
fQRS	69 (25)	5 (12.8)	11 (34.4)	NS
Epsilon wave in lead V1	6 (2.2)	1 (2.6)	1 (3.1)	NS
V1R > 0.15 mV	139 (50.4)	16 (41.0)	23 (71.8)	NS
V6S > 0.15 mV	155 (56.2)	29 (74.3)	23 (71.8)	NS
V6S /R > 0.2 mV	117 (42.4)	21 (53.8)	18 (56.2)	NS
V1R amplitude (mV)	0.17 ± 0.15	0.15 ± 0.14	0.26 ± 0.20	NS
V6S amplitude (mV)	0.23 ± 0.21	0.25 ± 0.21	0.31 ± 0.29	NS
S wave in lead I				
S presence	154 (55.8)	20 (51.4)	31 (96.9) †§	<0.0001
S amplitude ≥ 0.1 mV	103 (37.3)	16 (41)	29 (90.6) †§	<0.0001
S duration > 40 ms	89 (32.2)	14 (35.9)	29 (90.6) †§	<0.0001
S amplitude-duration area ≥ 1mm2	83 (30.1)	13 (33.3)	29 (90.6) †§	<0.0001
DII S amplitude (mV)	0.28 ± 0.27	0.37 ± 0.36	0.31 ± 0.29	NS
DII S duration (ms)	41.2 ± 33.2	37.3 ± 22.5	48.5 ± 45.2	NS
DIII S amplitude (mV)	0.28 ± 0.26	0.36 ± 0.33	0.31 ± 0.24	NS
DIII S duration (ms)	41.4 ± 24.2	41.3 ± 24.4	37.1 ± 35.2	NS
Early repolarisation pattern	22 (7.9)	6 (15.4)	2 (6.2)	NS
QTc in lead DII (ms)	395.1 ± 33.4	402 ± 32.5	397.7 ± 32.9	NS
Tp-Te in lead V2 (ms)	72.2 ± 21.8	75 ± 14.2	90 ± 25.4*†	0.044
Tp-Te in lead V6 (ms)	82.6 ± 15.1	78.6 ± 11.1	88.4 ± 13.5*†	NS

Values are expressed as mean ± SD or N/ %. P refers to distribution of ECG parameters among the three groups (ANOVA for quantitative variables; Chisquare test for qualitative variables). *P < 0.05 for FV/SCD vs syncope; †P < 0.05 for FV/SCD vs asymptomatic; ‡P < 0.001 for FV/SCD vs syncope; § P < 0.001 for FV/SCD vs asymptomatic. AV, atrio-ventricular; fQRS, fragmented QRS; LAFB, left anterior fascicular block; ms, milliseconds; QTc, QT corrected; RBBB, right bundle branch block; Tp-Te, T peak-T end; VF, ventricular fibrillation.

FIGURE 1 Box Plot of Results Obtained for S Waves in Lead I in Patients Who Presented With VF/SCD, Developed Syncope, and Remained Asymptomatic During Follow-Up

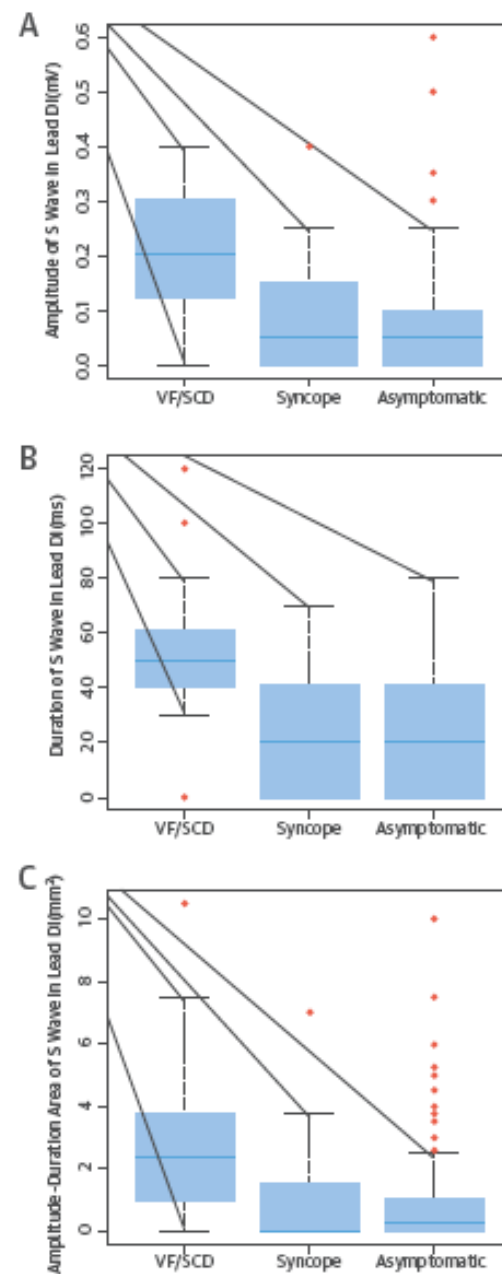
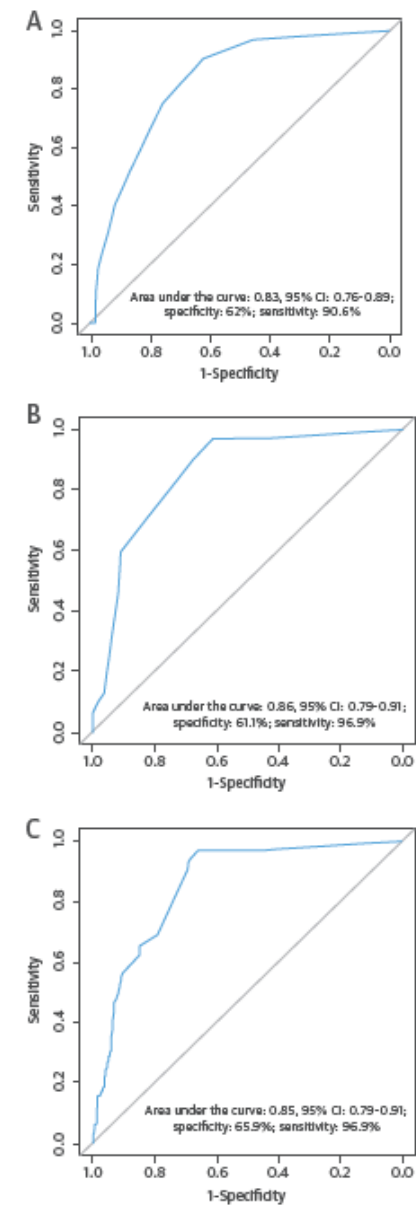


FIGURE 2 Receiver-Operating Characteristic Curves for Amplitude and Duration of the S-Wave in Lead I



(A) Receiver-operating characteristic curve for amplitude of the S-wave in lead I. (B) Receiver-operating characteristic curve for duration of the S-wave in lead I. (C) Receiver-operating characteristic curve for the product of the amplitude and duration of the S-wave in lead I. CI = confidence interval.

FIGURE 4 ECGs of Patients With BrS That Show a Spontaneous Coved-Type Pattern Without a Significant S-Wave in Lead I

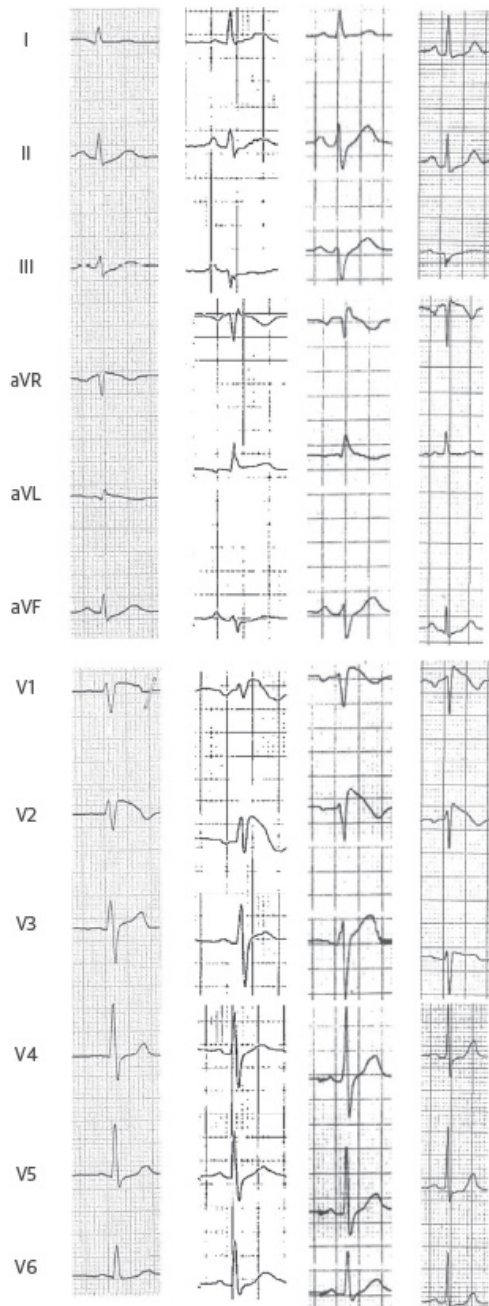
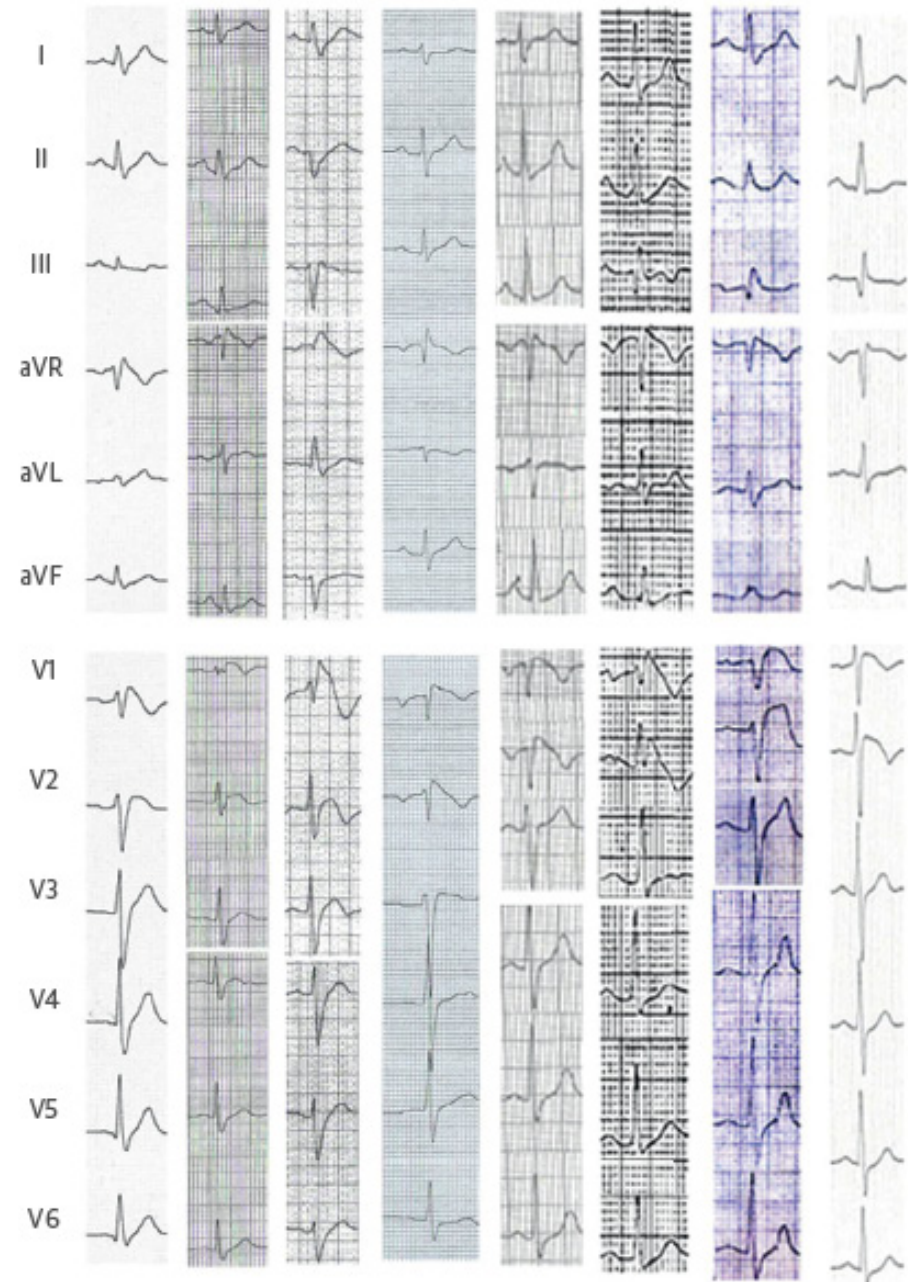


FIGURE 3 ECGs of Patients With BrS That Show the Spontaneous Coved-Type Pattern and a Significant S-Wave in Lead I



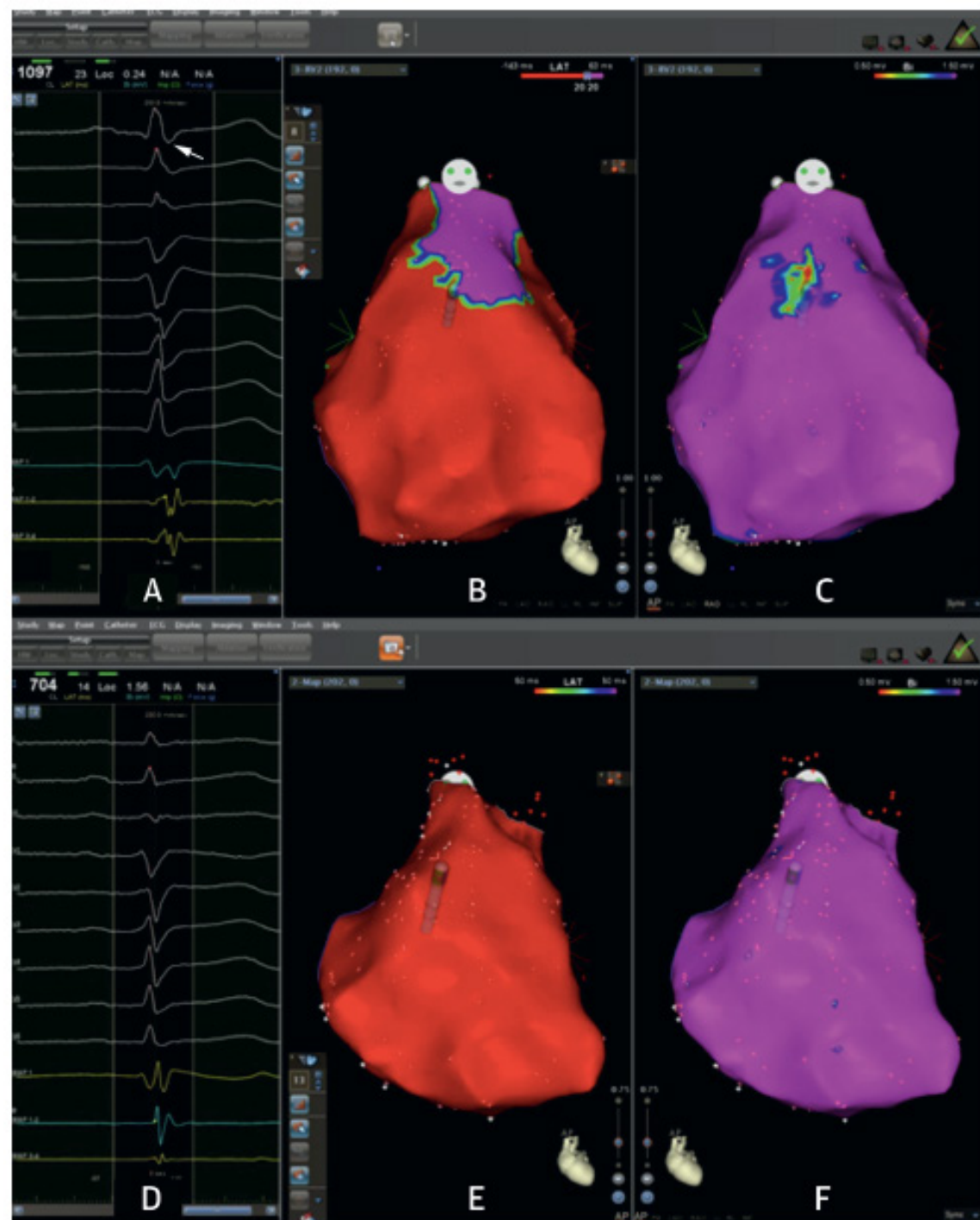
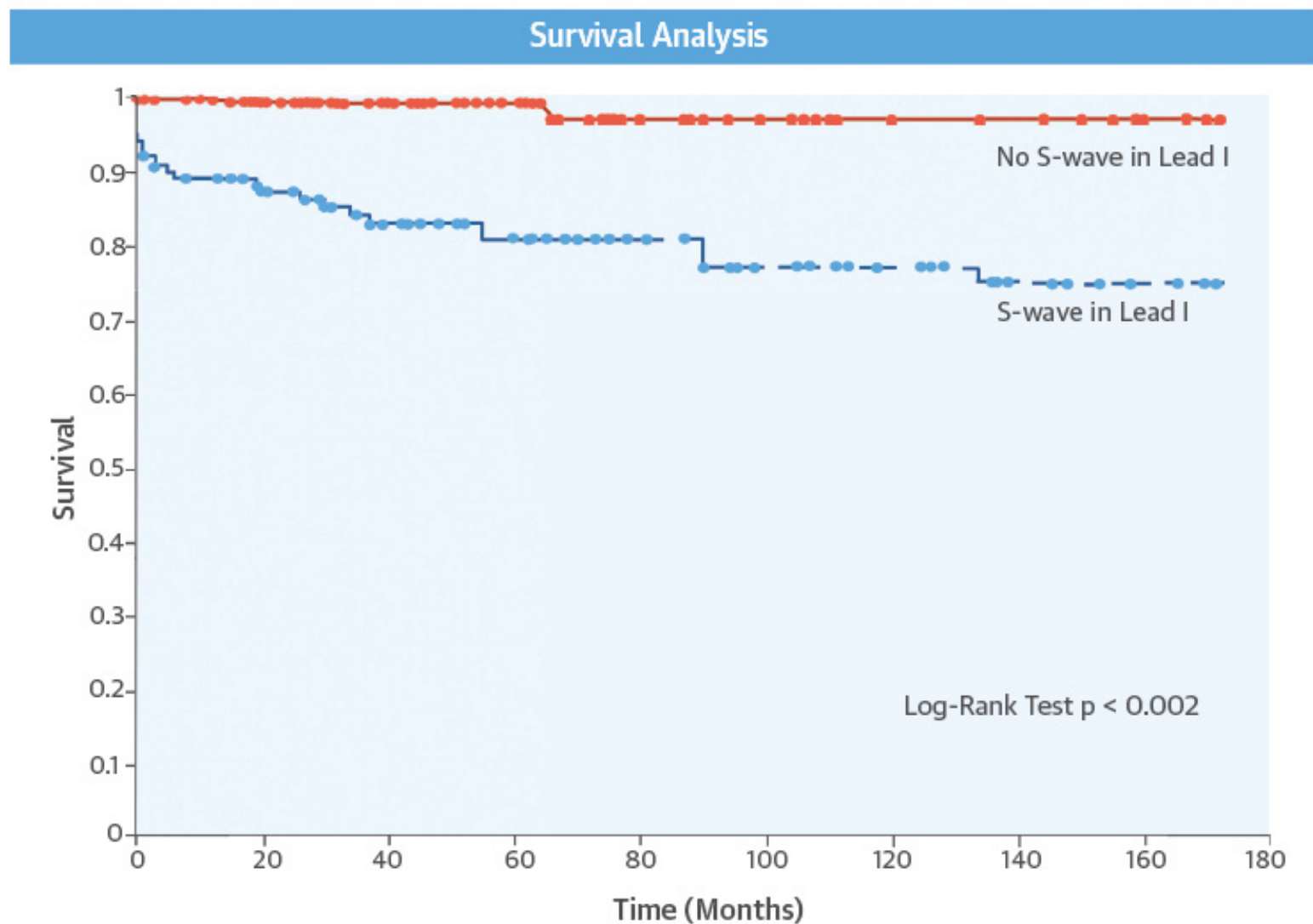


Table 4. Probability of VF/SCD during follow-up depending on clinical and electrocardiographic parameters: univariate and multivariate analysis

	Univariate analysis			Multivariate analysis		
	HR	95% CI	<i>P value</i>	HR	95% CI	<i>P value</i>
Male sex	0.44	0.13-1.46	0.18			
Age	0.96	0.93- 0.99	0.018	0.5	0.15-1.68	0.26
Family history of SCD	1.32	0.56-3.15	0.52			
Positive EPS	1.57	0.72- 3.48	0.26			
AF	5.53	2.3- 13.4	0.00015	2.1	0.83- 5.39	0.11
SCN5A mutation	0.68	0.45-1.02	0.06	0.73	0.48- 1.11	0.14
First AV block	1.5	0.57-4.0	0.41			
QRS duration >120 ms	1.9	0.8-4.93	0.14			
fQRS	1.9	0.89-4.13	0.09	0.99	0.44- 2.24	0.98
Epsilon	1.4	0.19-10.6	0.72			
V1R > 0.15 mV	2.4	0.47-12.4	0.29			
V6S > 0.15 mV	0.52	0.18-1.48	0.22			
V6S /R > 0.2 mV	3.3	0.61-18.2	0.17			
S amplitude > 0.1 mV in lead DII	0.52	0.18-1.48	0.22			
S duration > 40 ms in lead DII	0.79	0.24-2.67	0.71			
S amplitude > 0.1 mV in lead DIII	0.99	0.22-4.46	0.99			
S duration > 40 ms in lead DIII	1.56	0.31-8.1	0.59			
S wave in lead DI						
S presence	20.9	2.84-154.6	0.003	7.9	0.89- 70.2	0.06
S amplitude > 0.1 mV	12.6	3.8-41.9	<0.0001	9.7	2.8- 33.2	0.0003
S duration > 40 ms	38	5.16-280.7	<0.0001	30.9	4.1- 231.9	0.0008
S area > 1 mm2	16.8	5.05-55.8	<0.0001	9.3	3.9- 45.7	<0.0001
Early repolarisation	0.7	0.17-3.13	0.68			
QTc	1.001	0.99-1.01	0.66			
Tp-Te in lead V2	1.028	1.013- 1.042	< 0.0001	1	0.99-1	0.88
Tp-Te in lead V6	1.025	1.002-1.048	0.03	1	0.98-1	0.87

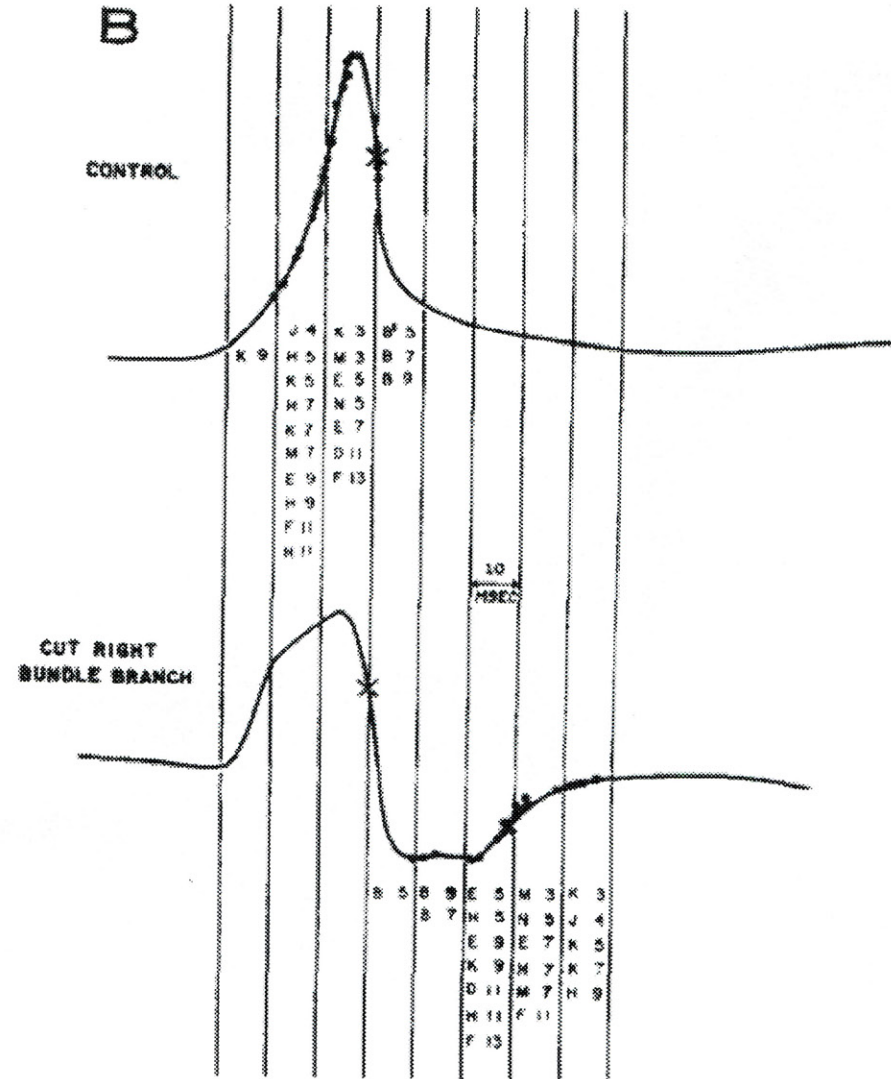
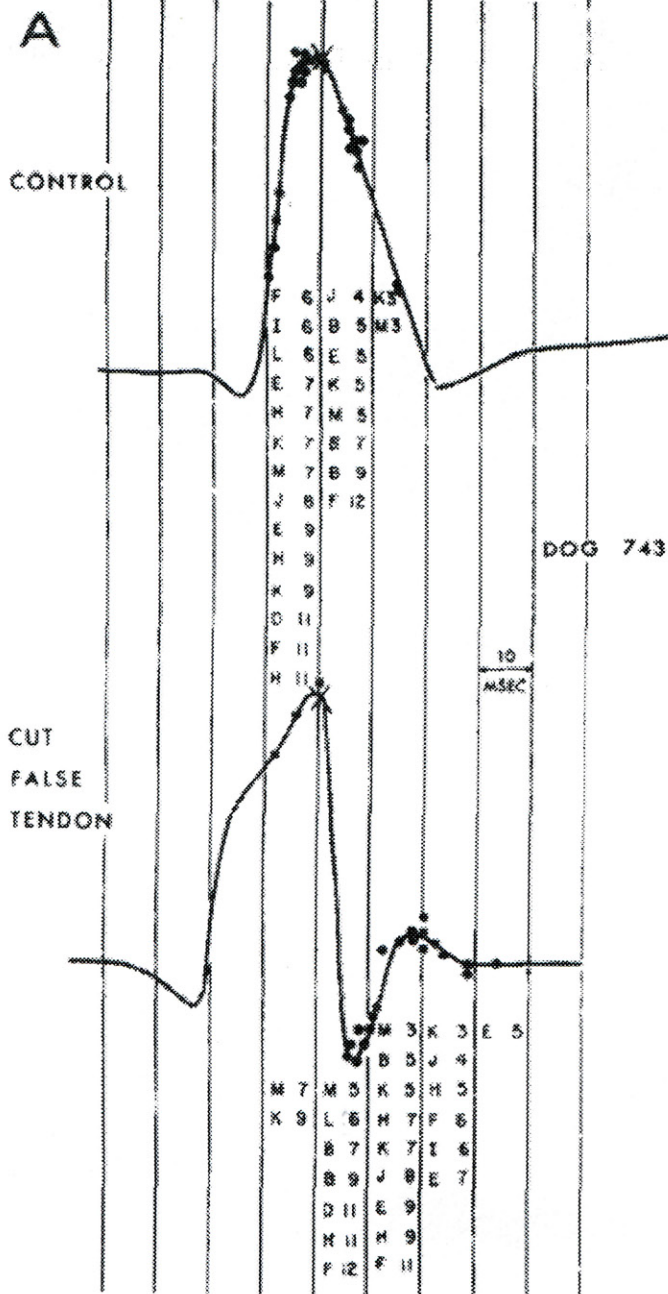
AF, atrial fibrillation; AV, atrioventricular; EPS, electrophysiological study; fQRS, fragmented QRS; Ms, milliseconds; Tp-Te, T peak-T end



Calò, L. et al. J Am Coll Cardiol. 2016; 67(12):1427-40.

Kaplan-Meier analysis of freedom from ventricular fibrillation/sudden cardiac death events during follow-up in patients with S waves in lead I versus those without S waves in lead I.

BLOCCO DI BRANCA
DESTRA

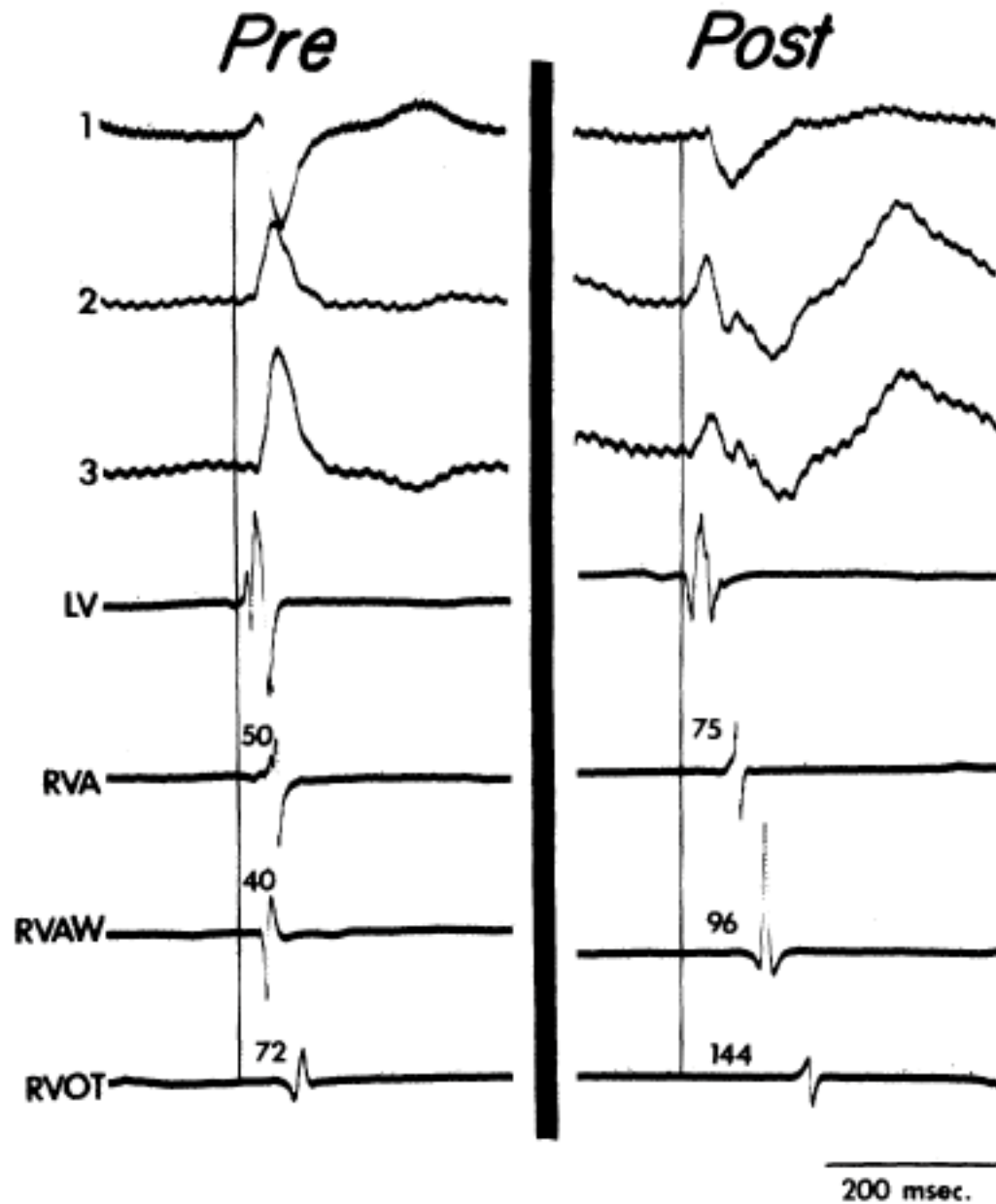


Postoperative Right Bundle Branch Block: Identification of Three Levels of Block

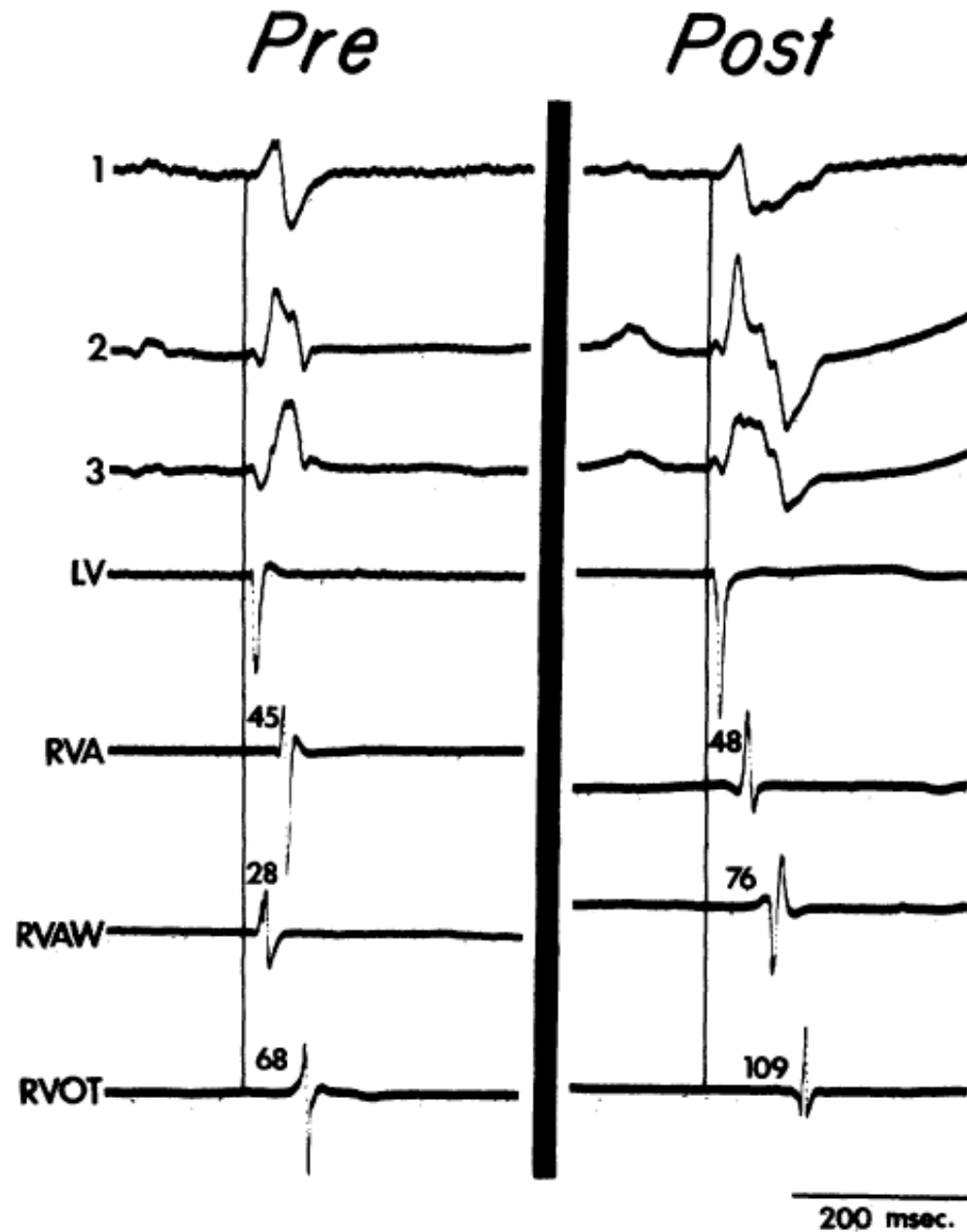
LEONARD N. HOROWITZ, M.D., JAMES A. ALEXANDER, M.D.,
AND L. HENRY EDMUNDS, JR., M.D.

SUMMARY It has been postulated that postoperative right bundle branch block (RBBB) may be produced by conduction block at any of several sites. In this study the site of block and resultant pattern of ventricular activation were documented in 20 patients in whom RBBB developed during repair of congenital cardiac defects. Intraoperative epicardial and endocardial mapping and recording from the right ventricular specialized conduction system were performed before and after repair in each patient. In eight patients right bundle branch (RBB) conduction was interrupted proximally in the area of the ventricular septal defect. Right ventricular (RV) activation in these patients was delayed at all sites. In five patients RBB conduction was interrupted distally in the area of the moderator band. RV activation in these patients was delayed at most sites; however, the apical septal sites were activated normally. In seven patients, RBB conduction was interrupted terminally in the area of the terminal fascicular network. In these patients RV activation was delayed only in basilar areas. We conclude that at least three distinct types of postoperative RBBB exist and can be identified by differences in RV activation.

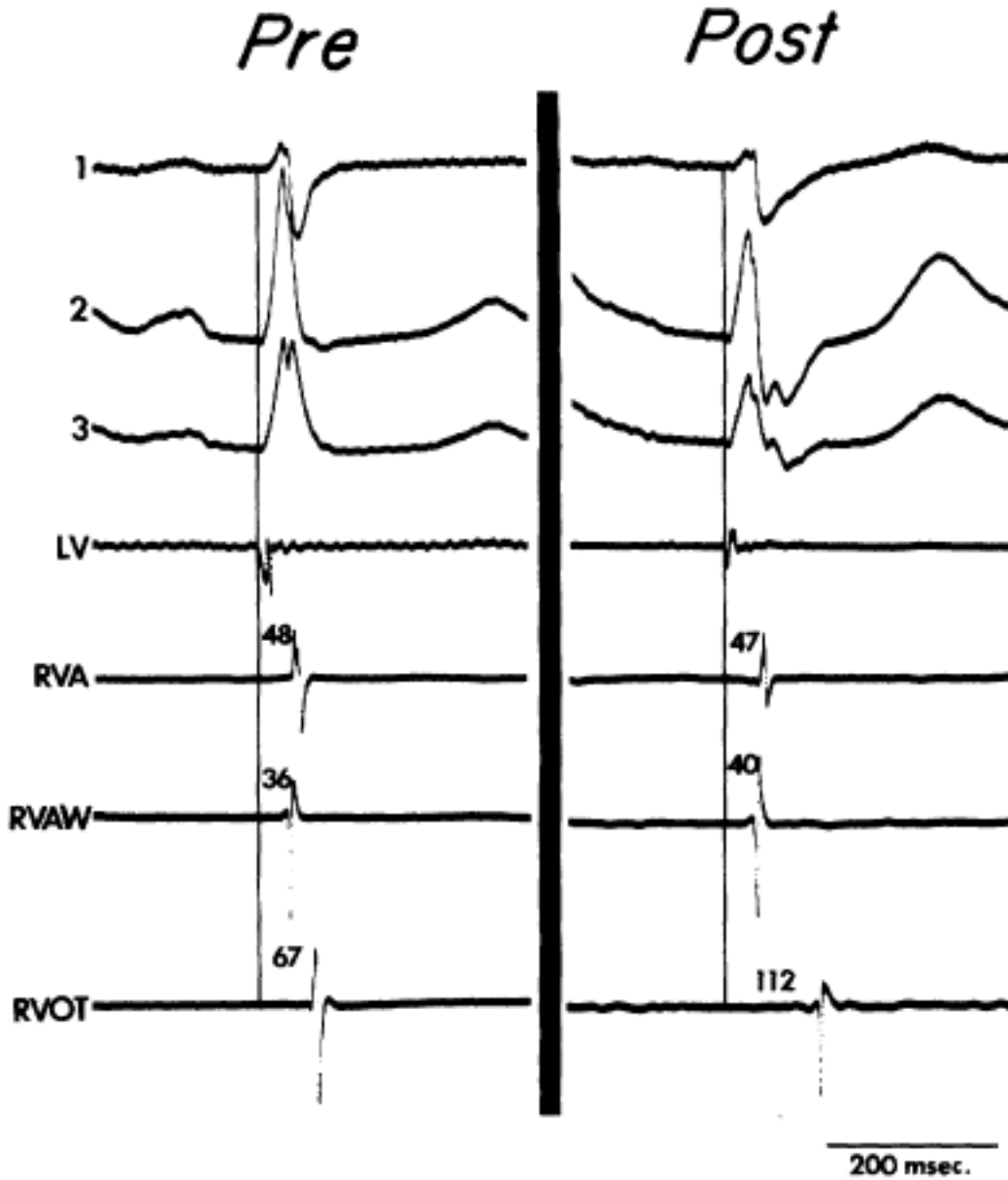
Proximal Right Bundle Branch Block



Distal Right Bundle Branch Block



Terminal Right Bundle Branch Block

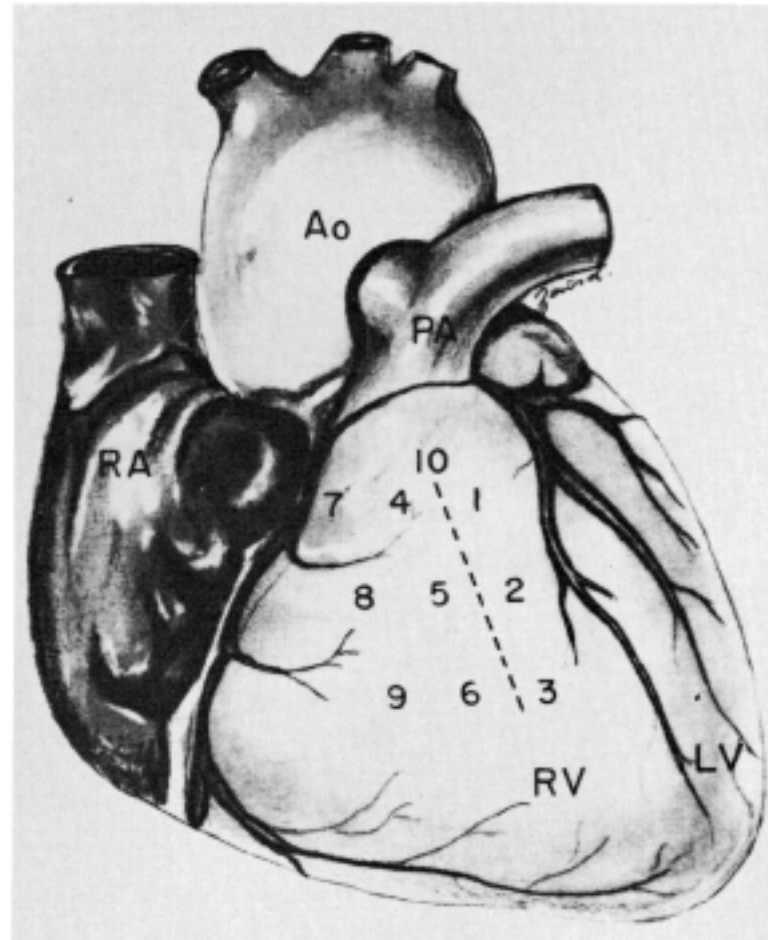


Etiology of Right Bundle-Branch Block in Patients Undergoing Total Correction of Tetralogy of Fallot

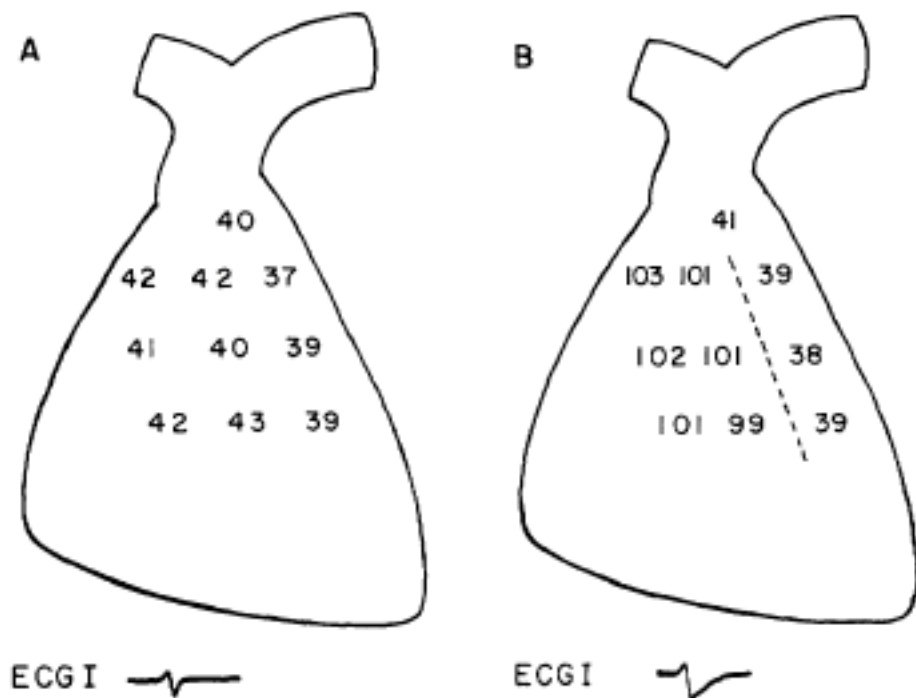
By HENRY GELBAND, M.D., ALBERT L. WALDO, M.D., GERARD A. KAISER, M.D.,
FREDERICK O. BOWMAN, JR., M.D., JAMES R. MALM, M.D.,
AND BRIAN F. HOFFMAN, M.D.

SUMMARY

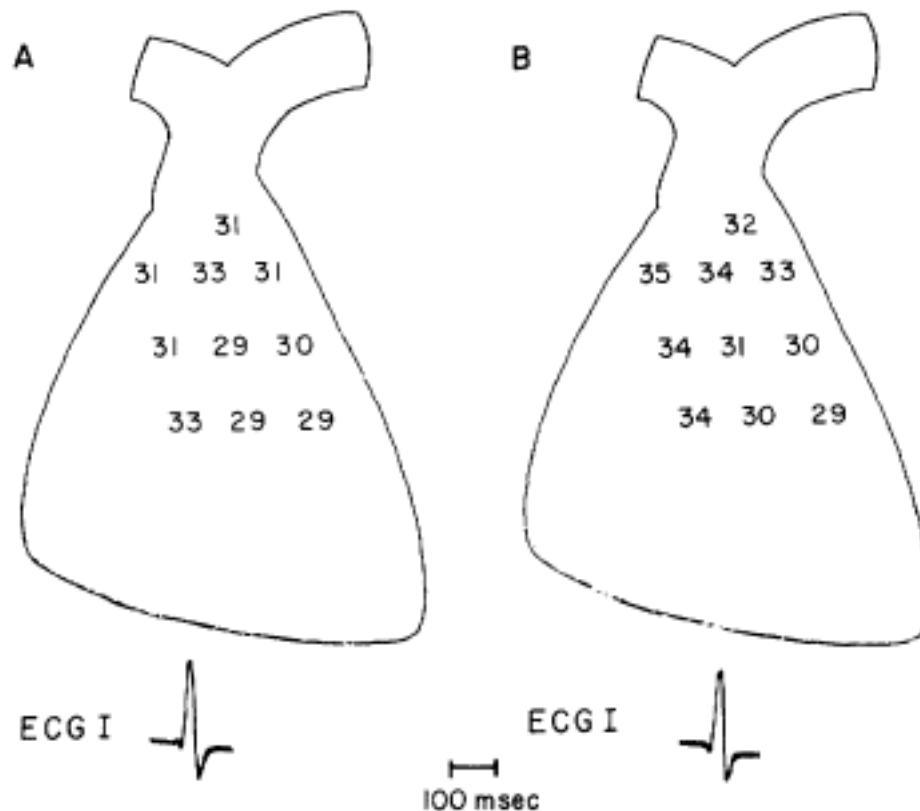
The electrocardiographic (ECG) pattern of right bundle-branch block (RBBB) occurs routinely in patients after open-heart surgery for tetralogy of Fallot (TF). To determine the etiology of the RBBB pattern, 14 patients with TF, seven with ventricular septal defects (VSD), and one with pulmonary stenosis (PS) were studied during and after cardiac surgery. Bipolar electrograms from 10 selected right ventricular epicardial sites were recorded simultaneously with an ECG. Records were obtained before and immediately after vertical right ventriculotomy, after infundibular resection, and after repair of a ventricular septal defect (VSD). The vertical ventriculotomy alone was always associated with significant prolongation of the time of epicardial activation only to the recording sites lateral to the incision with prolongation of the QRS complex by an average of 39 msec, and with the appearance of an RBBB ECG pattern. Infundibular resection and VSD repair were not associated with any changes in the electrophysiologic parameters measured. A retrospective analysis of 251 patients with TF, VSD, and PS revealed a 100% incidence of RBBB pattern in the electrocardiograms of only those who had undergone ventriculotomy. It can be concluded that the RBBB pattern seen postoperatively in patients with TF is due to changes in right ventricular activation secondary to the vertical ventriculotomy.

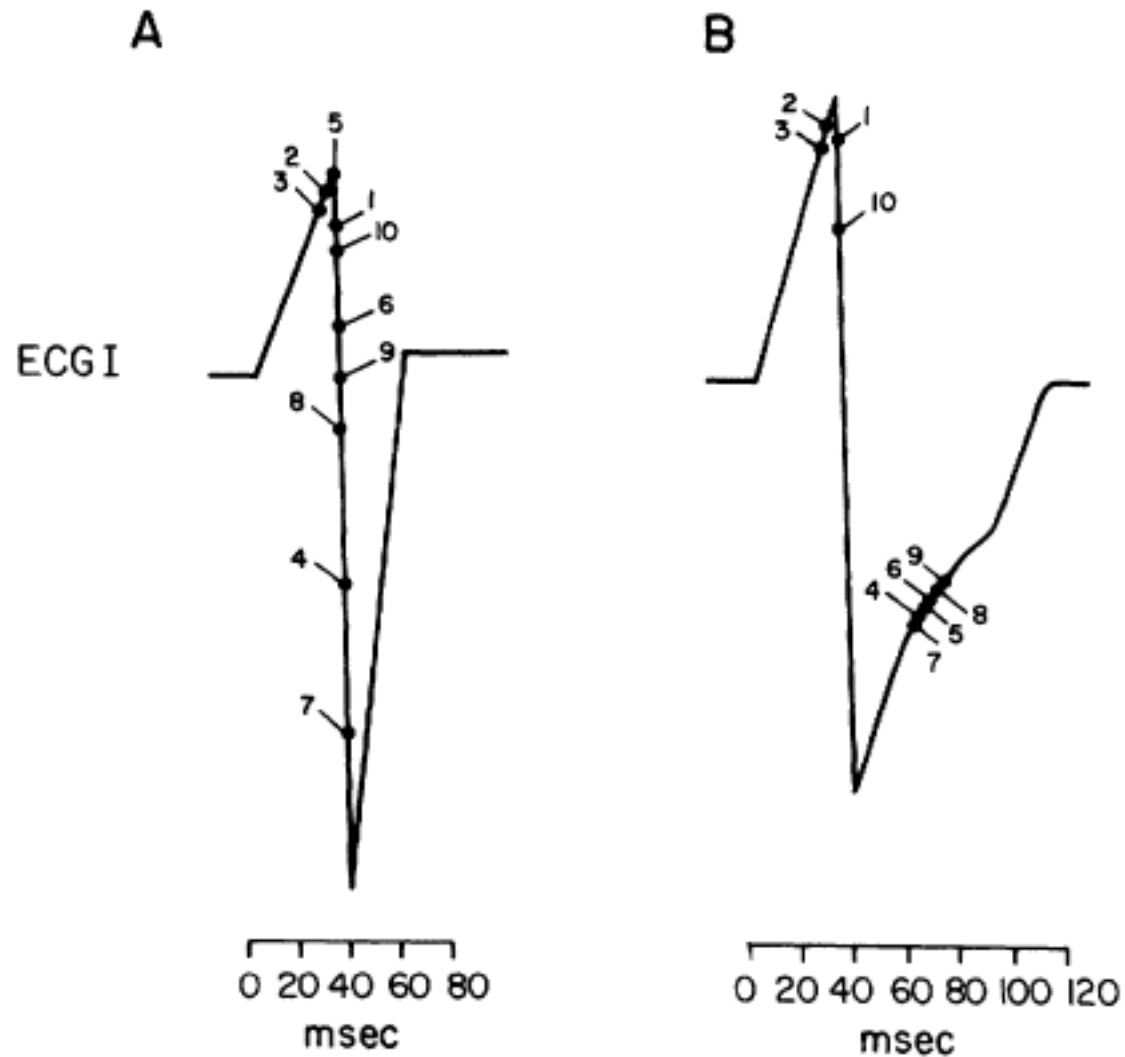


**Effect of a vertical
ventriculotomy on the activation
times to the right ventricular
epicardial recording sites
in a representative patient**



**Right ventricular epicardial
activation times after repair
of VSD via the right atrium**



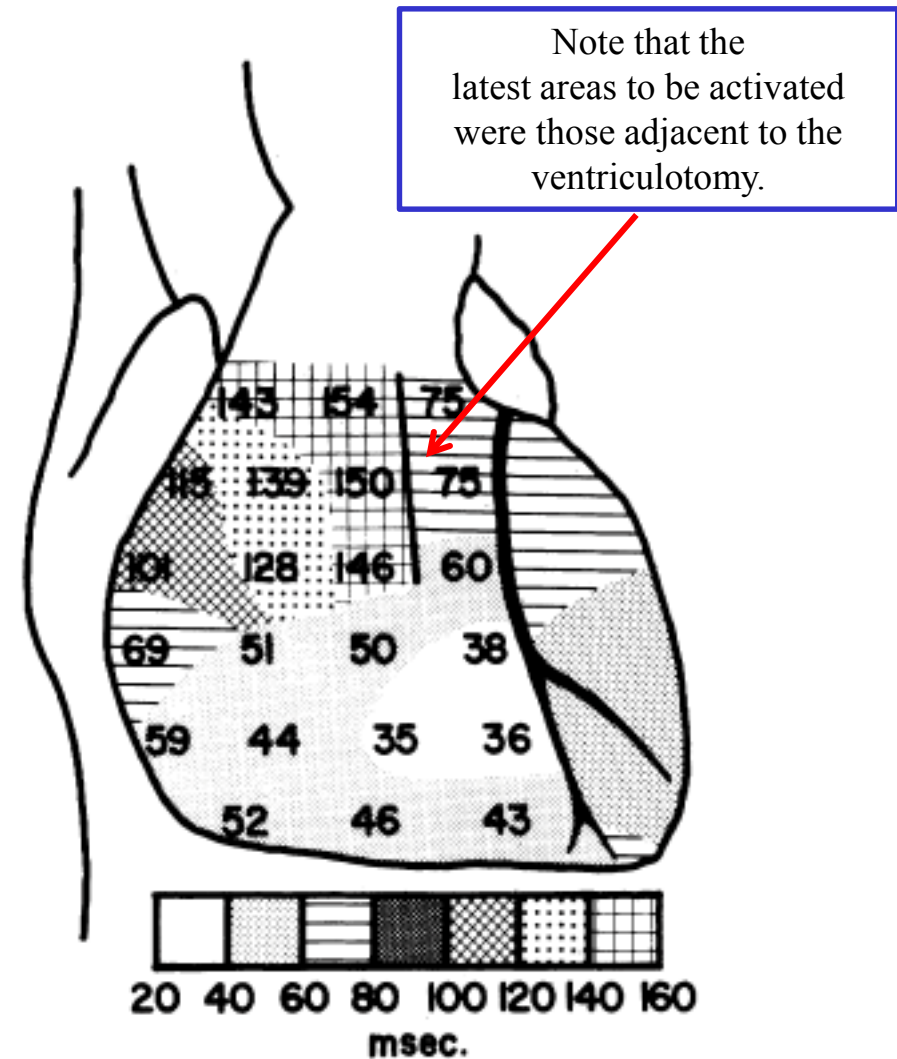
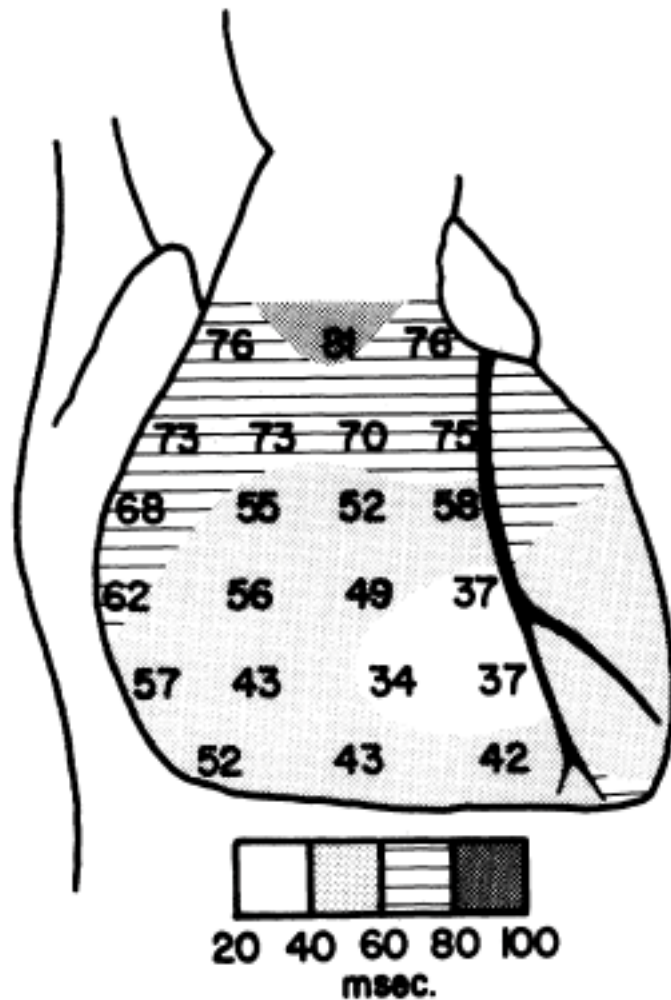


Temporal relation of the time of activation of the 10 epicardial sites plotted on an electrocardiographic lead-1 QRS complex before (A), and immediately after (B), ventriculotomy in patient 9.

The Mechanism of Apparent Right Bundle Branch Block After Transatrial Repair of Tetralogy of Fallot

LEONARD N. HOROWITZ, M.D., MICHAEL B. SIMSON, M.D., JOSEPH F. SPEAR, PH.D.,
MARK E. JOSEPHSON, M.D., E. NEIL MOORE, D.V.M., PH.D., JAMES A. ALEXANDER, M.D.,
JOHN A. KASTOR, M.D., AND L. HENRY EDMUNDS, JR., M.D.

SUMMARY The electrocardiographic pattern of right bundle branch block (RBBB) is routinely observed after transatrial repair of tetralogy of Fallot even though no ventriculotomy has been performed. The mechanism of this conduction disturbance was studied in 16 patients with tetralogy of Fallot and one patient with infundibular pulmonic stenosis. Preoperative ECGs and vectorcardiograms showed right ventricular hypertrophy and no RBBB. Epicardial activation maps were obtained before and after total surgical repair in all patients and after infundibular resection but before closure of ventricular septal defect (VSD) in four of these patients. After infundibular resection, RBBB appeared and activation was markedly delayed (> 30 msec) over the pulmonary outflow tract, but was unchanged over the body of the right ventricle. No further changes in ventricular activation occurred after closure of the VSD. This study shows that RBBB after transatrial repair of tetralogy of Fallot is usually produced by infundibular resection, but not by VSD closure, and is associated with delayed activation of the pulmonary outflow tract and base of the right ventricle which results from damage to portions of the right ventricular conduction system.



Epicardial activation in tetralogy of Fallot before (A) and after (B) transventricular repair. After ventriculotomy right bundle branch block and delay in outflow tract activation appeared.

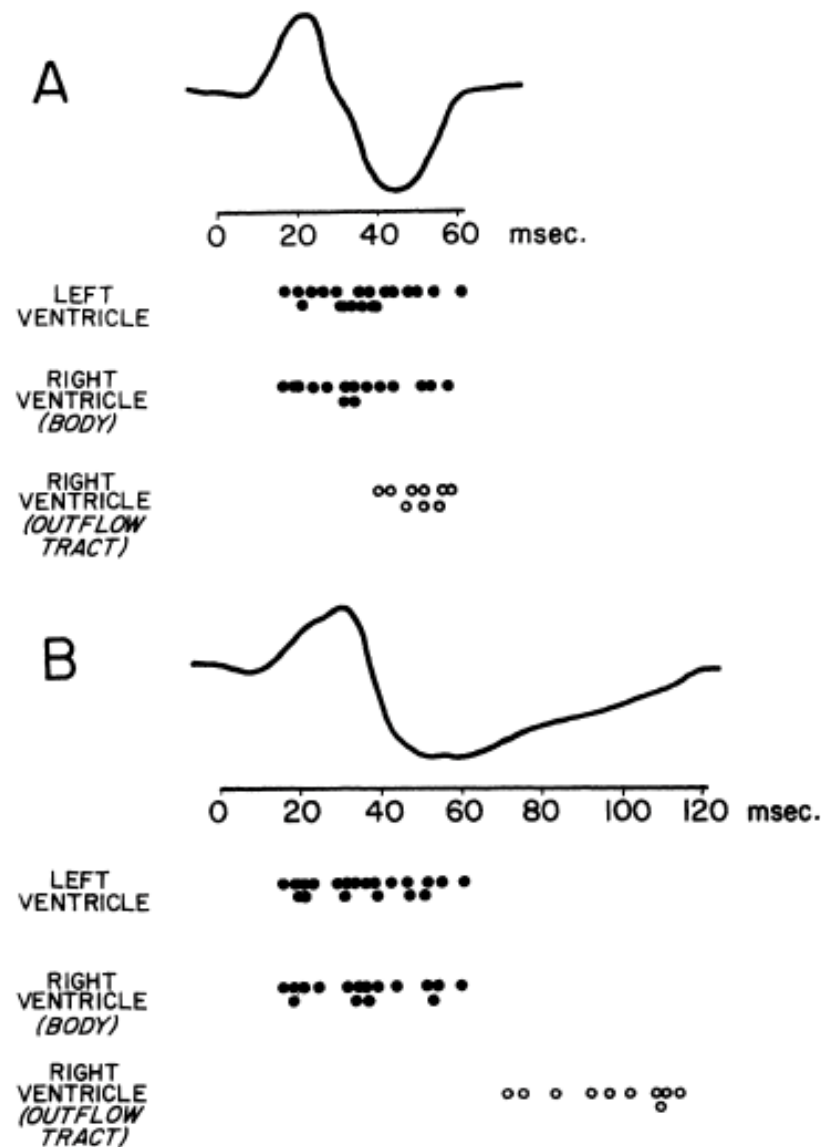
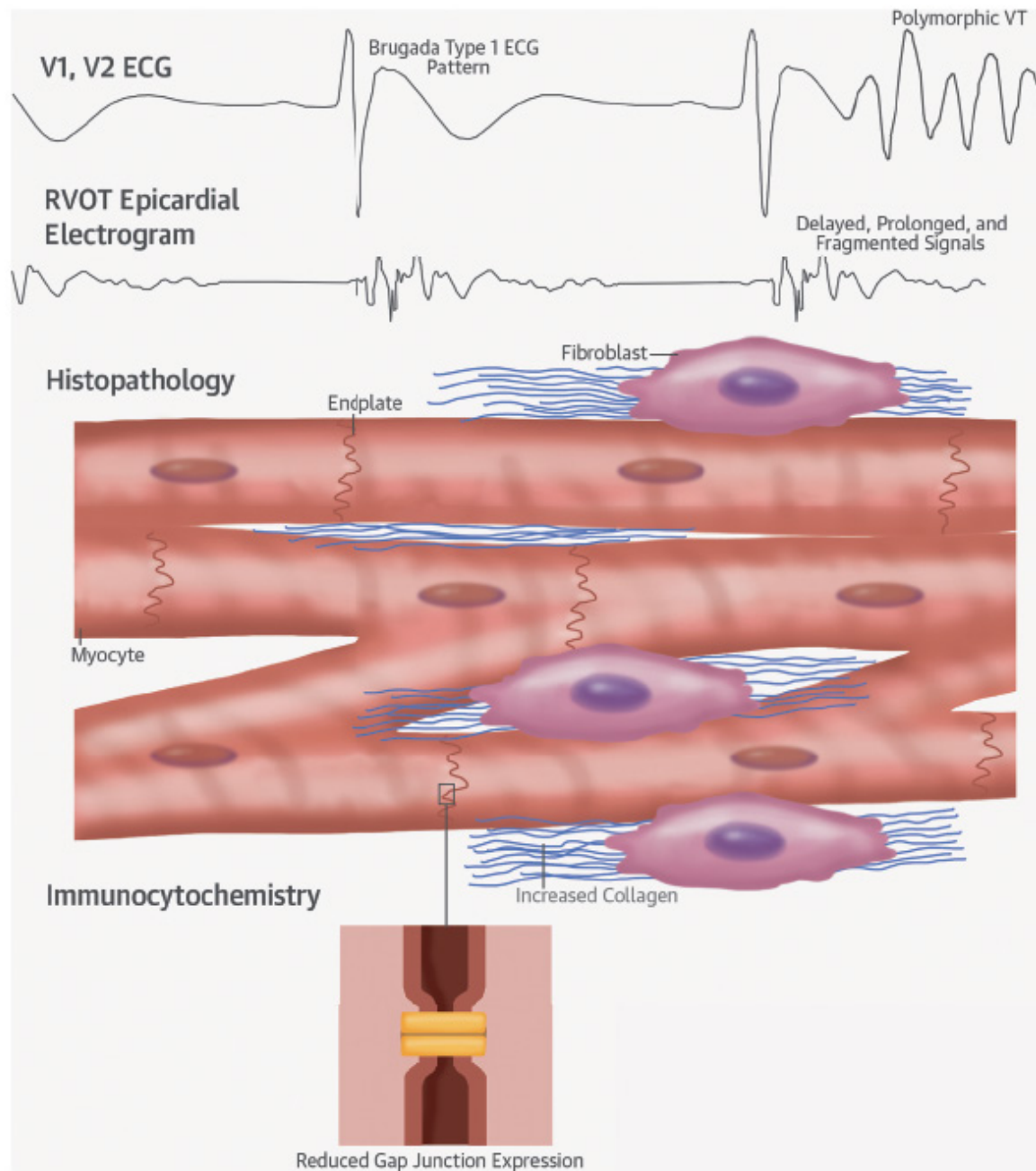


FIGURE 7. Epicardial activation data plotted with a lead I QRS complex before (A) and after (B) transatrial repair of tetralogy of Fallot (patient 6). Epicardial activation times of the sites on the left ventricle (solid circles), body of the right ventricle (solid circles) and outflow tract of the right ventricle (open circles) are plotted on a common time axis with a single QRS complex from lead I recorded before (A) and after (B) repair. In A, QRS duration is 62 msec and activation of the outflow tract occurred between 40–58 msec. In B, the QRS duration is 114 msec and right bundle branch block is present. Activation of the sites on the left ventricle and body of the right ventricle was unchanged; however, activation of sites on the outflow tract was delayed 35–56 msec. The sites in the outflow tract are all activated during the slurred S wave of the QRS complex.



SUBSTRATE

FA

TRIGGER

AUTONOMIC
NERVOUS SYSTEM

