

Congenital Anomalies of Coronary Arteries: diagnosis and management

XXVIII GIORNATE CARDIOLOGICHE TORINES
October 13-15, 2016, Turin

Naser Ammash, MD

Professor of Medicine
Practice Chair, CV Department

Mayo Clinic Rochester

Coronary Artery Anomalies

Ectopic
Coronary Artery
Origin

Coronary Artery
Aneurysm

Coronary Artery
Fistulae

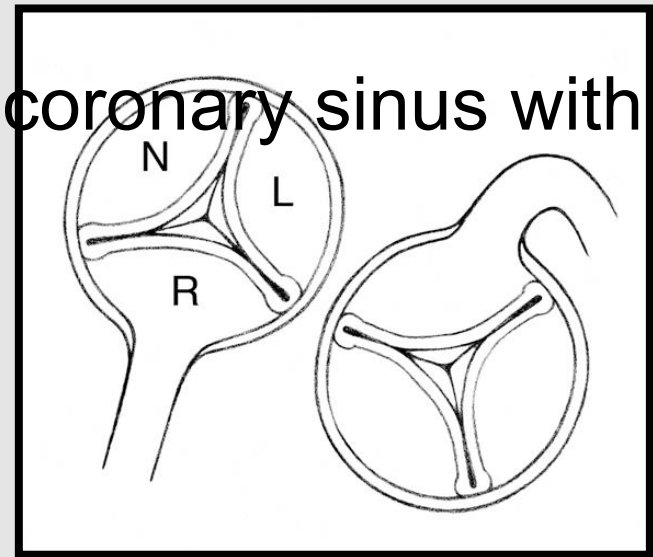
Coronary Artery
Bridge

Some are life threatening

Coronary Artery Anomalies

Malignant Ectopic Origin

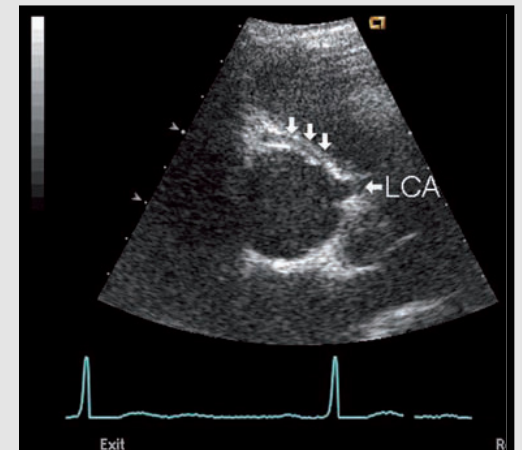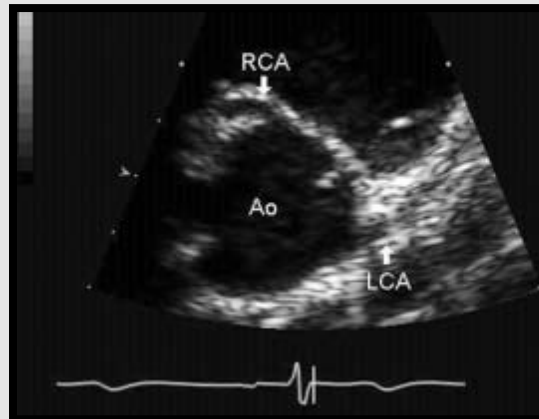
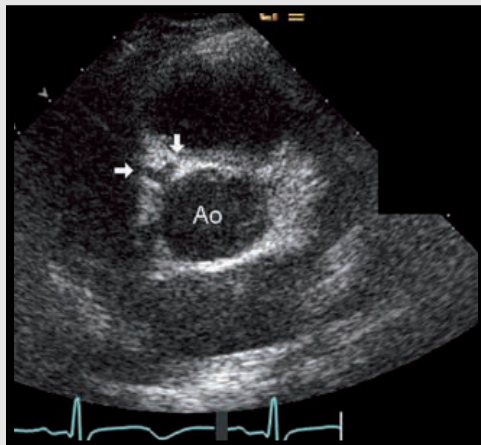
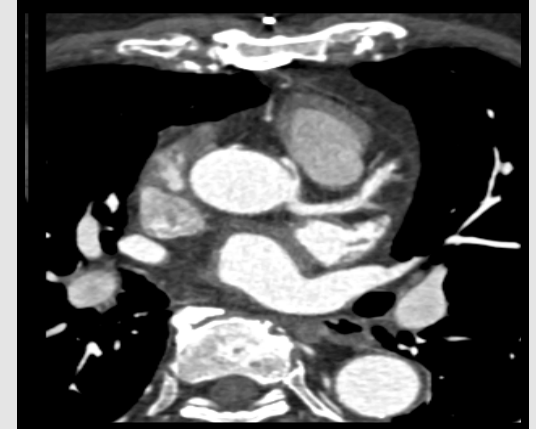
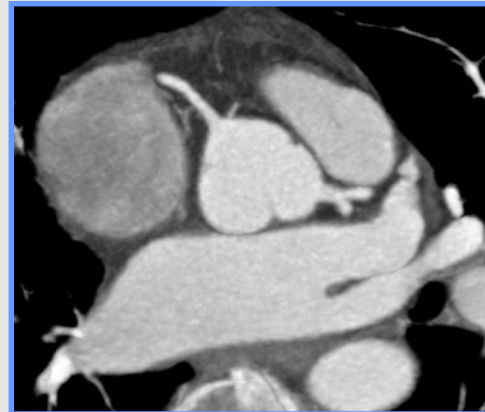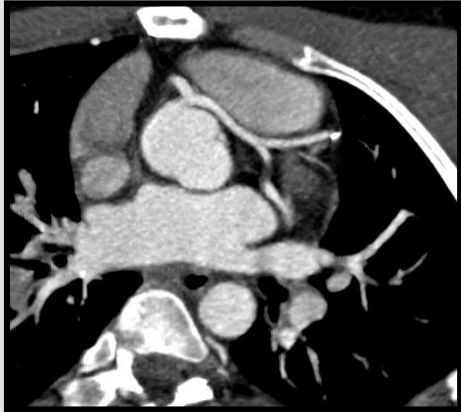
- Left main CA from Pulmonary Artery (ALCAPA)
- Anomalous CA from opposing coronary sinus with intra-arterial course
 - LCA from Right CA
 - RCA from Left Sinus



ALCAPA
Anomalous LCA from PA

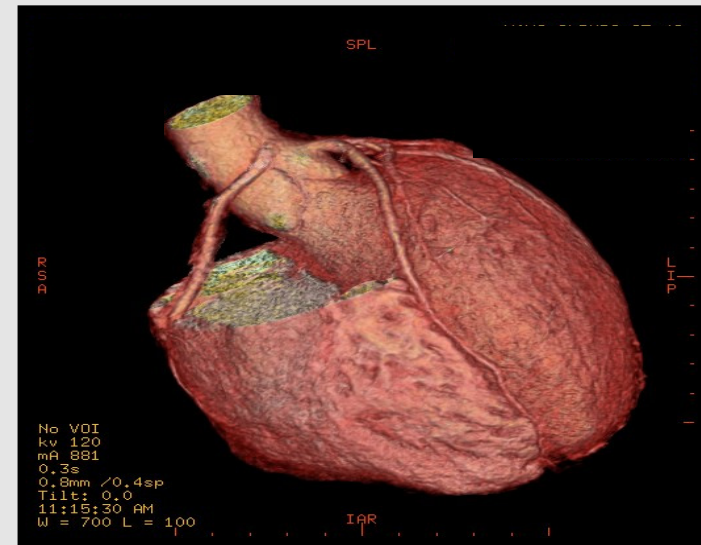Coronary Artery Anomalies

Intra-arterial course



The Hockey Player

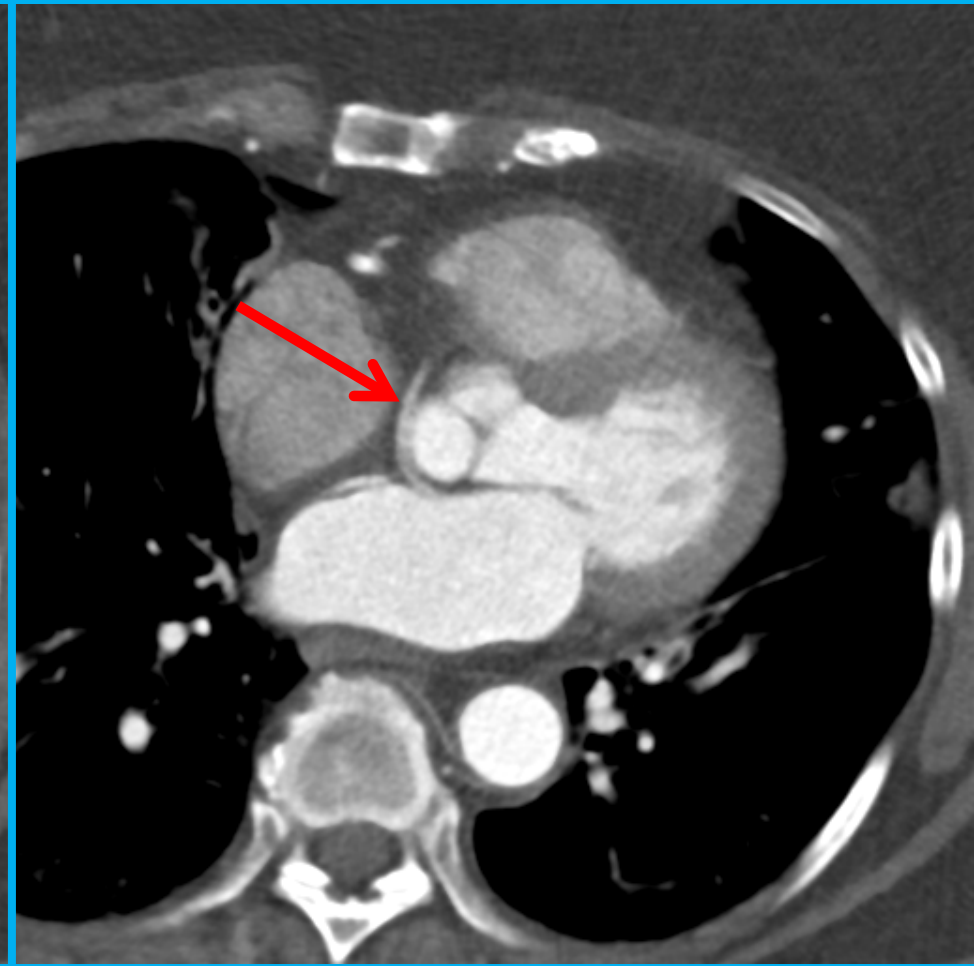
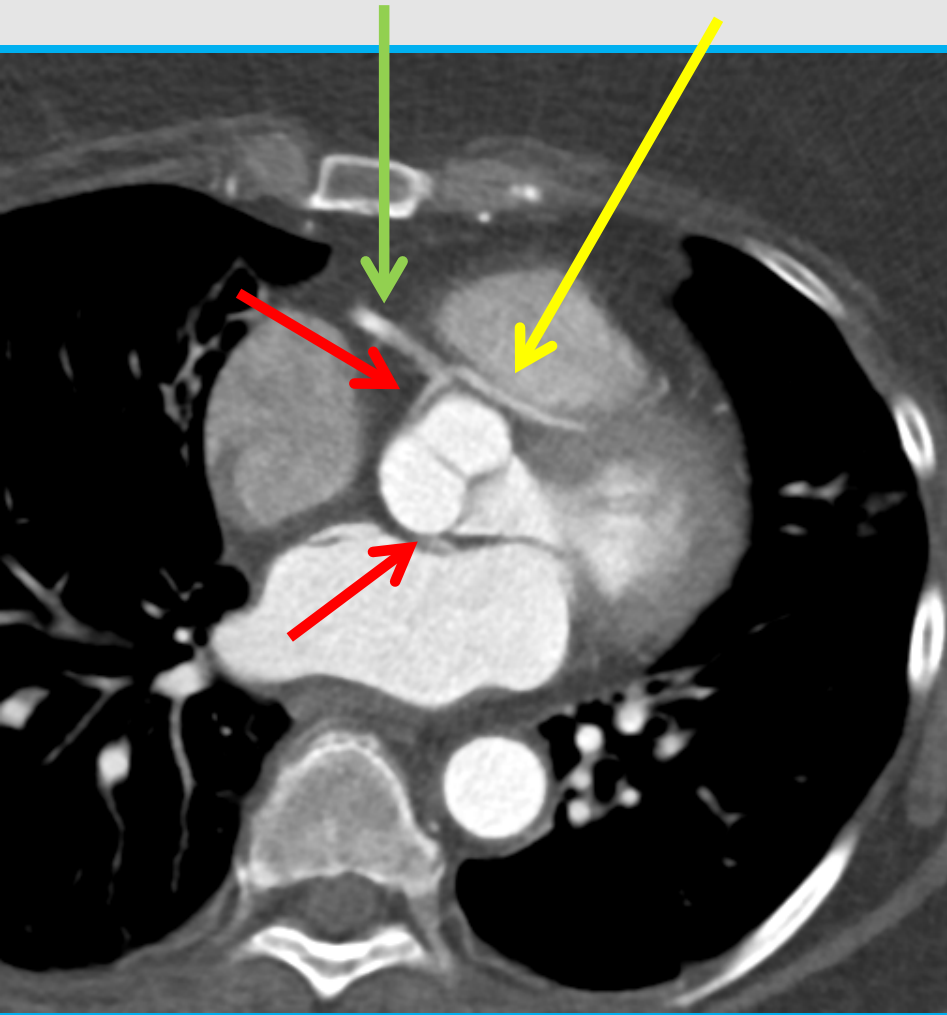
- 34 yrs. old male hockey player
- Intermittent chest pain for 2 years
 - Followed by shortness of breath and lightheadedness
- No history of syncope
- Grandfather had MI at 38 years
- Normal cardiac exam
- Normal EKG



The Concerned Spouse

- 69 yrs. old lady
- Jaw pain while playing a game on computer
 - Two minutes duration without dyspnea
- Unpredictable rest CP: -ve Cardiolite 9 yrs. ago
- Mild DOE but no syncope
- Father died of cardiomyopathy at age 63 yrs.
- Normal cardiac exam
- Normal EKG

The Concerned Spouse

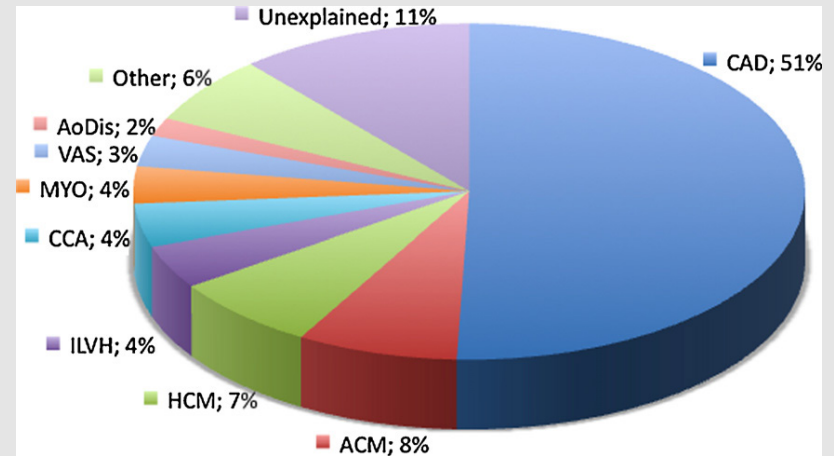


Sudden Death in 387 Young Competitive Athletes

Cause	Athletes	
	No.	%
Hypertrophic cardiomyopathy	102	26.4
Commotio cordis	77	19.9
Coronary artery anomalies	53	13.7
LVH of indeterminate cause	29	7.5
Myocarditis	20	5.2
Ruptured Ao aneurysm (Marfan syndrome)	12	3.1
Arrhythmogenic RV cardiomyopathy	11	2.8
Tunneled (bridged) coronary artery	11	2.8
Ao valve stenosis	10	2.6
Atherosclerotic CAD	10	2.6

Pathology of SD during recreational sports

- Spain 1995-2010
- 168 / 8862 SDs (1.8%)
 - cycling (29.1%)
 - soccer (25.5%)
- Mean age was 36.6 ± 15.6 yrs.
 - 81 (48.2%) were ≤ 35 YO
 - 87 (51.7%) were > 35 YO



		CAD	ACM	HC M	ILVH	CCA	MYO	AoS	No Cause
Total	168 (100%)	85(50.5%)	13 (7.7%)	12 (7.1%)	7 (4.1%)	7 (4.1%)	6 (3.5%)	5 (2.9%)	19 (11.3%)
9–35 (22.8 ± 7)	81 (48.2%)	11 (13.5%)	12(14.8%)	8 (9.8%)	7 (8.6%)	5 (6.1%)	4 (4.9%)	3 (3.7%)	19 (23.4%)
36–79 (49.4 ± 9)	87 (51.7%)	74 (85%)	1 (1.1%)	4 (4.5%)	0	2 (2.2%)	2 (2.2%)	2 (2.2%)	0

Ectopic Coronary Artery Origin

What to do?

- Everybody needs repair
- Be selective in recommending repair

What criteria to use?

Some are life threatening

Account for: 1.2% of all SCD

14% of SCD in athletes

4% of recreational sport death

Media Attention

Potential Liability

Ectopic Coronary Artery Origin

What we know

- 25-yr review of autopsies in military recruits
 - 6.3 Million ; age 18-35 years
- 126 sudden nontraumatic death
 - Cardiac abnormalities in 64 (51%)
 - Anomalous CA origin in 21 (17% of SCD)
 - All Lt CA from Rt sinus + intra-arterial
 - 11 had prior CP, dyspnea or syncope



Can Anomalous RCA be a Killer?

Management of Anomalous Coronary Artery From the Contralateral Coronary Sinus*

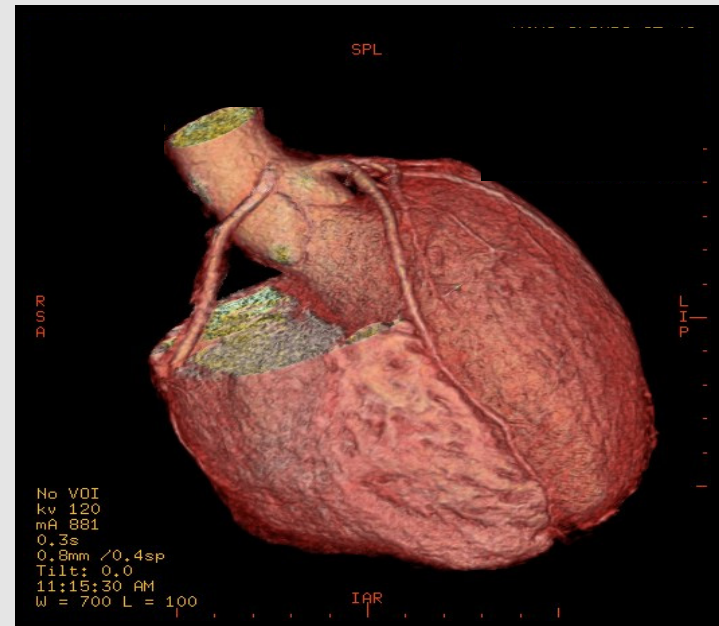Welton M. Gersony, MD, FACC
New York, New York

- 25 yr review of clinical reports
- 10 ARCA deaths
 - All sudden deaths
 - All asymptomatic prior to event
 - Age 10-30 yr

ARCA, more prevalent, is less risky but can be deadly with SCD as the first manifestation

The Hockey Player

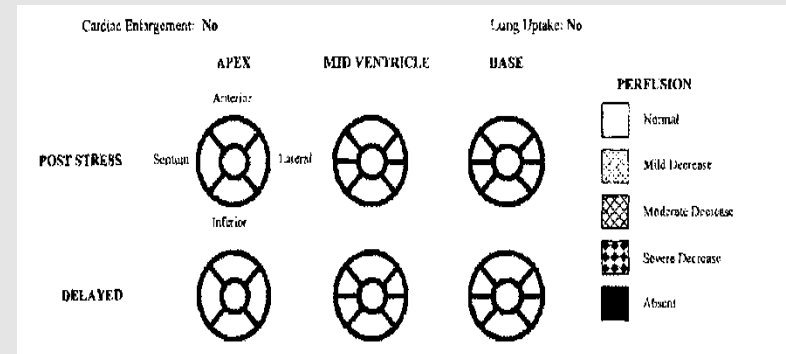
1. Observation
2. PC intervention
3. Surgical repair
4. More information



The Hockey Player

- Holter:
 - Max HR = 197 BPM playing hockey
 - Occasional PVC's
 - No ST changes

- Stress test:
 - Max HR = 192 BPM
 - No evidence of ischemia

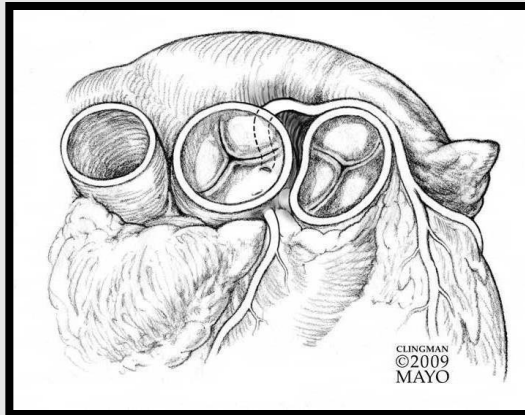


FACTS about Coronary Anomalies

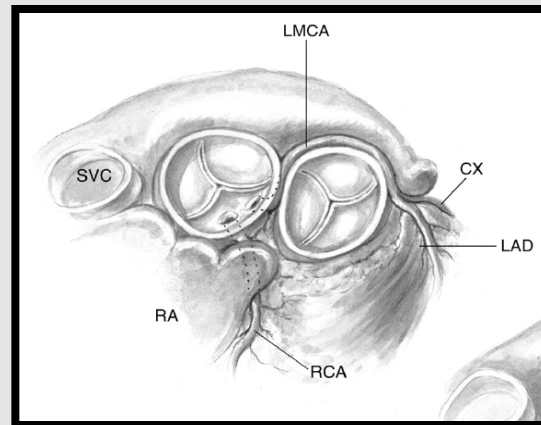
- Although majority of associated SCD occur during or shortly after exercise, SCD has been reported in the sedentary state
- Clinical symptoms, such as CP or DOE may be helpful, but up to 50% of SCDs are first events without prior symptoms
- ECG is an unreliable screening tool
- Stress tests are not uniformly positive: Dynamic obstruction
- Understanding the interplay between anatomic features and physiologic impact is important in making recommendations regarding management

Ectopic Coronary Artery Origin

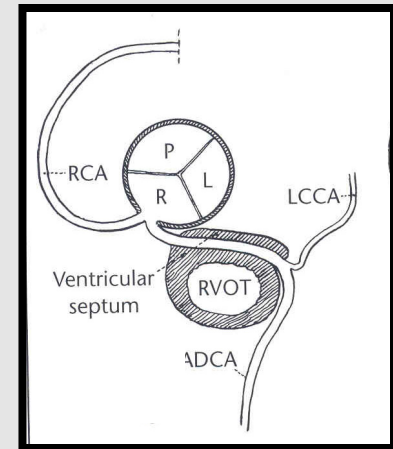
Intra-arterial course: Value of CTA



Intramural



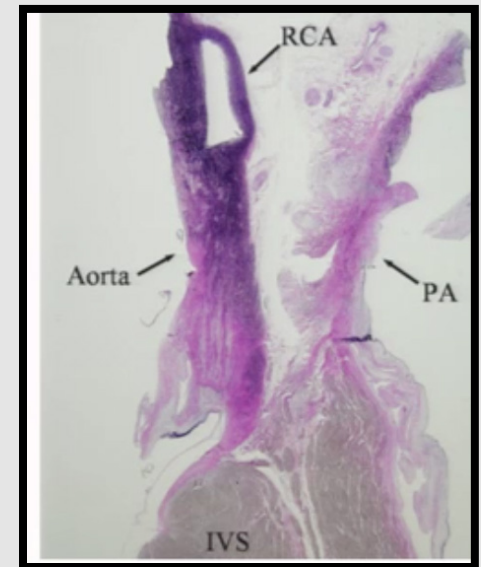
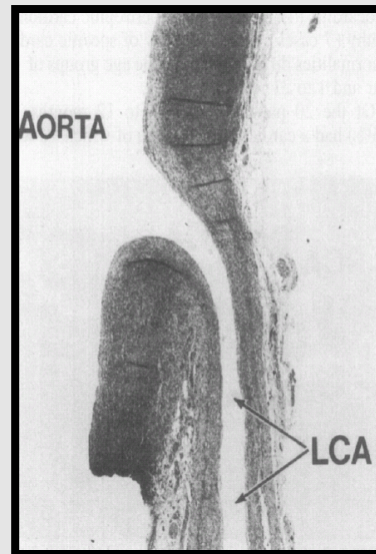
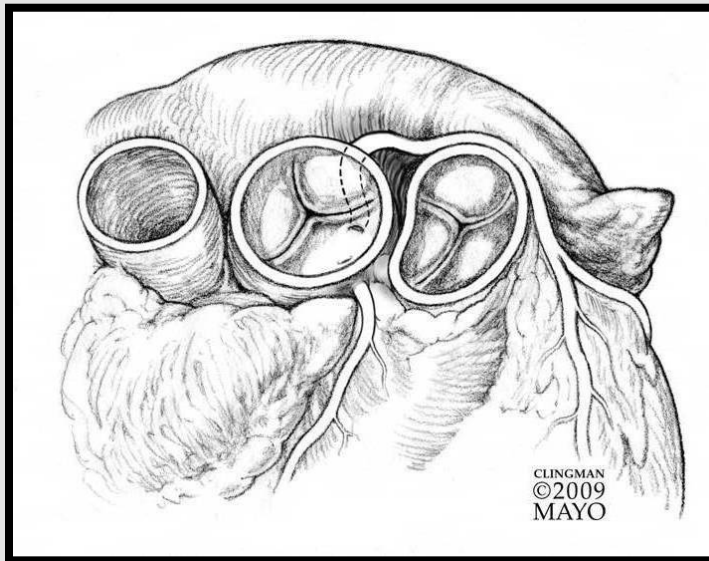
Extramural



Intramyocardial

Coronary Artery Anomalies

Intra-arterial Intramural course

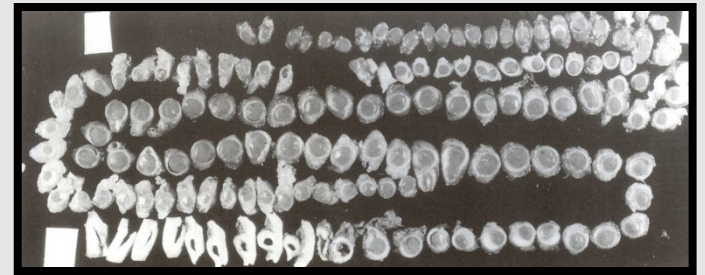


Exercise induced root expansion
with increased CO

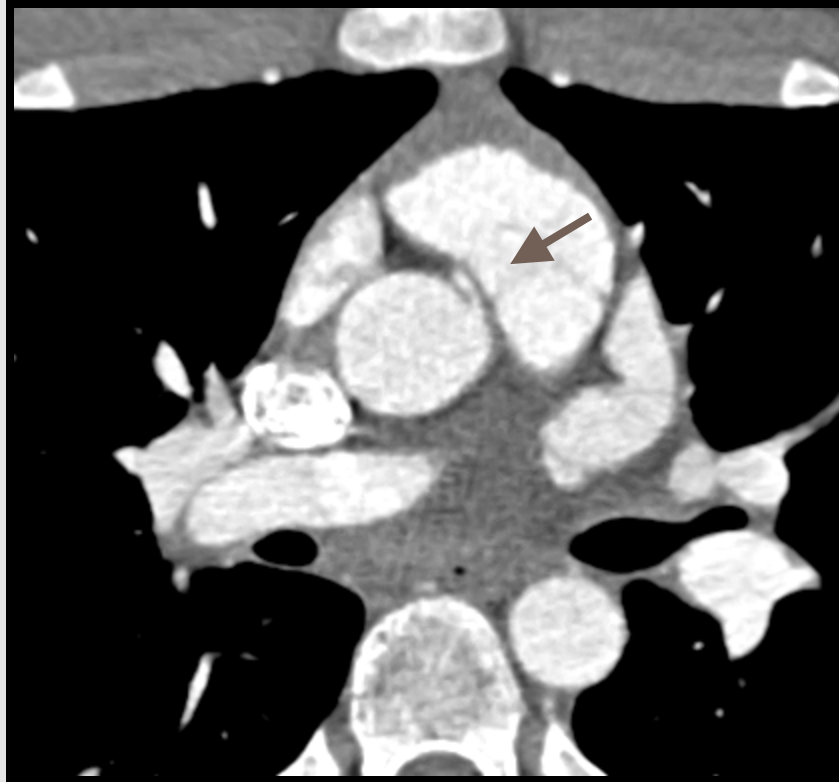
Value of CT Imaging

Questions for the radiologist if intraarterial course

1. Slit like opening?
2. Acute angle of take off?
3. Intramural vs. extramural vs. intramyocardial ?
4. Length of intramural or intramyocardial segment:
Symptomatic 8 ± 3 mm vs. 5 ± 1 mm Asymptomatic



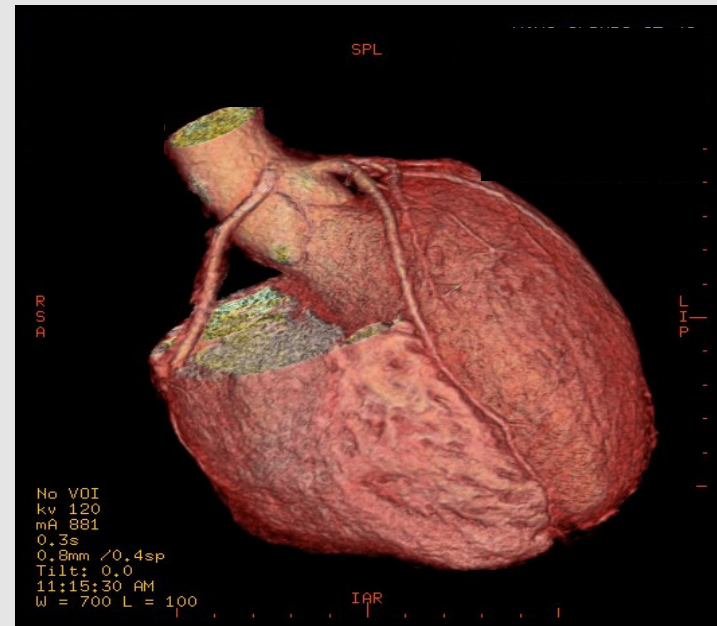The Hockey Player



Chest pain + intramural + slit like opening + acute angle takeoff

The Hockey Player

1. Observation
2. PC intervention
3. Surgical repair
4. More information

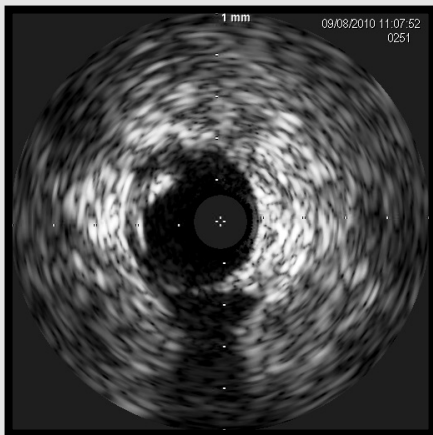


Stent in CA Anomalies

- 67 patients ARCA (Age 12 to 73 yrs, mean 48 ± 12)
 - CP (58), dyspnea (36), syncope (15), SCD (0)
 - All patients had IVUS: CSA 16-83%
- Stent placed in 42 patients for:
 - Significant symptoms, +ve EST, or involvement in strenuous exercise
 - CSA stenosis (rest $>50-55\%$, SAD $>60-65\%$)
- Resolution of intramural stenosis by IVUS in all
- Follow up at mean 29 months: Improved symptoms and no death
 - In- stent restenosis in 4 (13%)

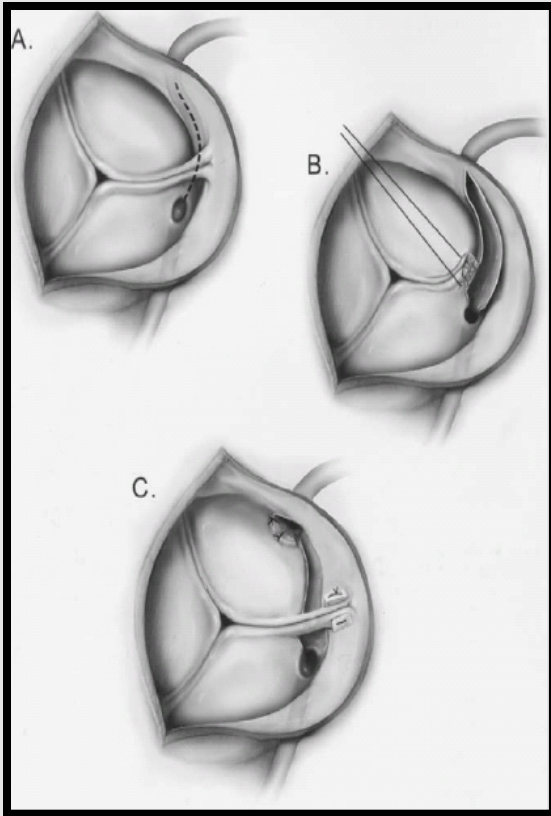
Value of IV Ultrasound

- Features correlating with clinical severity:
 1. Hypoplasia of intramural segment
 2. Lateral compression at rest and exercise
 - Area of stenosis >60%
 - Minimal diameter



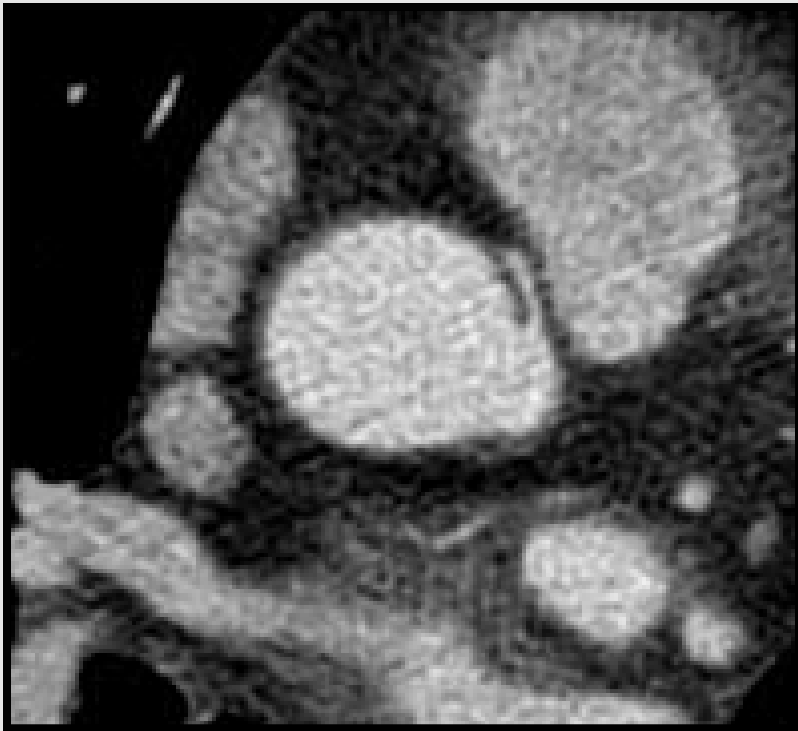
55 YO with anomalous RCA from Lt
Chest pain
Uncle died suddenly in 40s
Negative stress test

Ectopic Coronary Artery Origin Unroofing of Intramural ECA

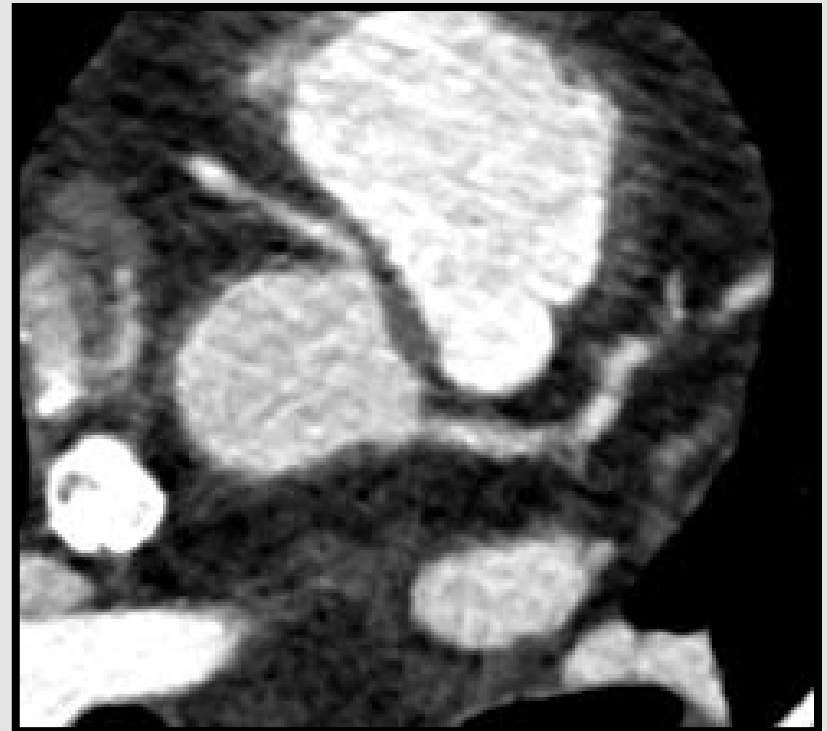


The Hockey Player

Unroofing of intramural ECA



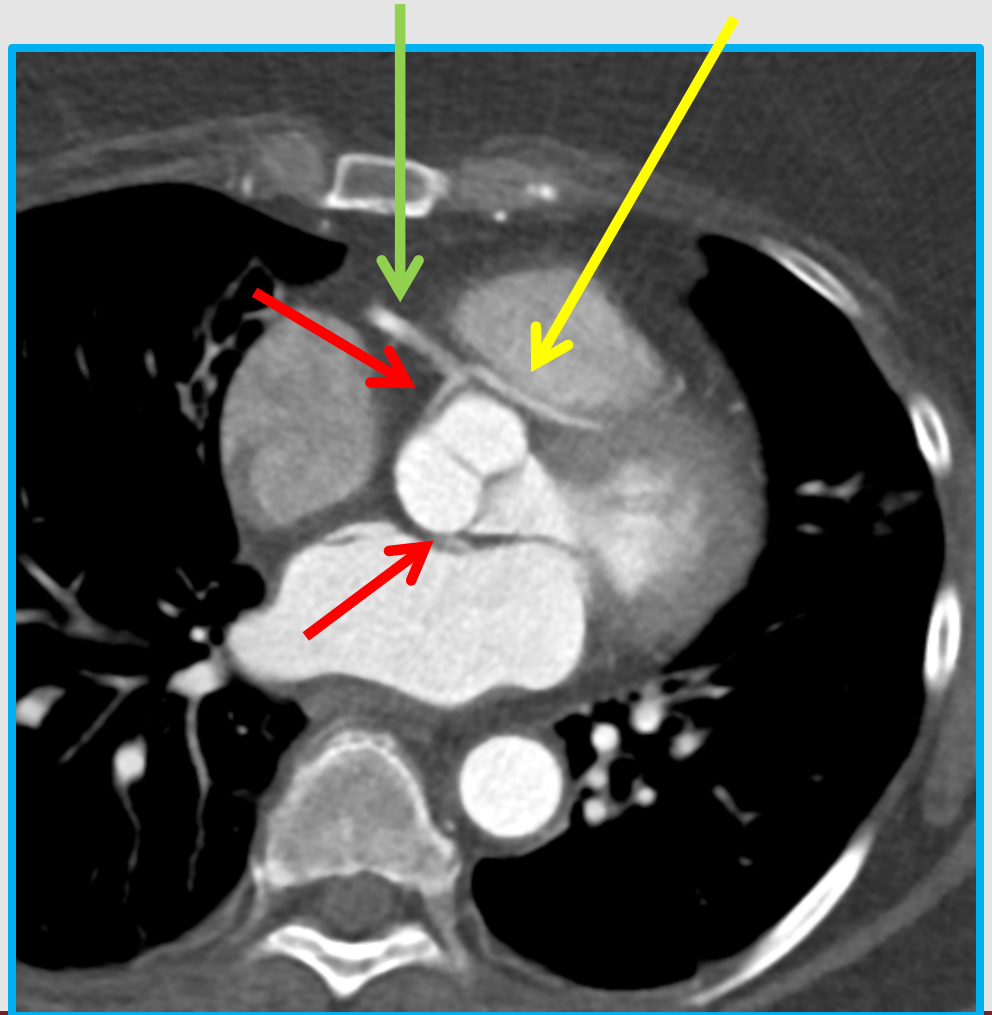
Preoperative



Postoperative

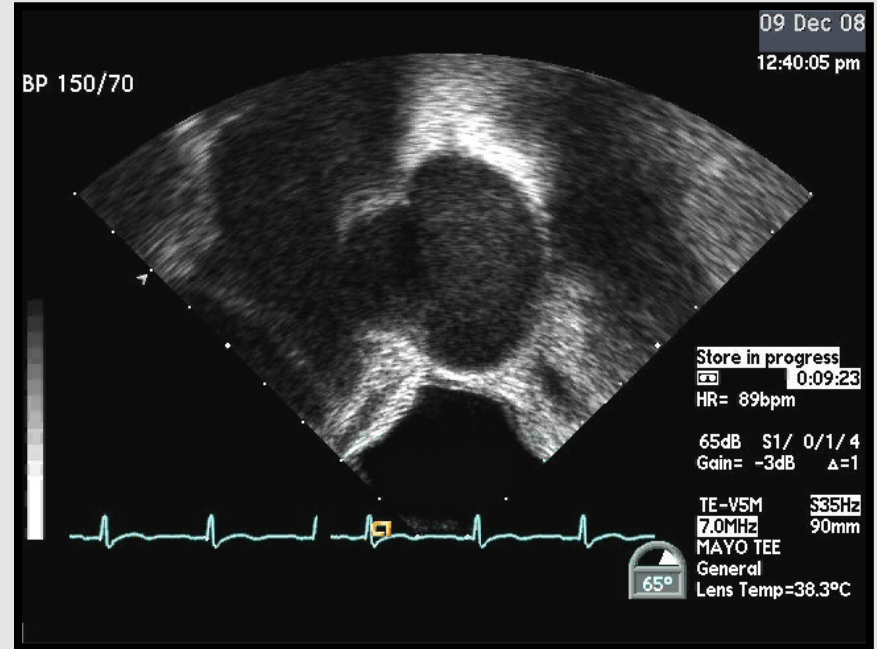
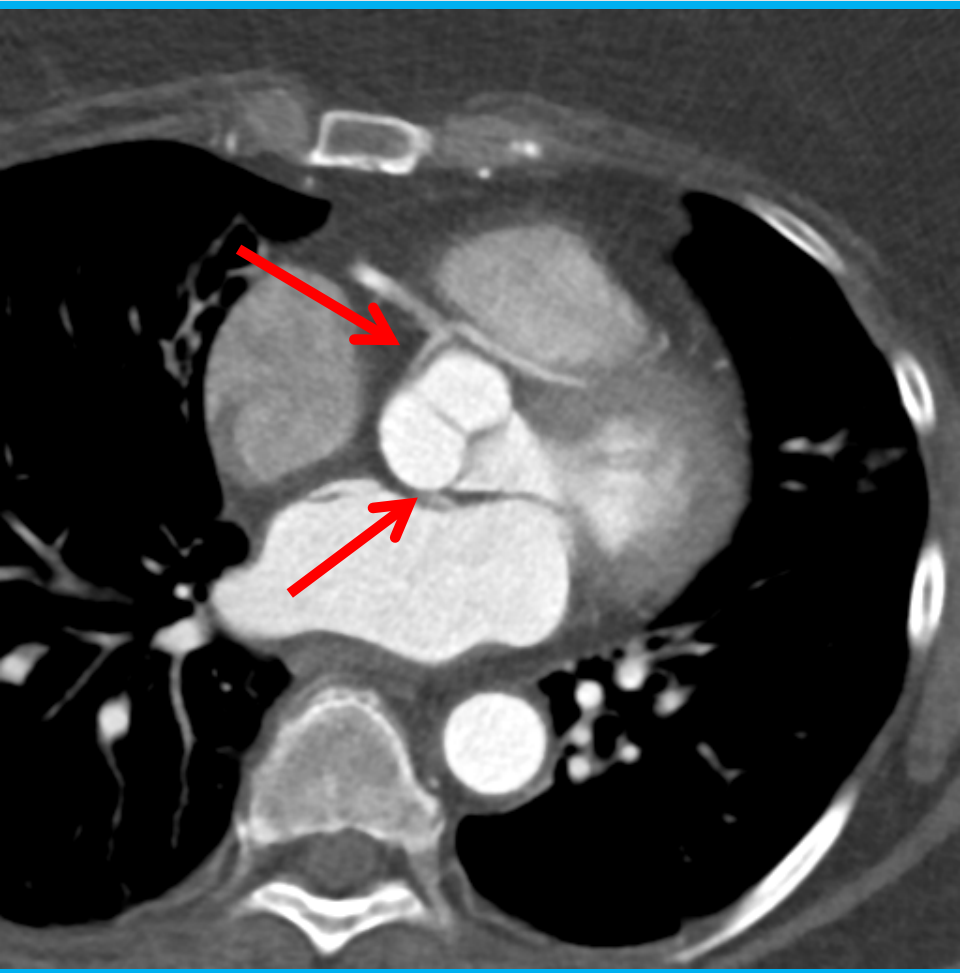
The Concerned Spouse

1. Observation
2. PC intervention
3. Surgical repair
4. More information



Coronary Artery Anomalies

Retro-aortic course



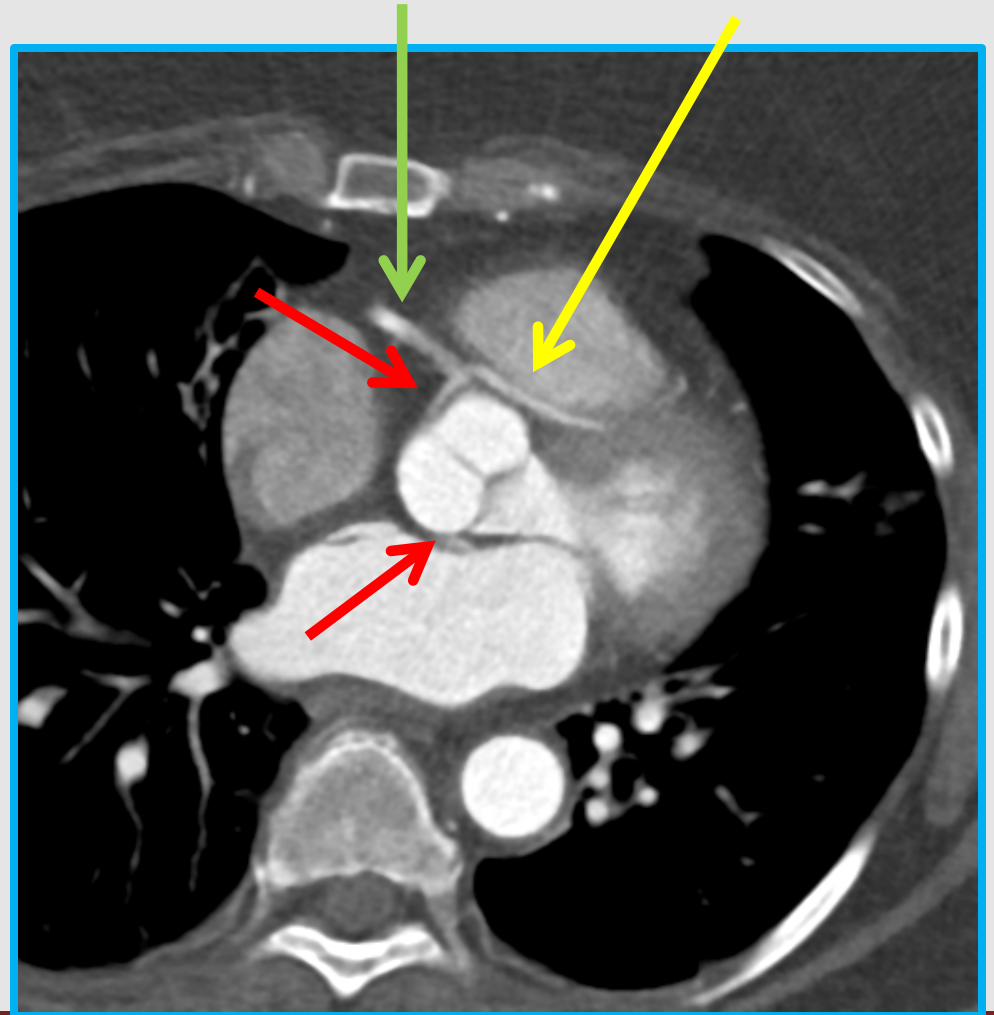
Post PFO/ASD closure
Post AVR + MVR
Post TAVR

The Concerned Spouse

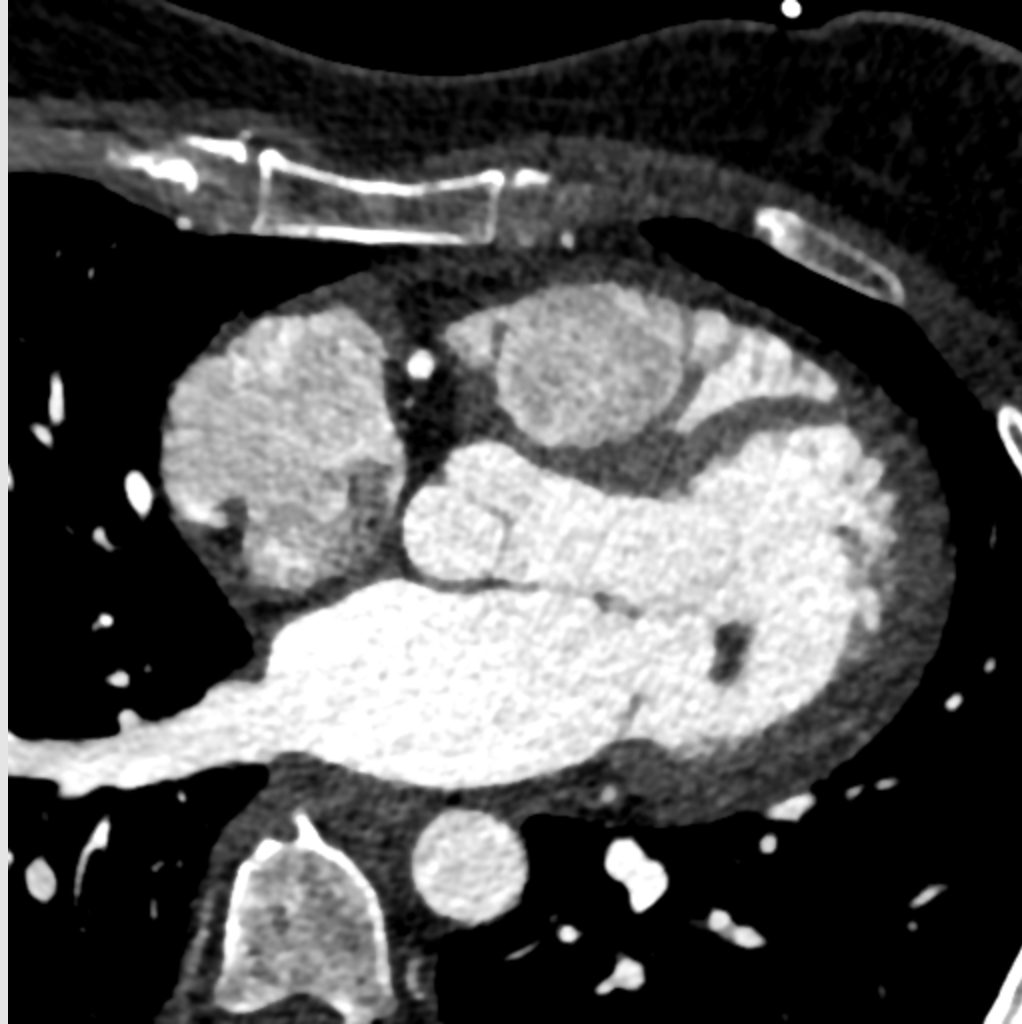- 69 yrs. old lady with jaw pain/ atypical rest CP
- Coronary CT: No intramural segments
- EST: 5:32 min, PHR 133 (88%), 7.1 mets, no CP
1mm horizontal ST↓ Inf-lat at 5 mins, gone 1 min post
- Cardiolute: 6:12 min, PHR 139 BPM
no ST changes , no CP/ arrhythmias
normal myocardial perfusion, EF 70%
- Holter 48 hrs: 36 PACs, 5 PVCs, NSR with Jaw pain

The Concerned Spouse

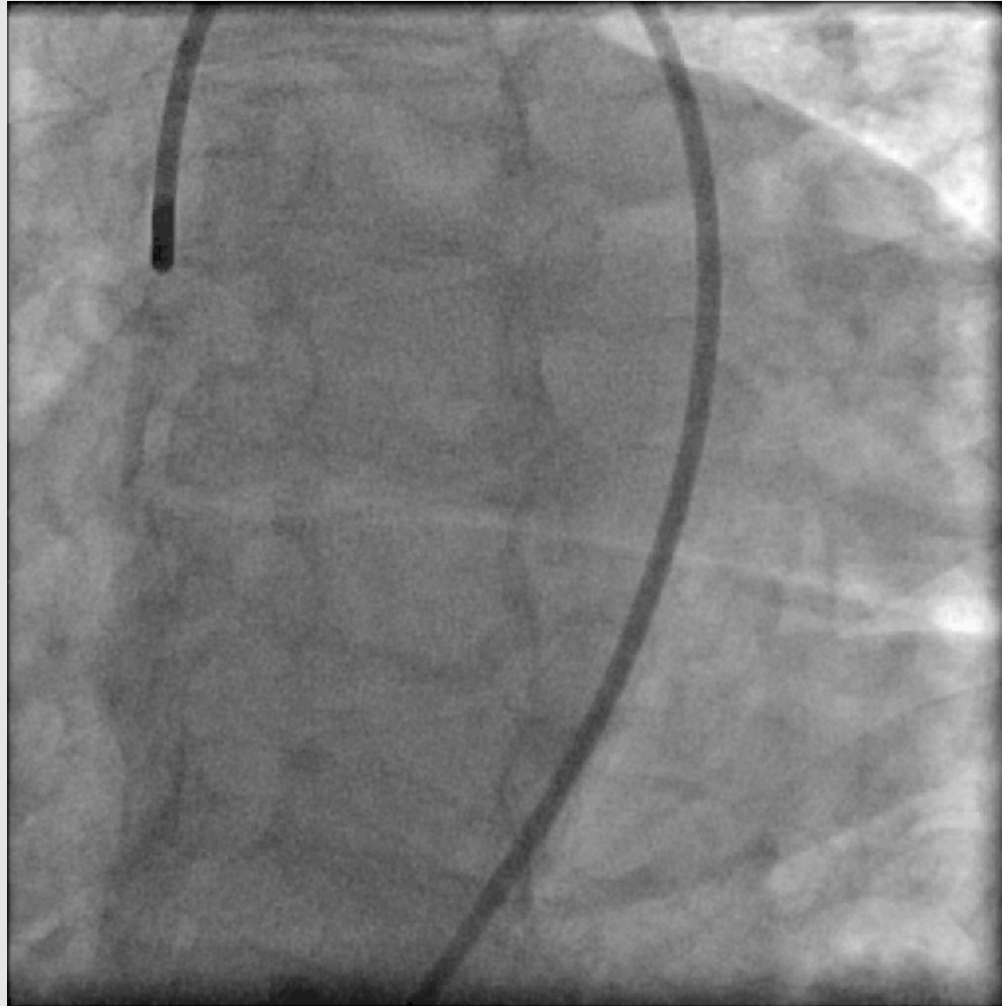1. Observation
2. Surgical repair
3. Metoprolol XL +
avoid strenuous
exercise



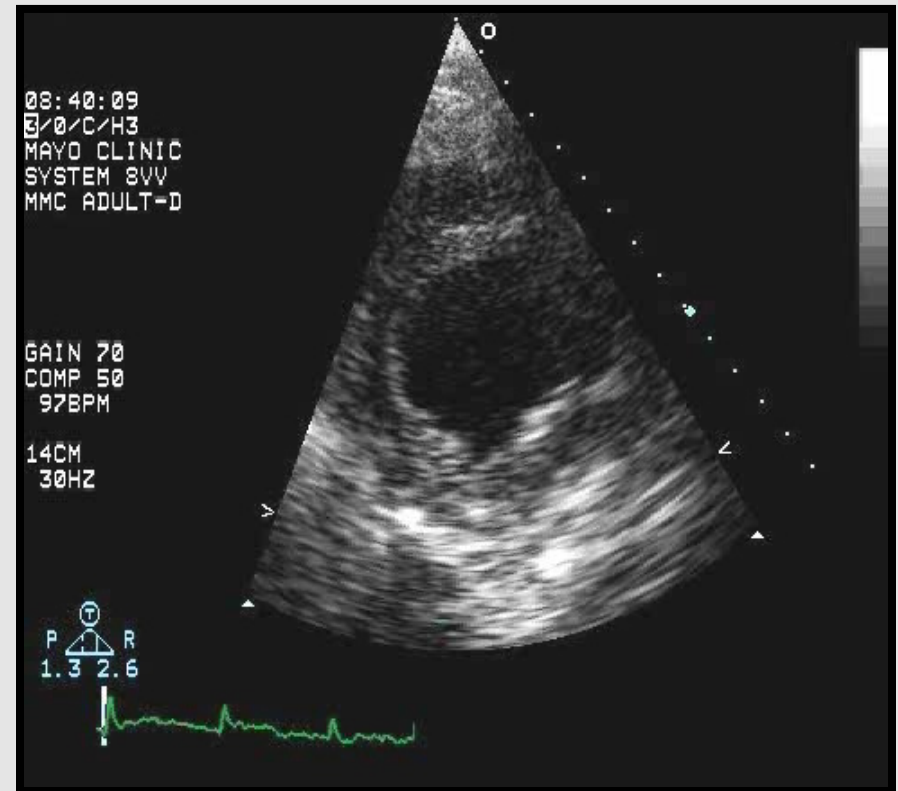
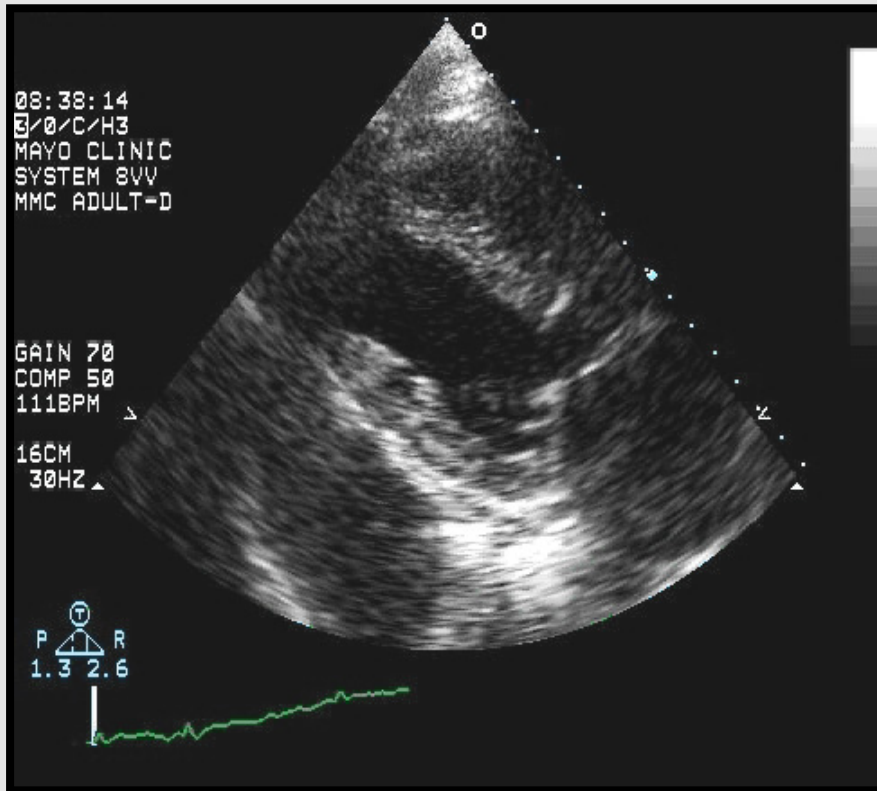
50 YO lady with Chest Pain



50 YO lady with Chest Pain

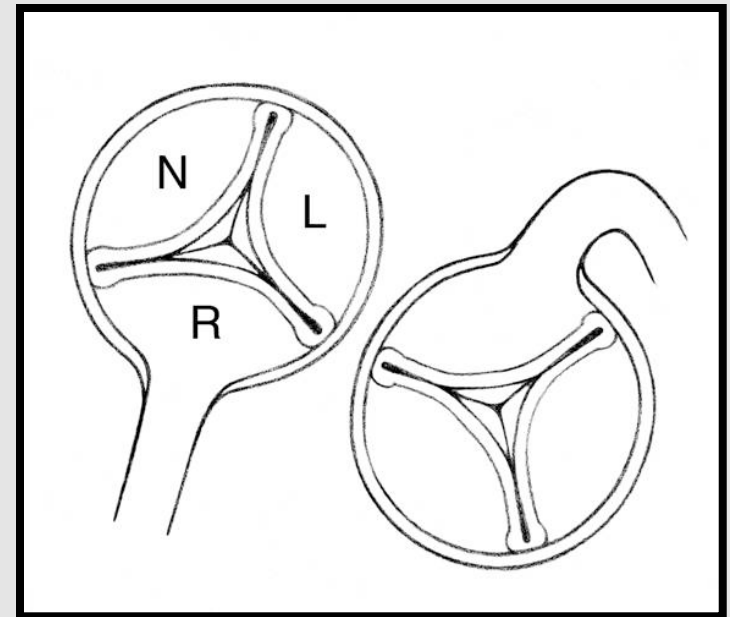
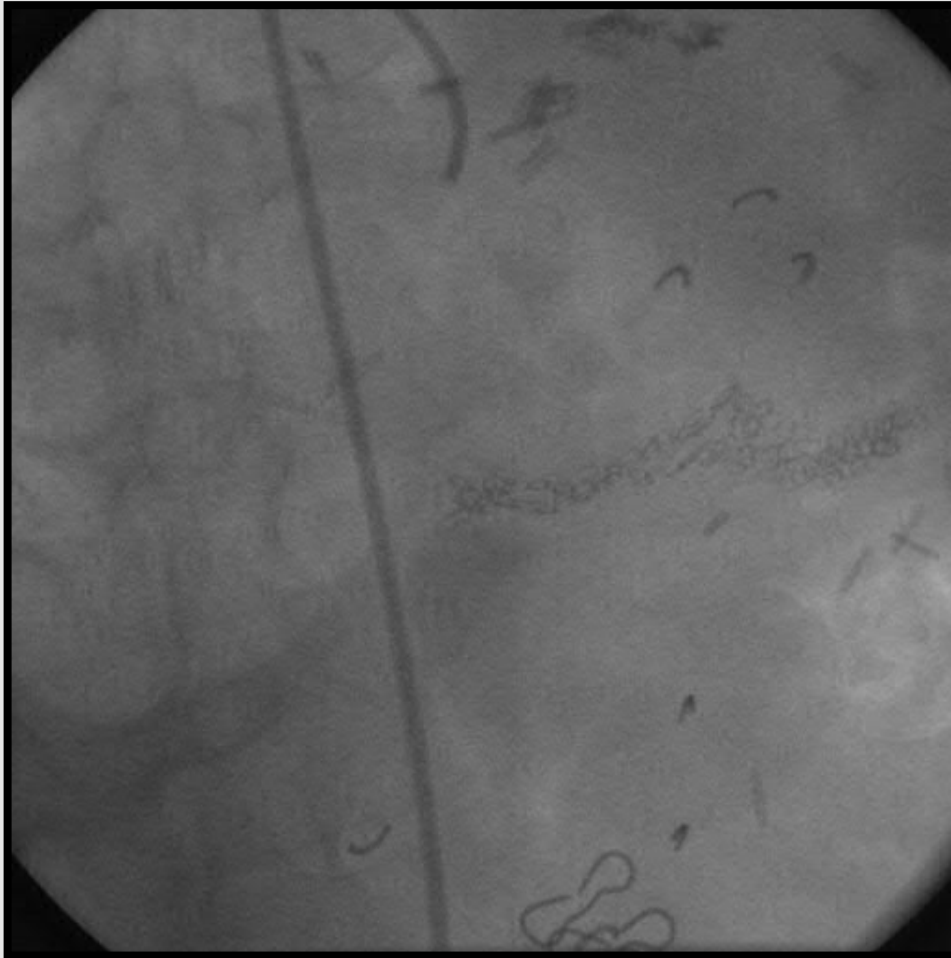


66 YO with chest pain and dyspnea

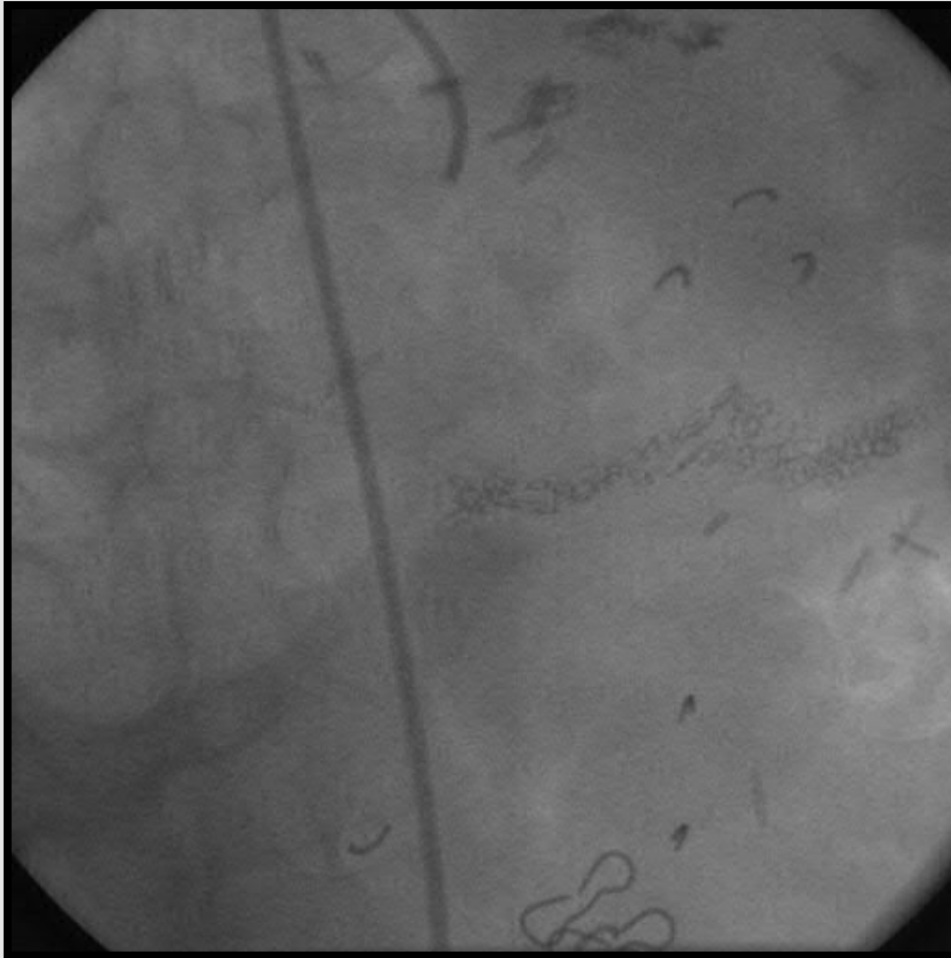


8/1/2005

65 YO with chest pain and dyspnea



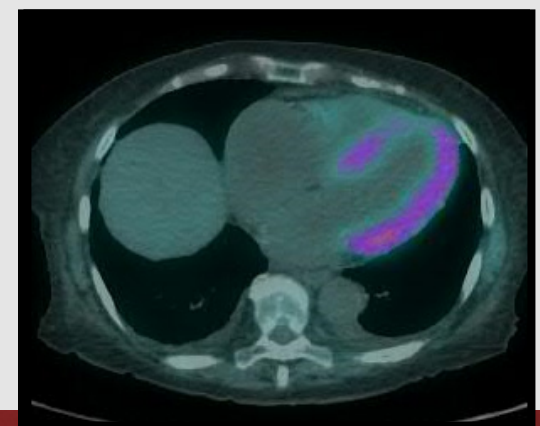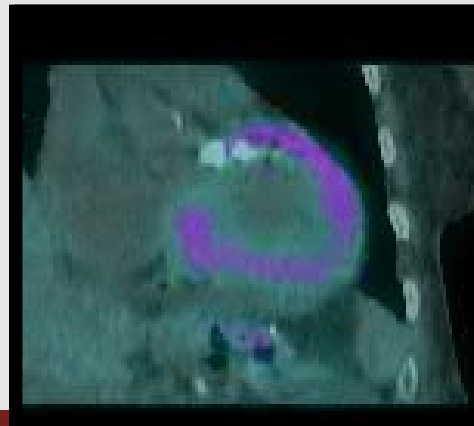
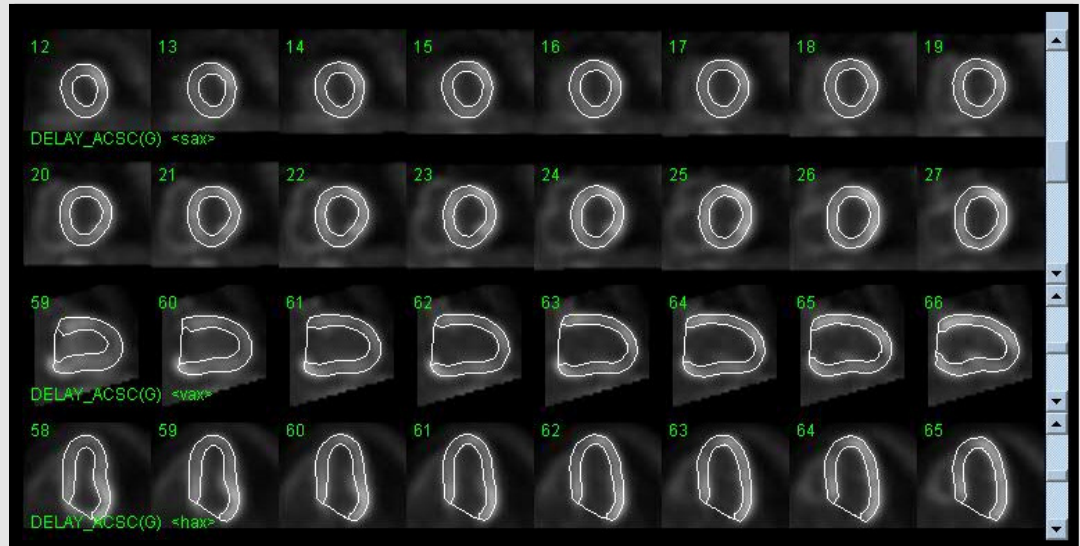
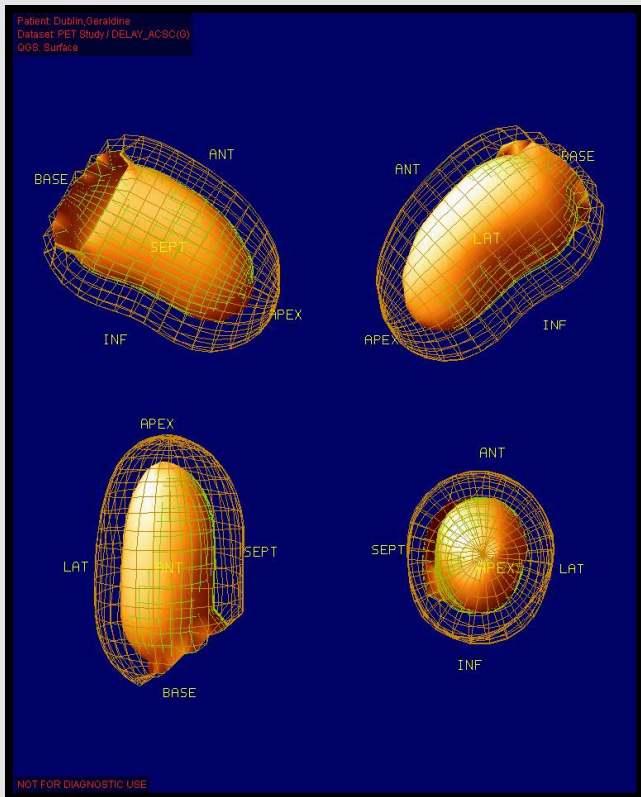
65 YO with chest pain and dyspnea



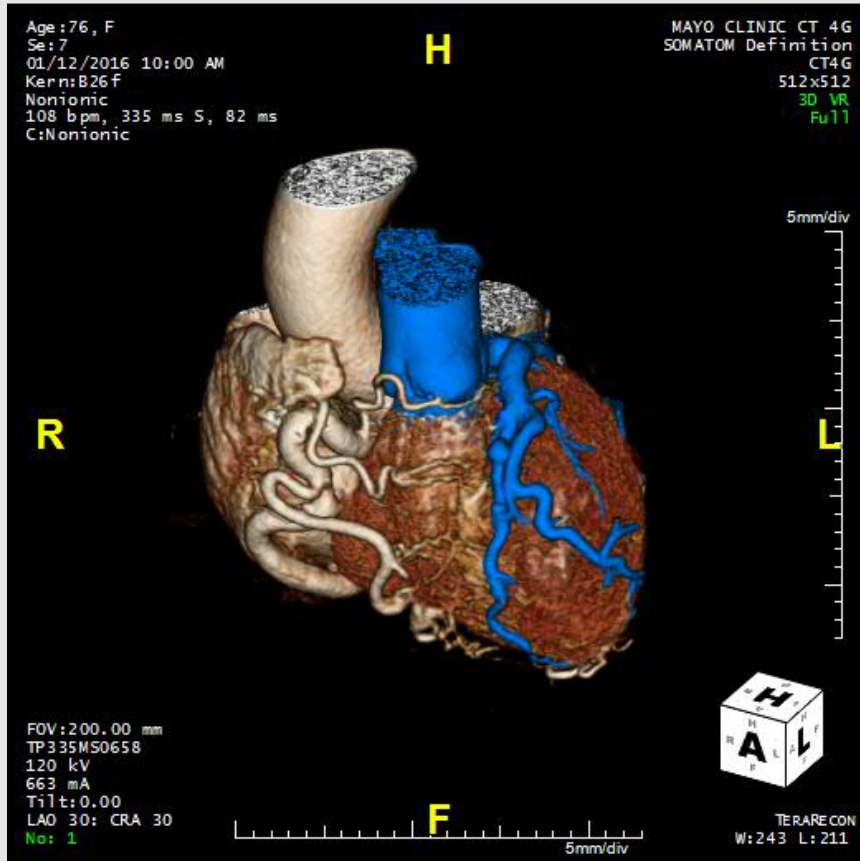
ALCAPA on Coronary angiography

- **Dilated RCA**
- **Large collaterals-filling of LCA and passage of contrast material to MPA**

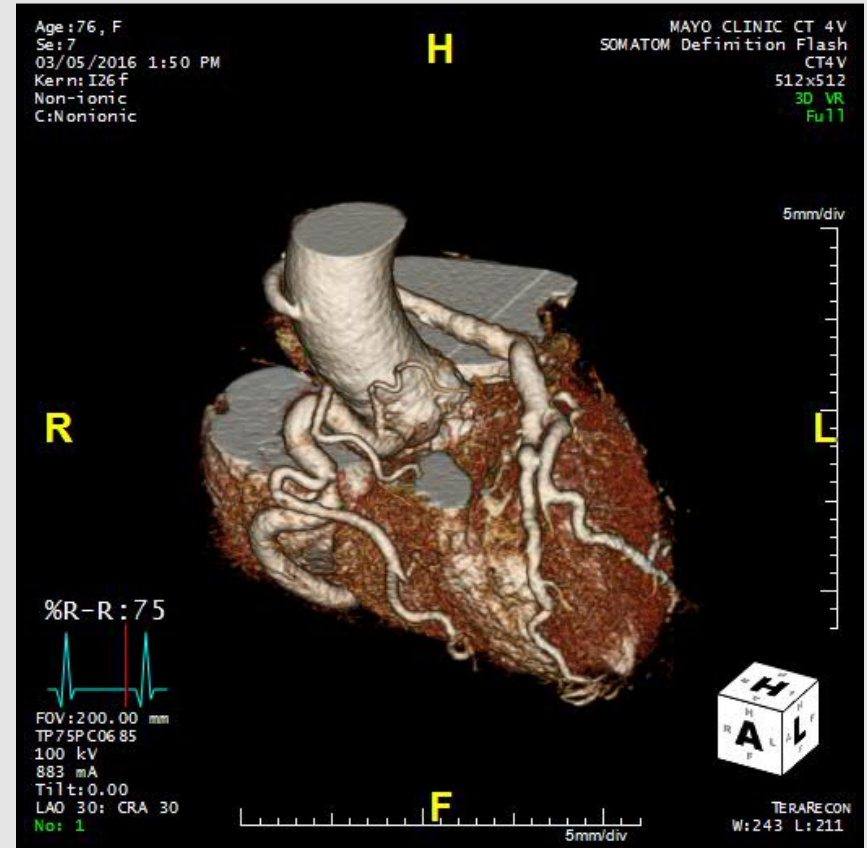
11 year later: 76 YO with CP and HF Pet-CT scan



76 YO ALCAPA with CP and HF



Preoperative

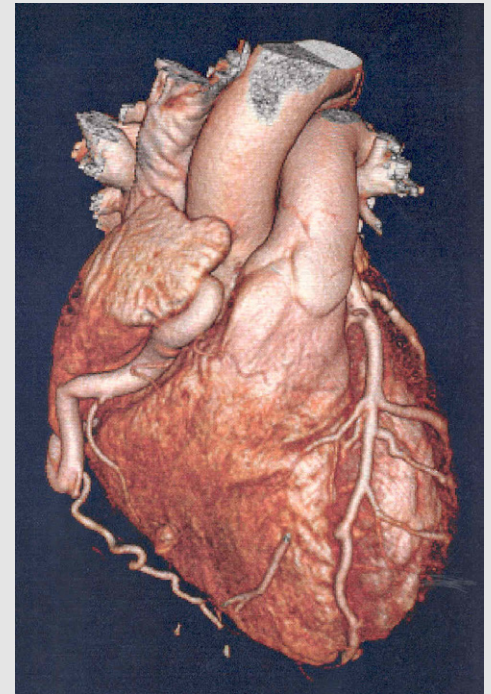


Postoperative

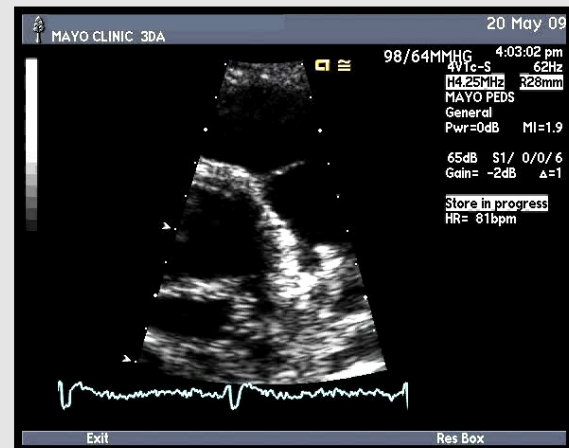
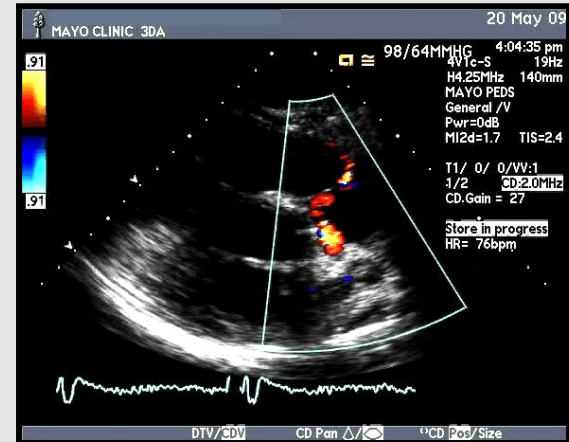
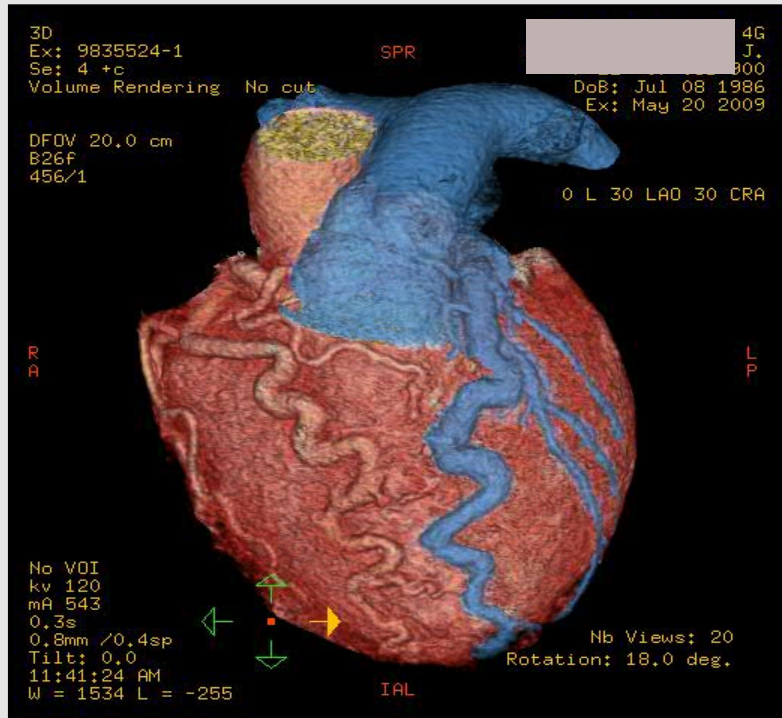
Coronary Artery Anomalies

ALCAPA

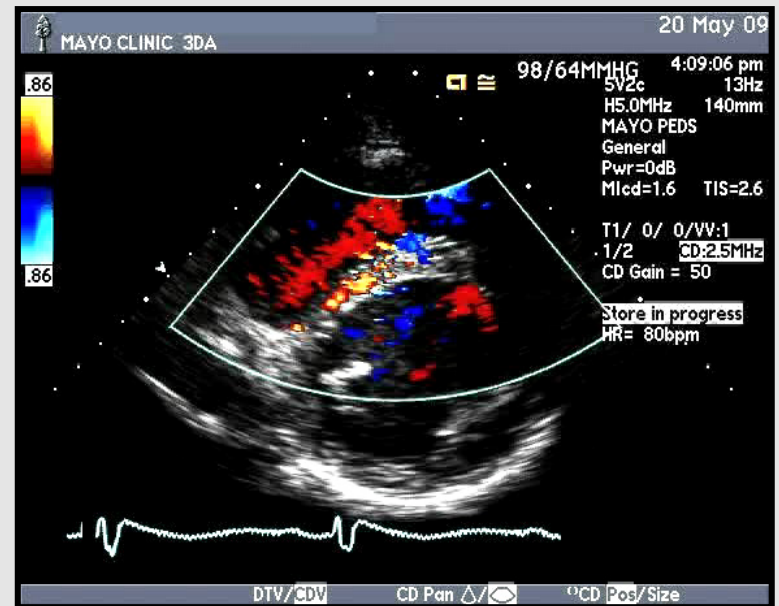
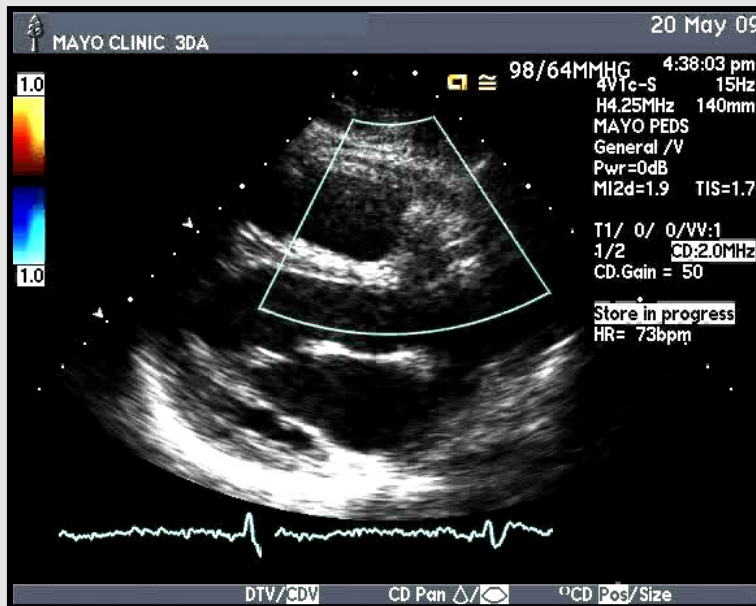
- Survival into adulthood in 10-15%
 - Average age at presentation 41 yrs
 - oldest report: 83 yrs
- Presentation:
 - No symptoms in up to 20%
 - Angina, ischemia, abn. EKG
 - LV dysfunction, Mitral regurgitation
 - VT, CHB or SCD



The College Graduate 22 YO with DOE



The College Graduate 22 YO with DOE



Ectopic CA Origin from Opposing Sinus

Which Ones Needs Treatment

1. **Anomalous Lt CA**: consider repair after Shared Decision Making
2. **Anomalous Rt CA** : selective – age (<35), Holter, EST, Echo, CTA, IVUS

Consider repair: Angina, syncope, ischemia, arrhythmia or ↓ LVEF

Asymptomatic with intramural segment:

Alternate recommendations especially in the elderly:

1. Avoidance of strenuous physical activity
2. Abstinance from competitive athletics
3. Possible role for β blockers

Anatomic Variants of Coronary Arteries

Take Home Message

1. Most CA anomalies are benign except for some with ectopic origin
2. Understanding their anatomic/ pathophysiological sequelae is key to management:
 - Value of echo, stress test, CT and IVUS
3. Percutaneous or Surgical treatment available in the selected patient needing intervention

Thank You!

Ammash.naser@mayo.edu



Eligibility and Disqualification Recommendations for Competitive Athletes With Congenital Heart Disease

- Anomalous origin of a CA from PA can participate only in low-intensity class IA sports, whether or not they have had a prior myocardial infarction, and pending repair of the anomaly (*Class I; LOE C*).
- Anomalous RCA from the left SOV should have exercise stress test. For those without either symptoms or a positive exercise stress test, permission to compete can be considered after adequate counseling of the athlete and/or the athlete's parents (uncertainty of accuracy of a negative stress test (*Class IIa; LOE C*)).

Eligibility and Disqualification Recommendations for Competitive Athletes With Congenital Heart Disease

- An anomalous origin of RCA from the left SOV who exhibit symptoms, arrhythmias, or signs of ischemia on exercise stress test should be restricted from participation in all competitive sports, with the possible exception of class IA sports, before a surgical repair (*Class III; LOE C*)
- Anomalous origin of LCA from the right SOV should be restricted from participation in all competitive sports, with the possible exception of class IA sports, before surgical repair (*Class III; LOE B*)