

Arrhythmogenic RV Cardiomyopathy

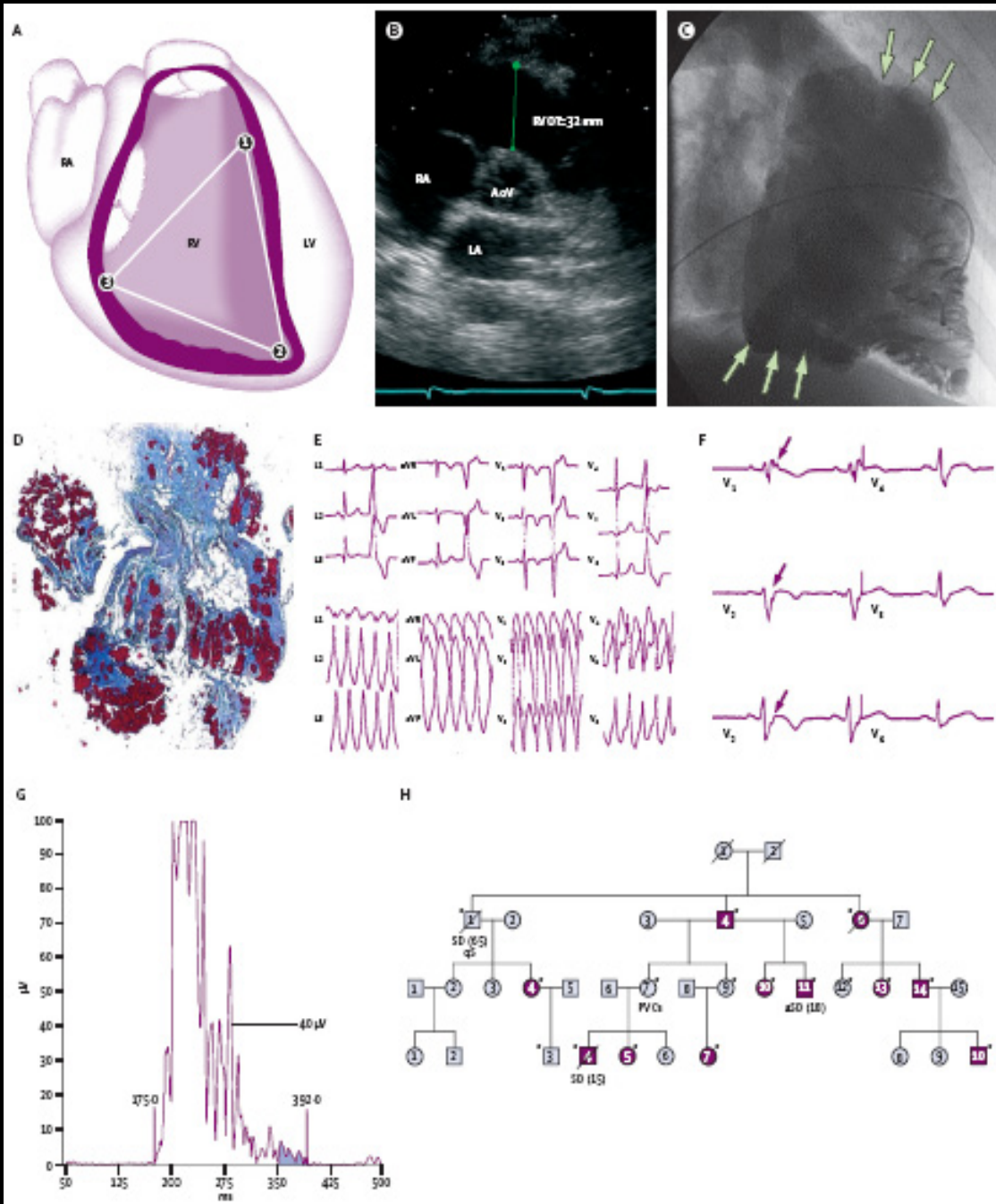
(A non Arrhythmologic Perspective)

Claudio Rapezzi, Bologna

Arrhythmogenic RV Cardiomyopathy (a non-arrhythmologic perspective)

Agenda:

- **Diagnostic pitfalls, mimics and phenocopies**
- **Role of molecular genetic**
- **Role of MRI**
- **ARVC as a cause of HF**
- **From right-side to left-side**
- **Commendation of the standard ECG**



Basso C et al, Lancet 2009

Disease-Causing Mutations in Desmosomal Proteins

**Mechanical and electrical uncoupling at
desmosomial level :**

Cell death

Fibrosis

Monomorphic arrhythmias

Sodium channel dysfunction

Activation delay

Deleterious effect of exercise

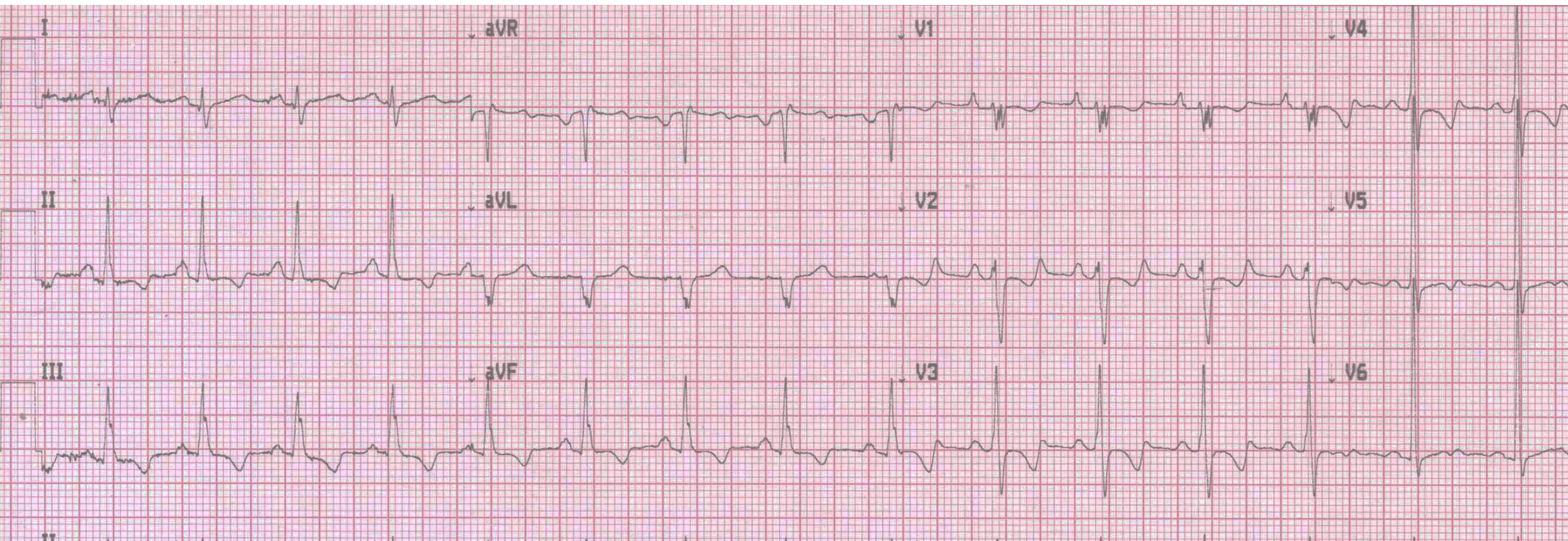
Progression by acute bursts

Male, 26 ys

Cardiac history: unremarkable

Family history negative for cardiomyopathy or SD

Pre-participation sport screening: RV dilatation and dysfunction → CMR in a peripheral centre with preliminary diagnosis of ARVC



24 h Holter: 55 VPBs (LBBB)

S5-1/Adulti

S5-1/Adulti

FR 49Hz
16cm

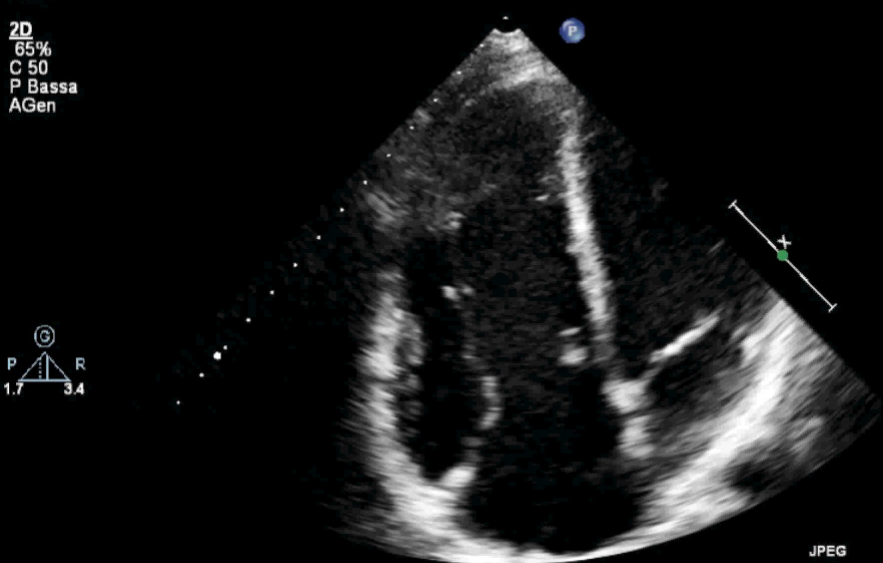
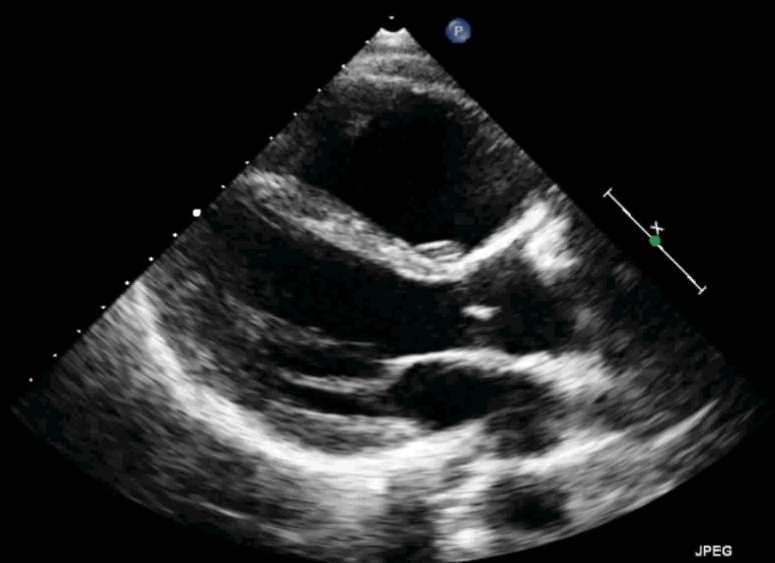
M3

FR 50Hz
15cm

M3

2D
75%
C 50
P Bassa
AGen

2D
65%
C 50
P Bassa
AGen



JPEG

48 bpm

JPEG

43 bpm

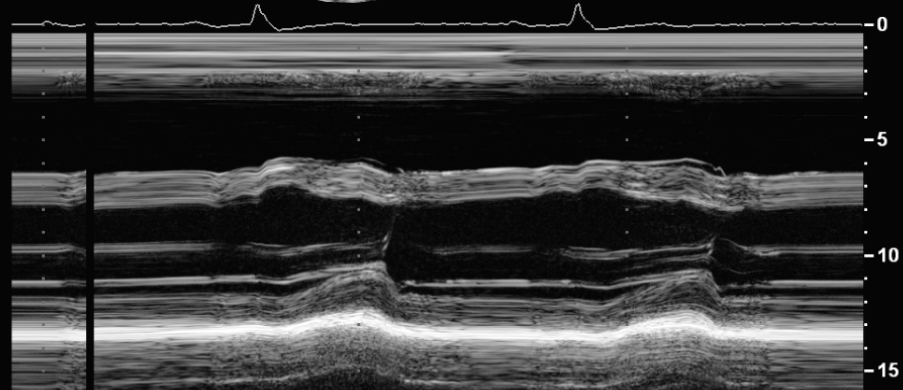
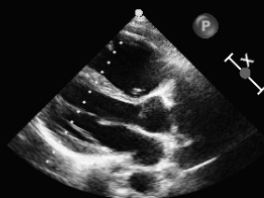
IST CARDIOLOGIA BO

S5-1/Adulti

FR 25Hz
16cm

M3

2D/MM
75% 71%
C 50
P Bassa
AGen



75mm/s

46bpm

RM Cuore

Ventricolo sinistro di normali dimensioni (EDV) e spessori parietali. Non alterazioni della cinetica loco-regionale; funzione sistolica globale ai limiti inferiori della norma.

Ventricolo destro con diametri aumentati e volumi ai limiti superiori della norma con lieve accentuazione della banda moderatrice.

Ipcinesia globale del ventricolo destro, maggiormente accentuata a carico dell'apice, con FE globale ai limiti inferiori della norma.

Lieve dilatazione del tratto di efflusso del ventricolo destro (RVOT 28 mm) con cinetica normale.

Atrio destro ed atrio sinistro di dimensioni ai limiti superiori della norma.

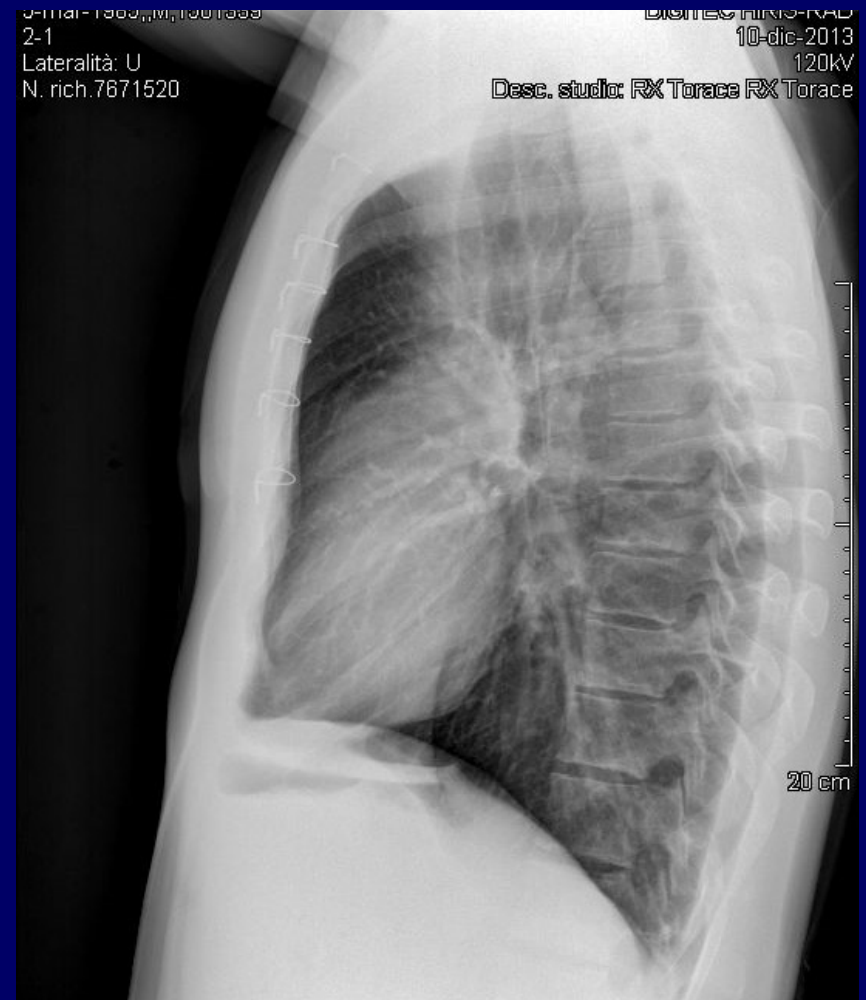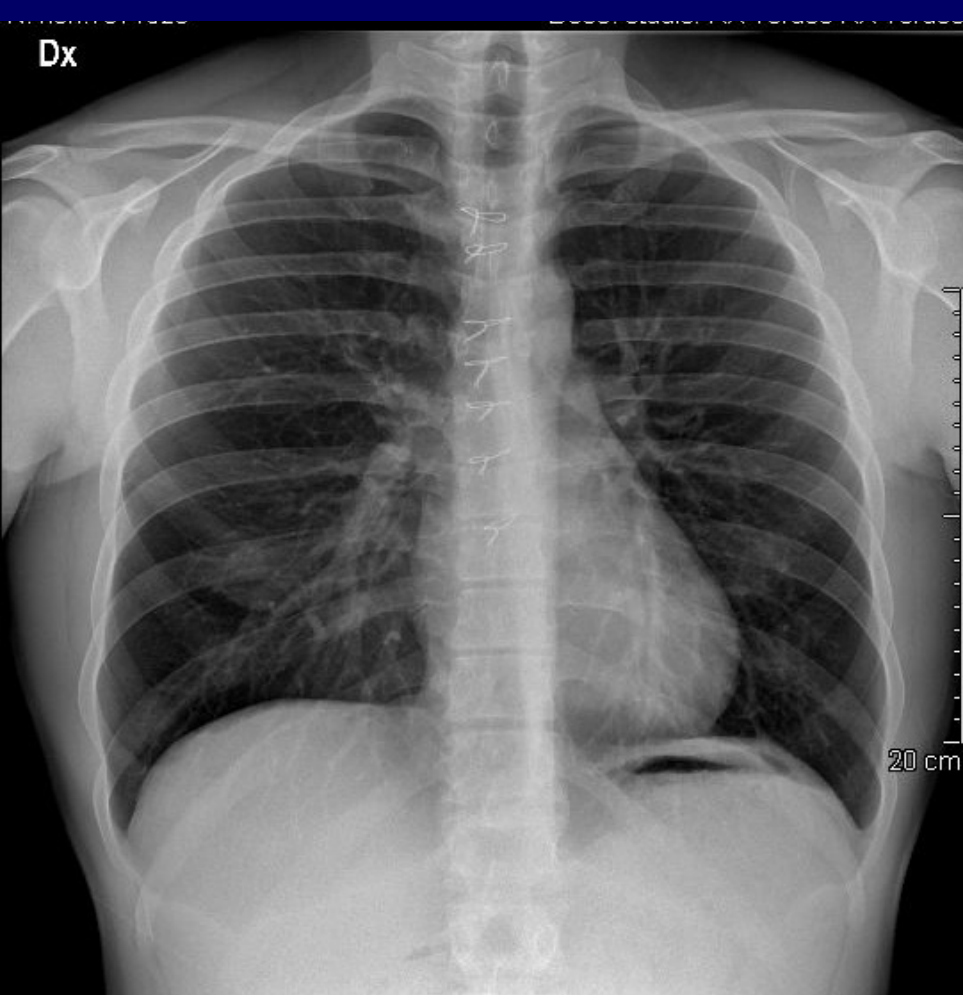
L'indagine non ha evidenziato segni di infiltrazione adiposa intramiocardica.

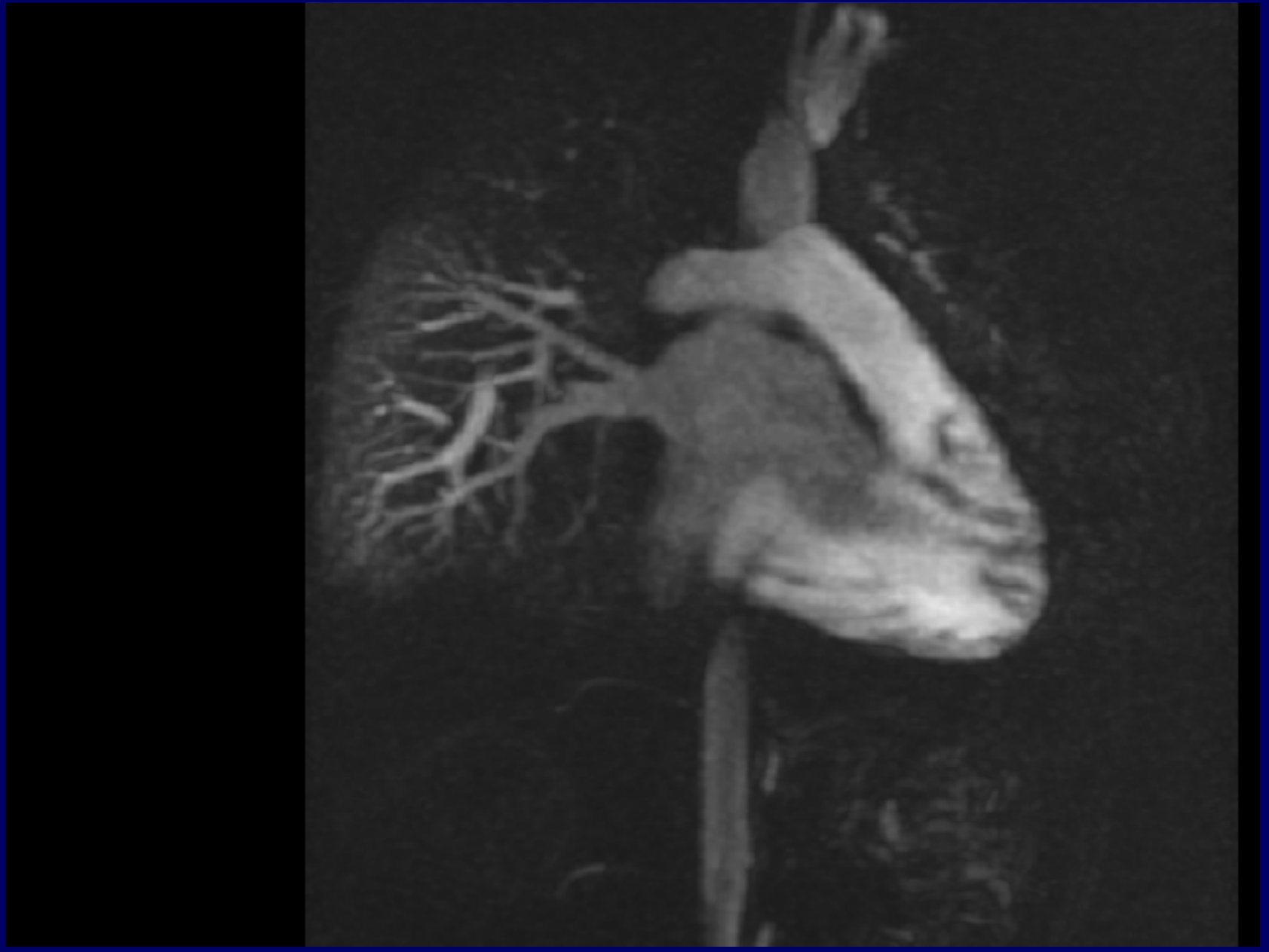
Non deficit di perfusione allo studio di primo passaggio a riposo.

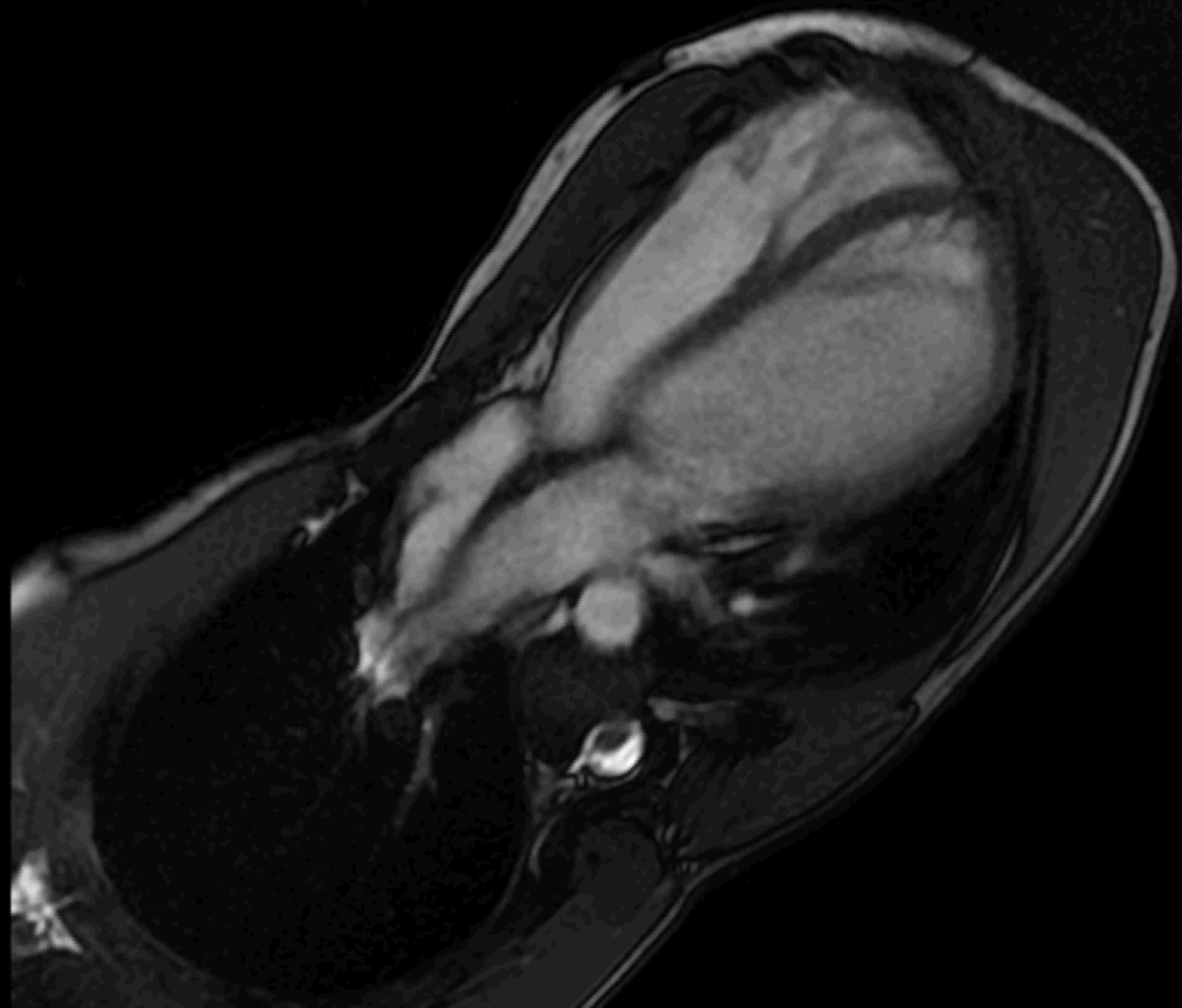
Non apprezzabili aree di ritardato wash-out di mdc indicative di danno interstiziale\ miocellulare.

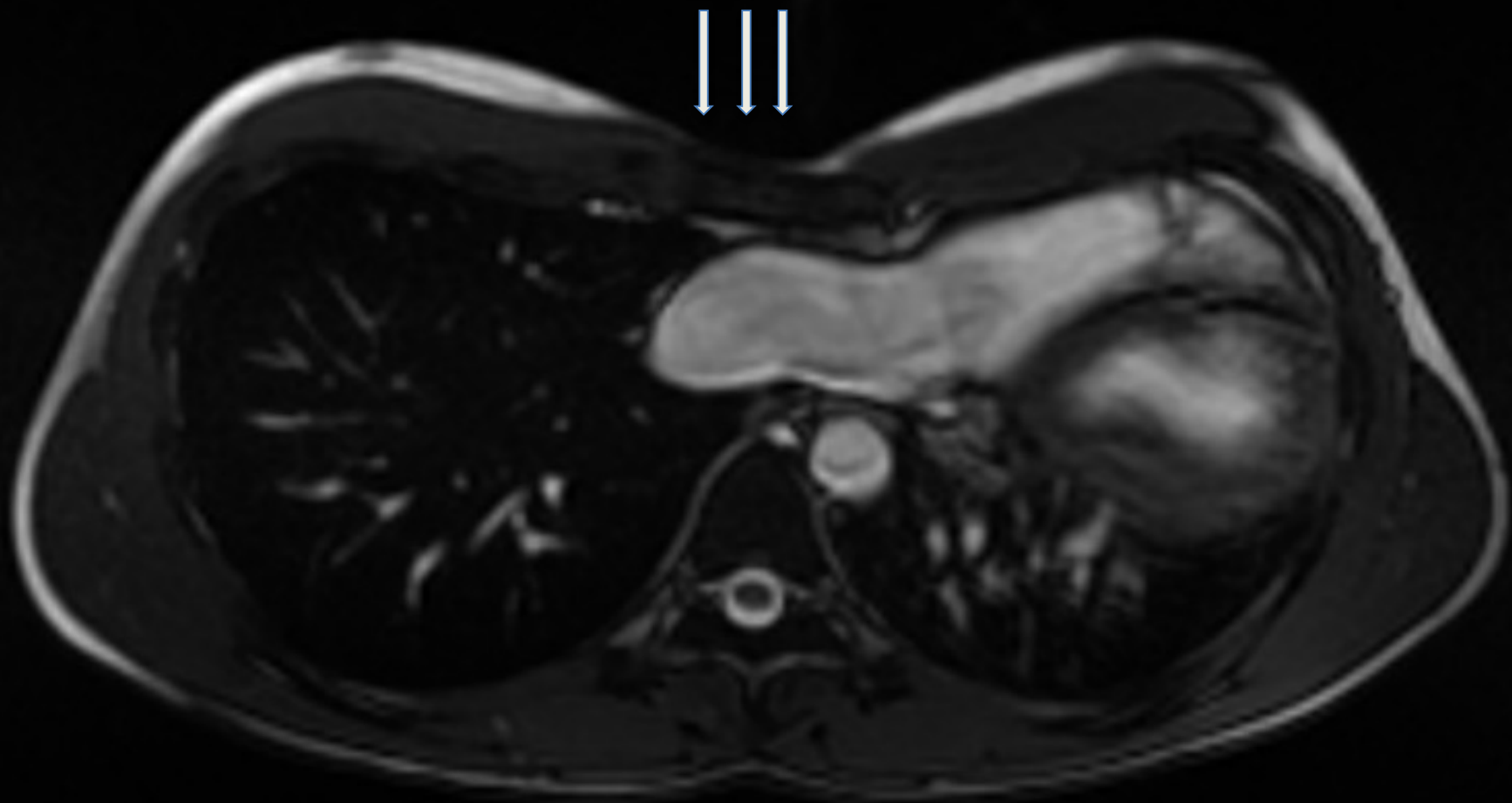
Conc.: l'indagine RM è compatibile con iniziale cardiomiopia aritmogena del ventricolo destro, soddisfacendo 2 tra i criteri minori secondo gli ultimi aggiornamenti. Si consiglia controllo RM a circa 2 anni se le condizioni cliniche rimangono invariate.

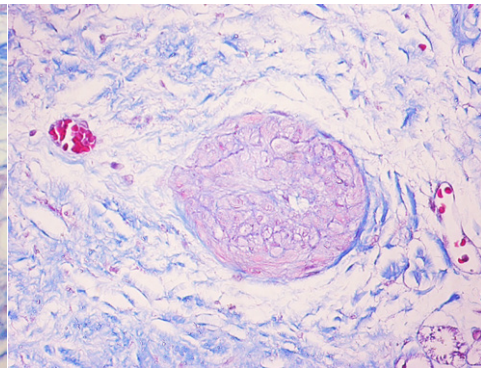
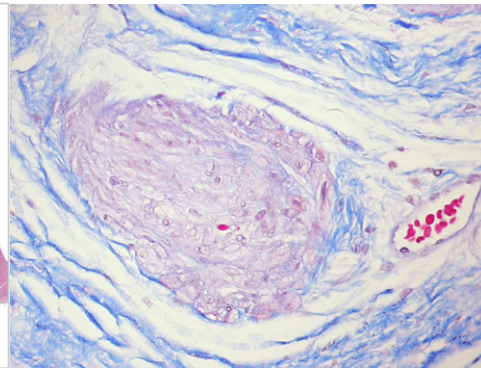
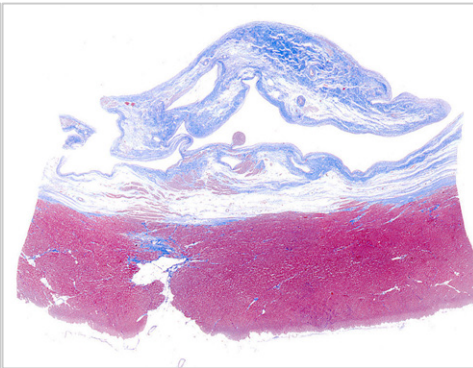
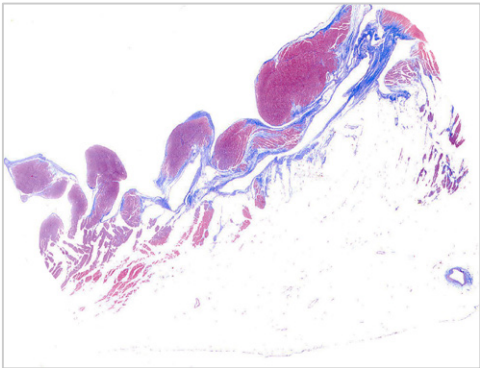
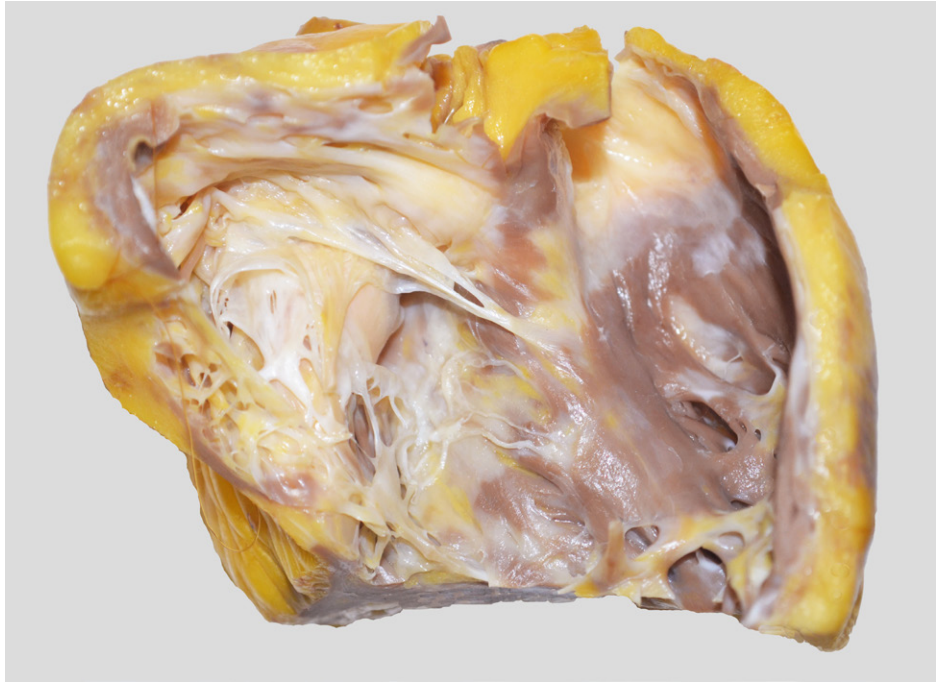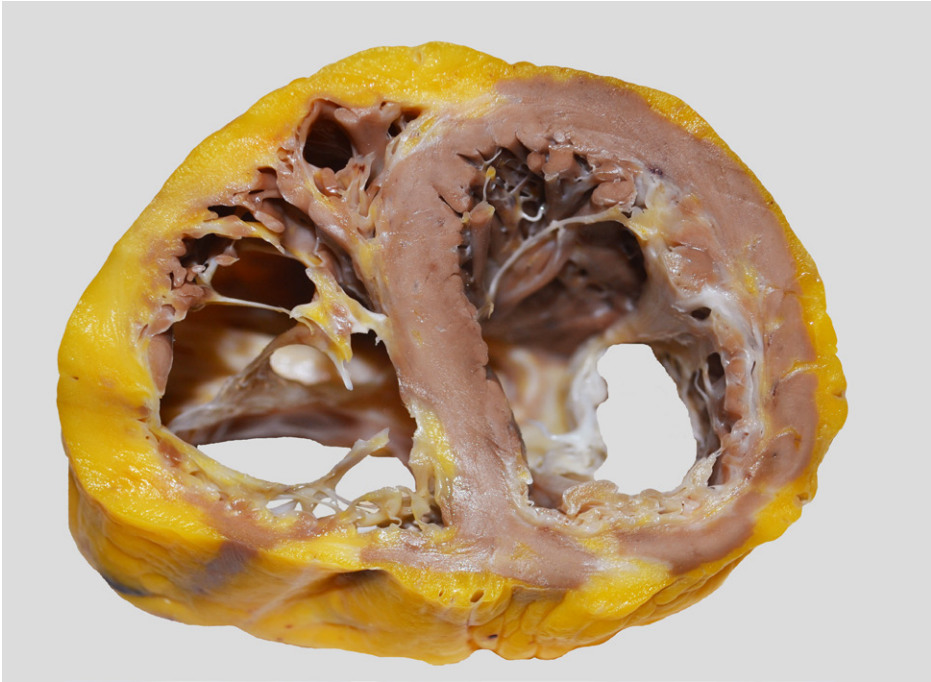
Rx torace







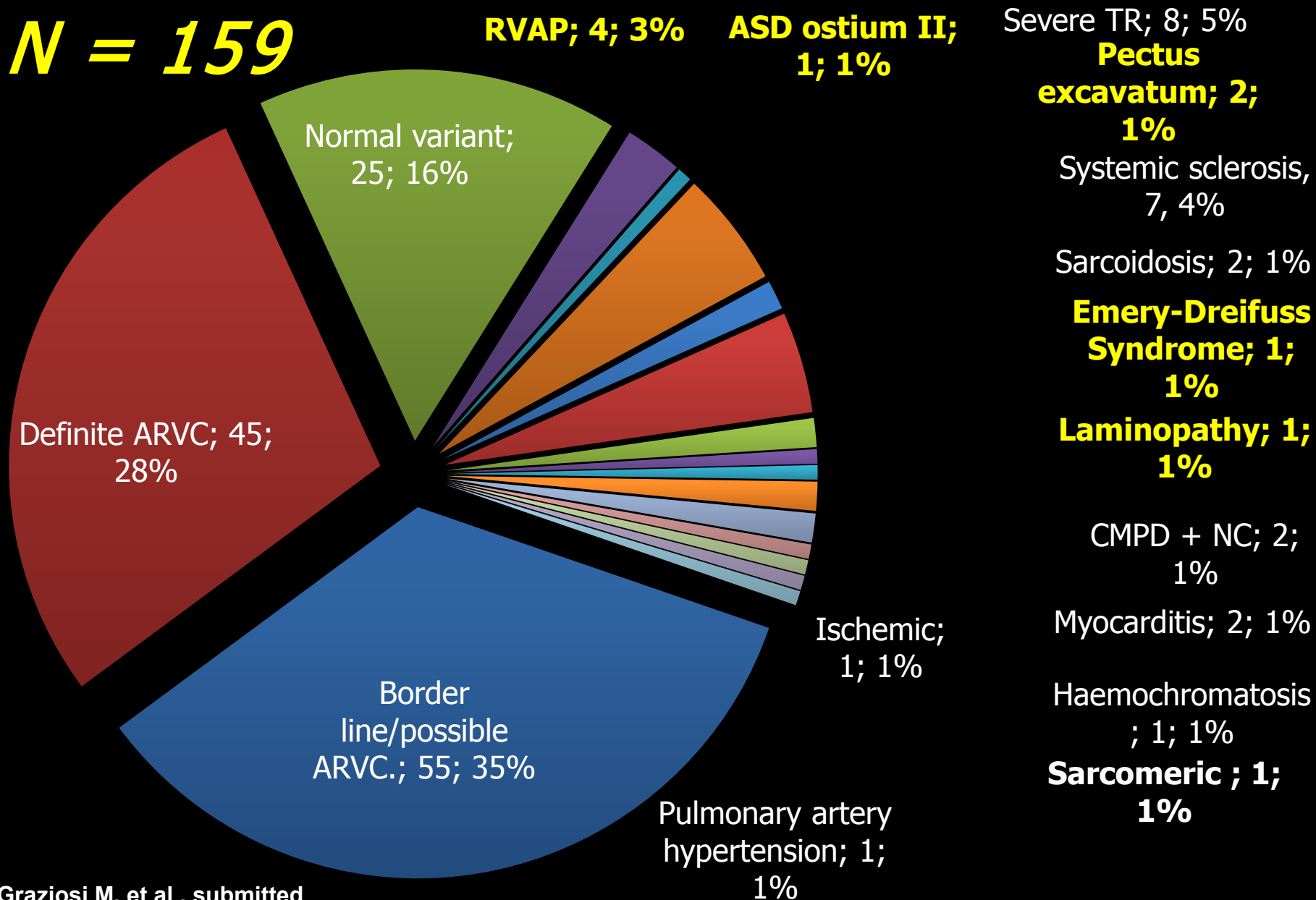




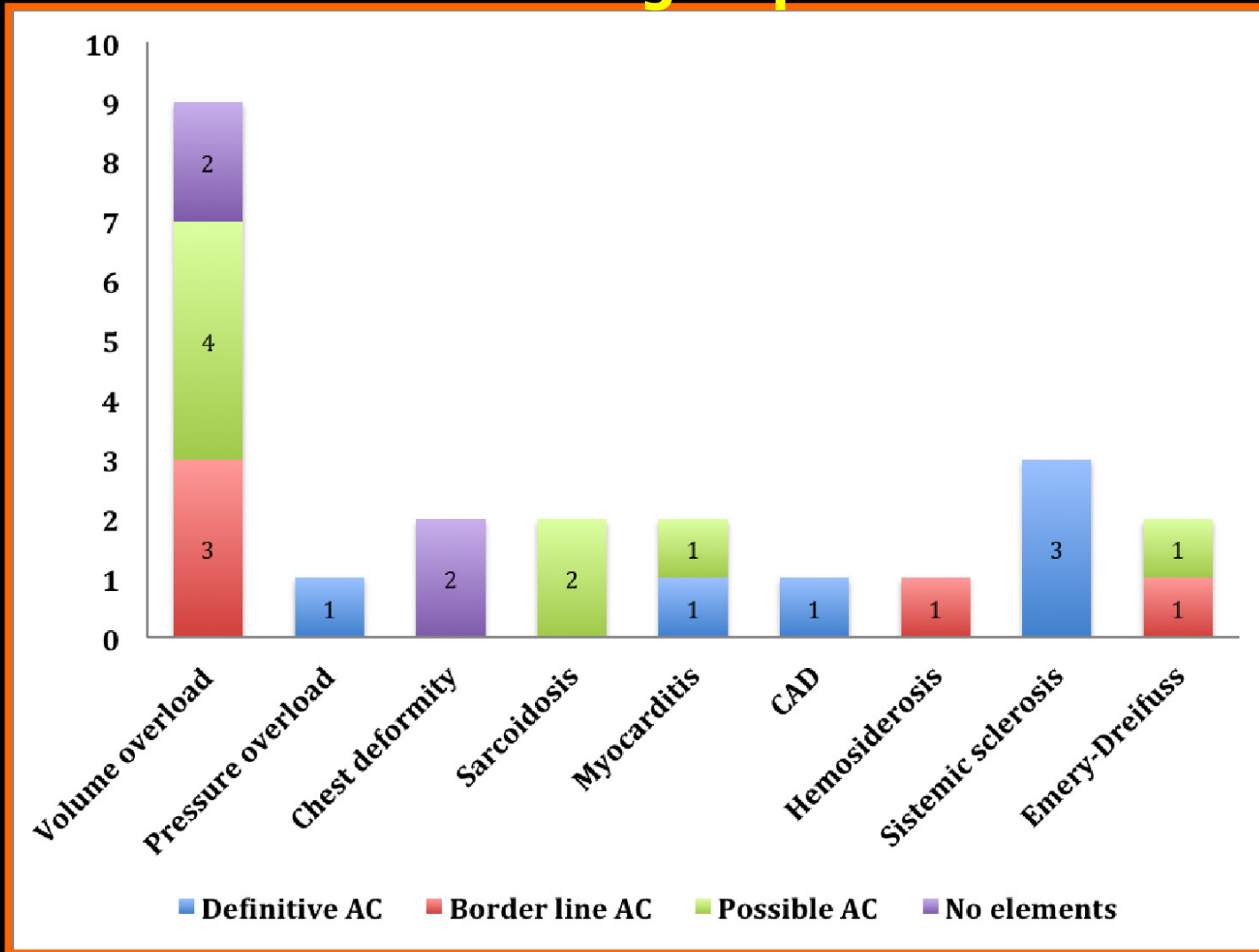
scleroderma

Mimics of ARVC

N = 159



Diagnosis of AC according to Task Force criteria in mimcs group



Definitive diagnosis AC 6 pt

Possible diagnosis of AC 7 pt

Border line diagnosis of AC 7pt

Not enough elements for dg of AC 3 pt

“Pathogenesis” of the cognitive error

- **Deficit of observation/interpretation**
- **Operational superficiality**
- **Ideological superficiality (typically an uncritical reliance on pathognomonic signs and biomarkers)**
- **Cultural deficit**
- **Excess of recent culture (fashion effect)**
- **Hypersemiotic thought process:**
 - **Use of generic diagnostic categories («hypercontainers»)**
 - **Focus on “hypersignificant” (“blinding”) elements**
 - **Absence of method**

PHILIPS

TIS0.7 MI 1.4

IST CARDIOLOGIA BO

S5-1/Adulti

FR 25Hz

16cm

2D/MM

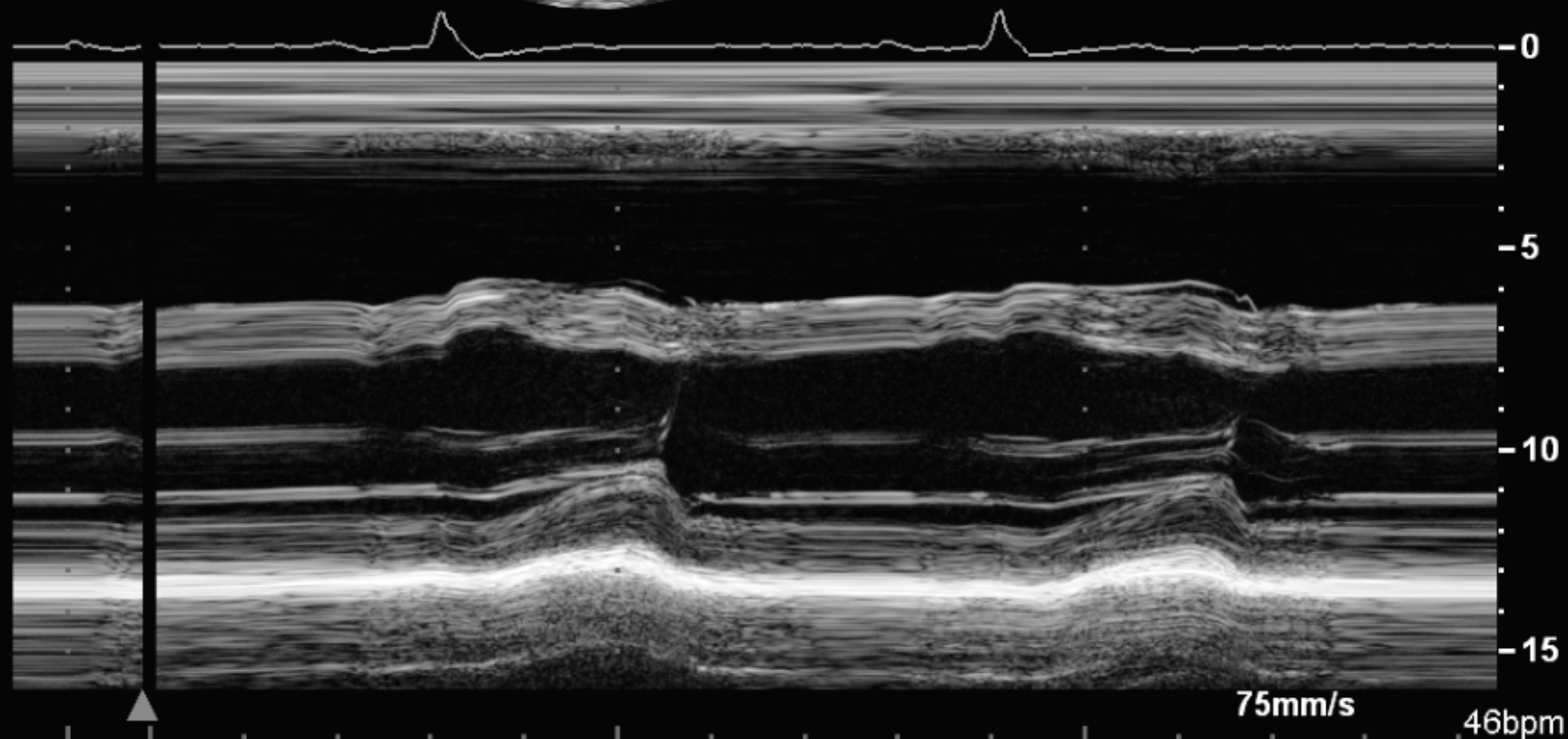
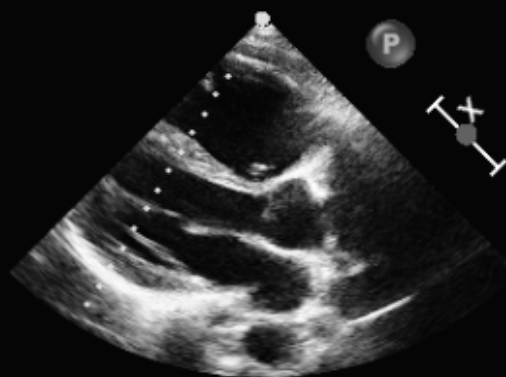
75% 71%

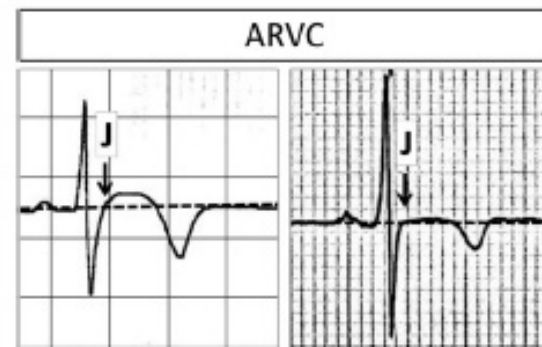
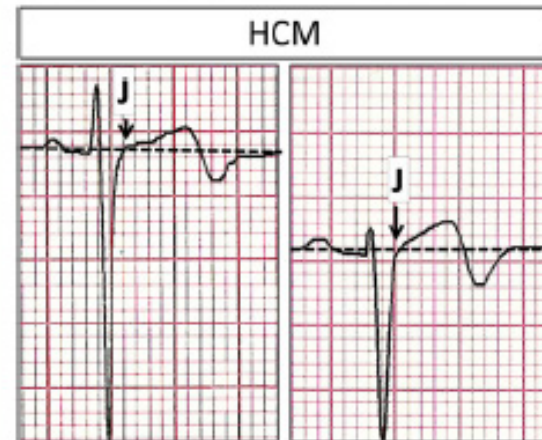
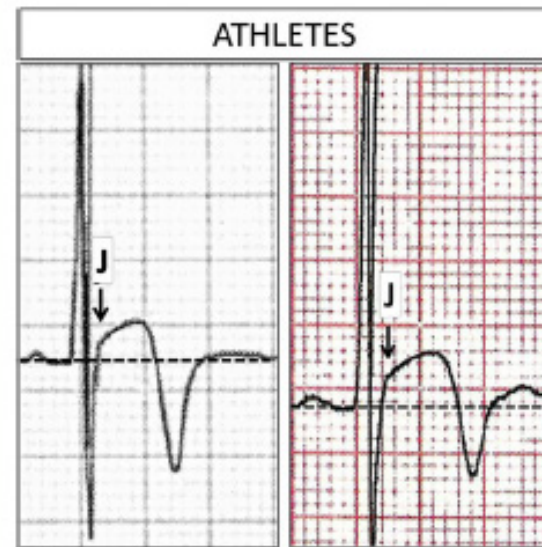
C 50

P Bassa

AGen

M3





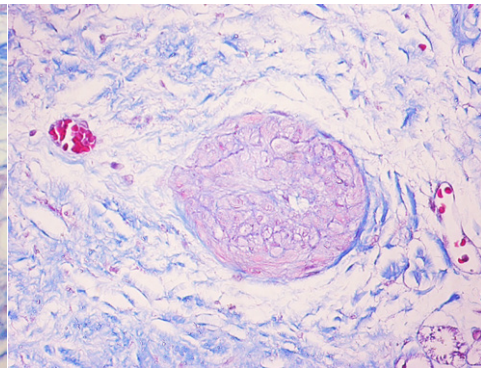
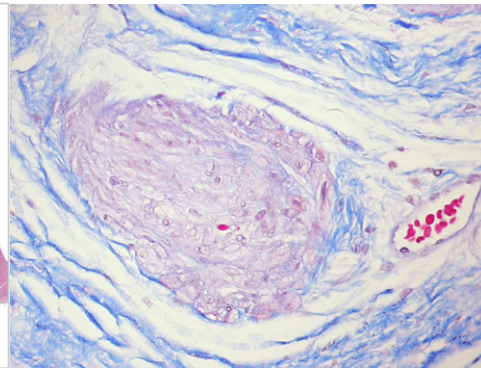
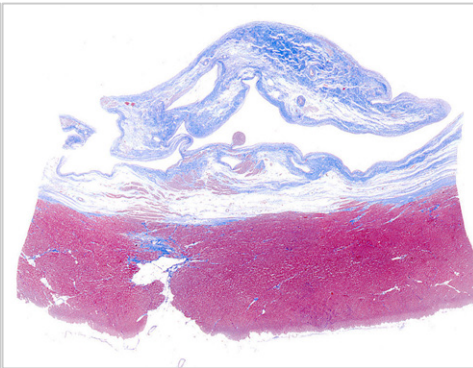
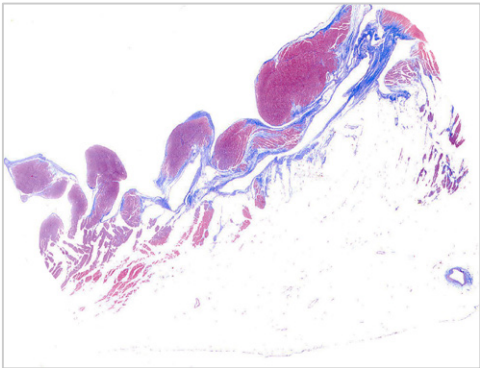
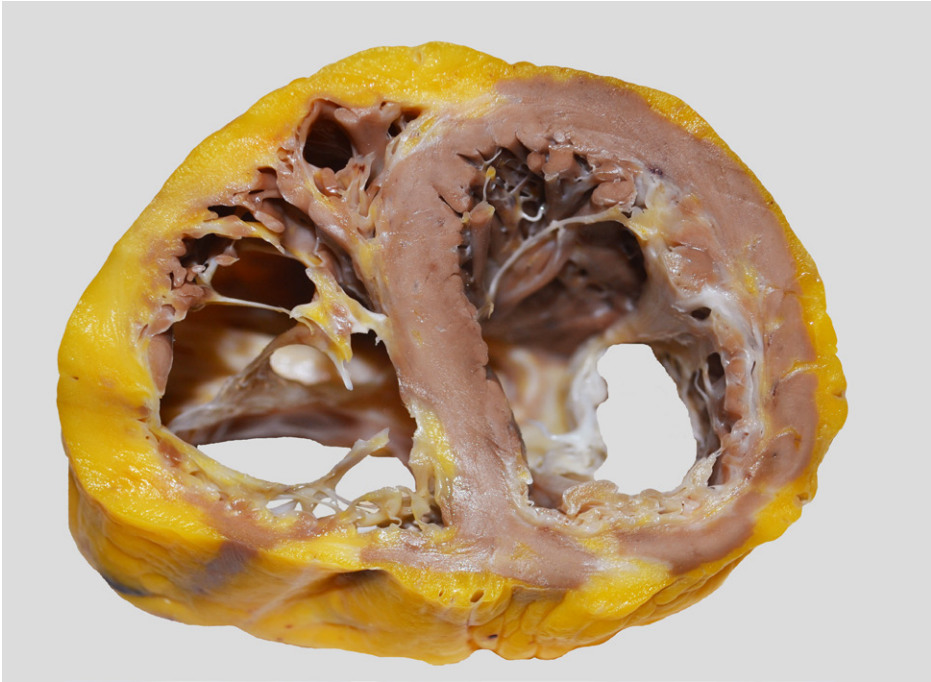
The long and winding road to ARVC

- **Mimics/pitfalls**
- **Phenocopies**
- **Genocopies**

**Acquired conditions with
"desmosomal stress"**

ARVC PHENOTYPE

**Genetic diseases interfering
with desmosomal integrity**

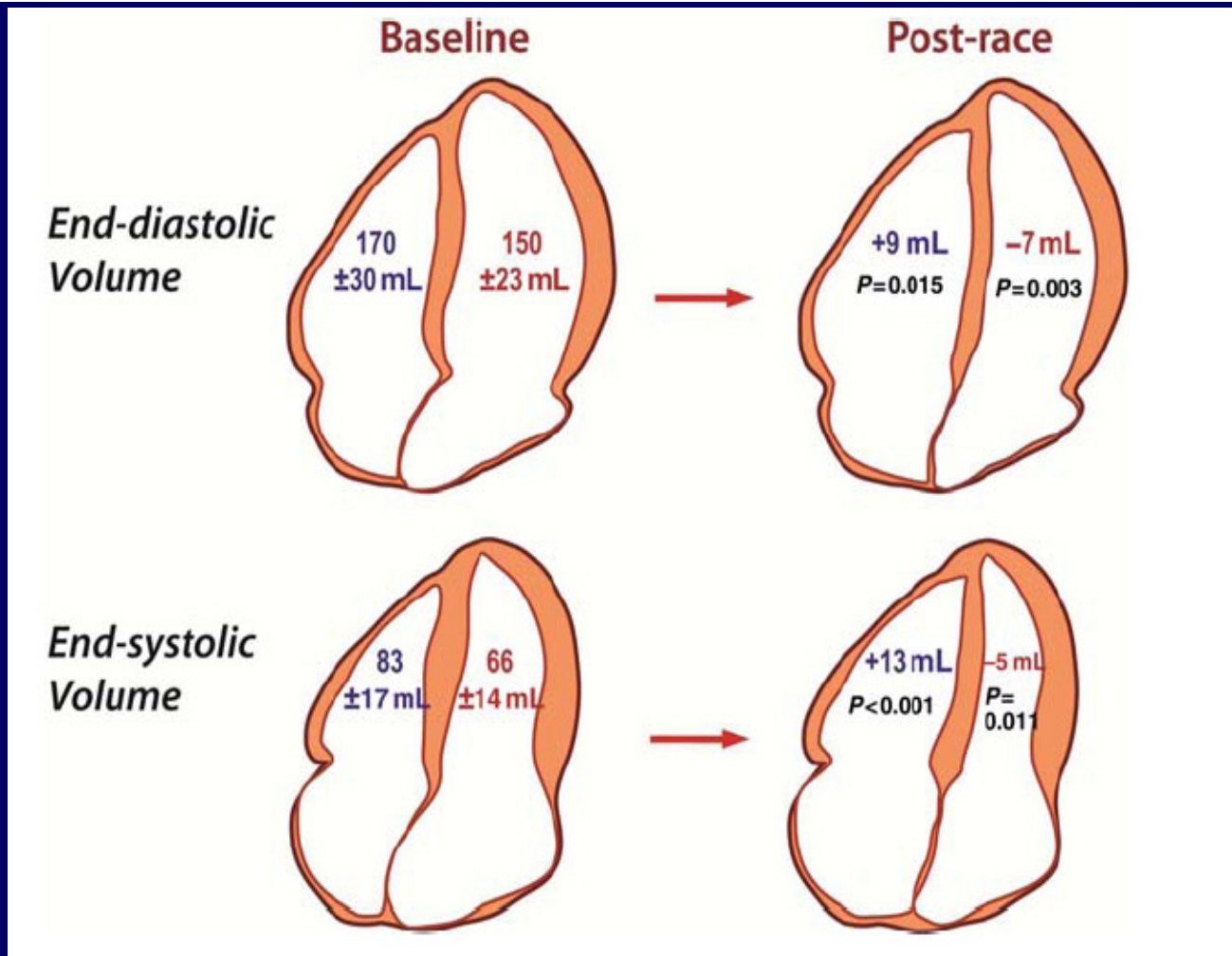


scleroderma

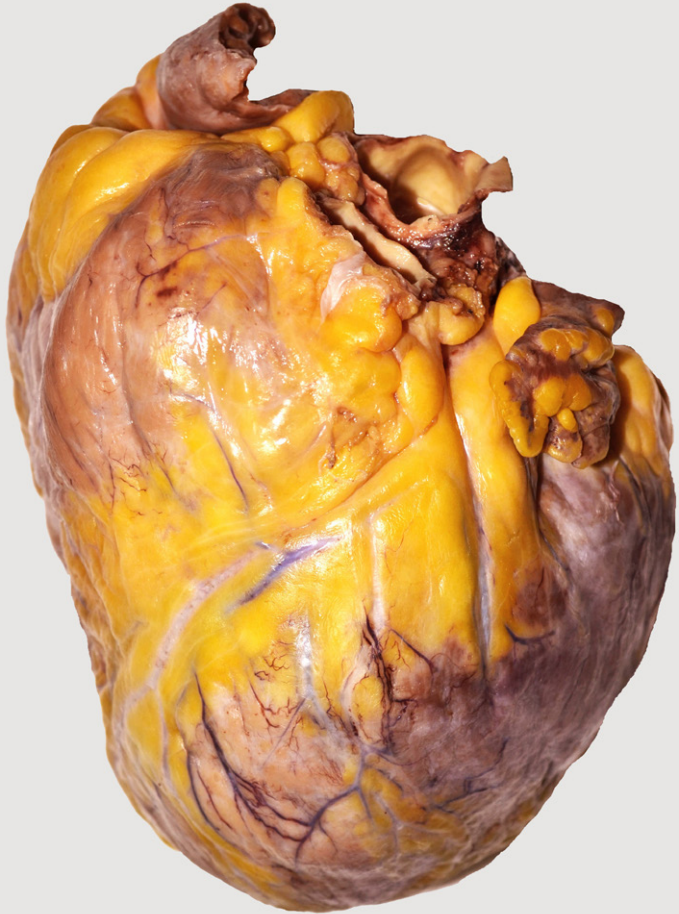
Exercise-induced right ventricular dysfunction and structural remodelling in endurance athletes

André La Gerche^{1,2*}, Andrew T. Burns³, Don J. Mooney³, Warrick J. Inder¹,
Andrew J. Taylor⁴, Jan Bogaert⁵, Andrew I. Maclsaac³, Hein Heidbüchel²,
and David L. Prior^{1,3}

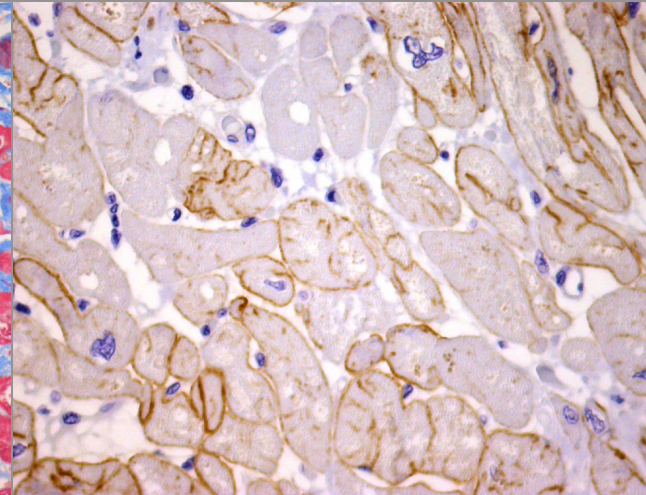
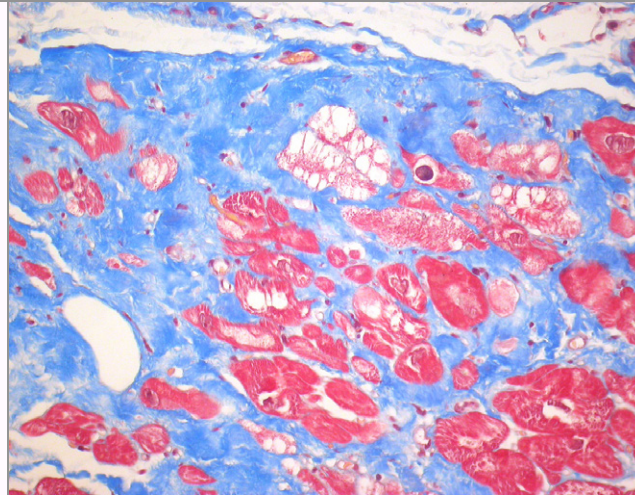
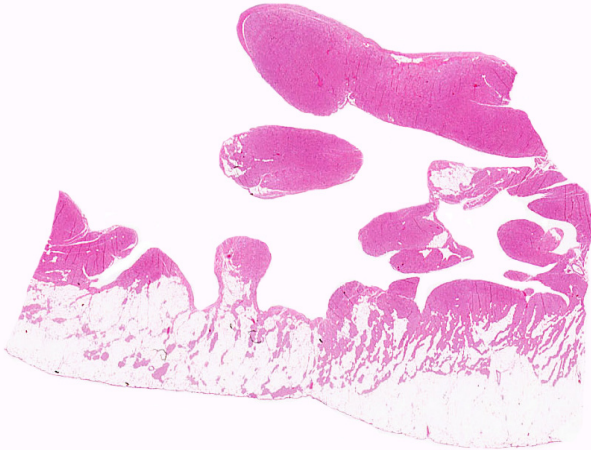
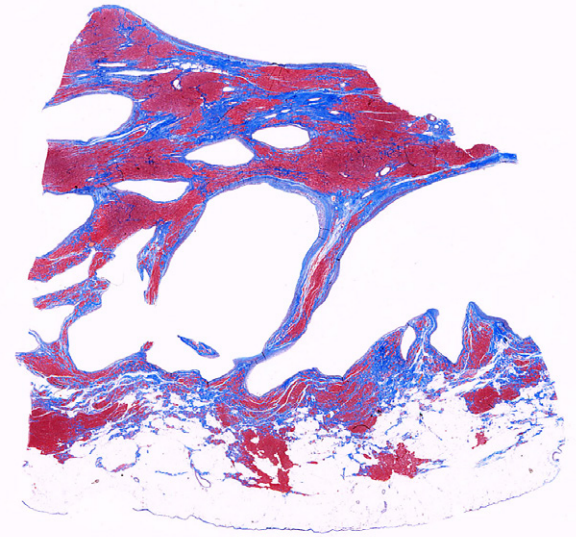
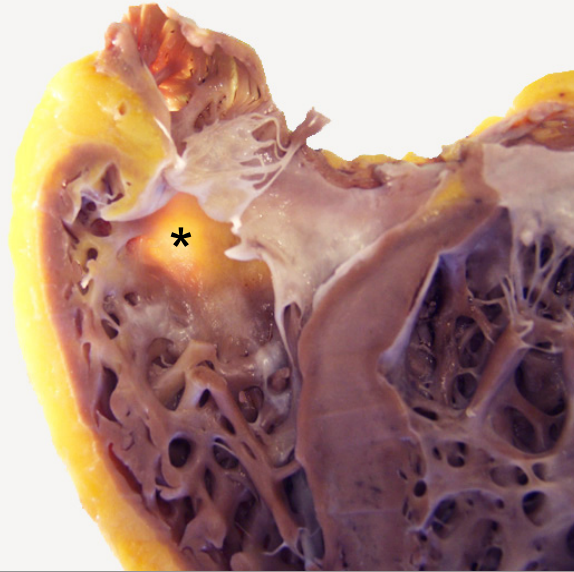
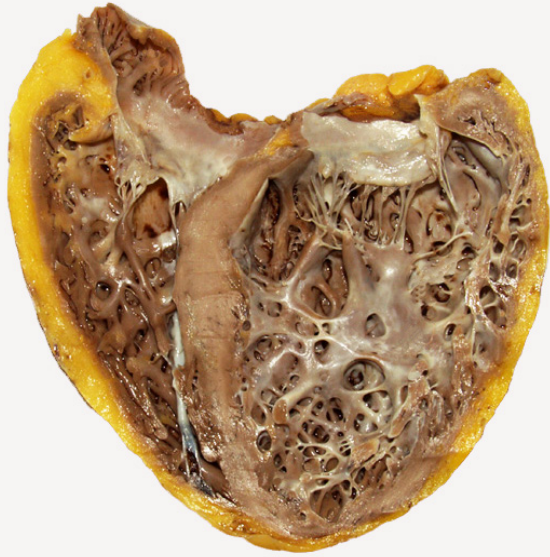European Heart Journal (2012) 33, 998–1006



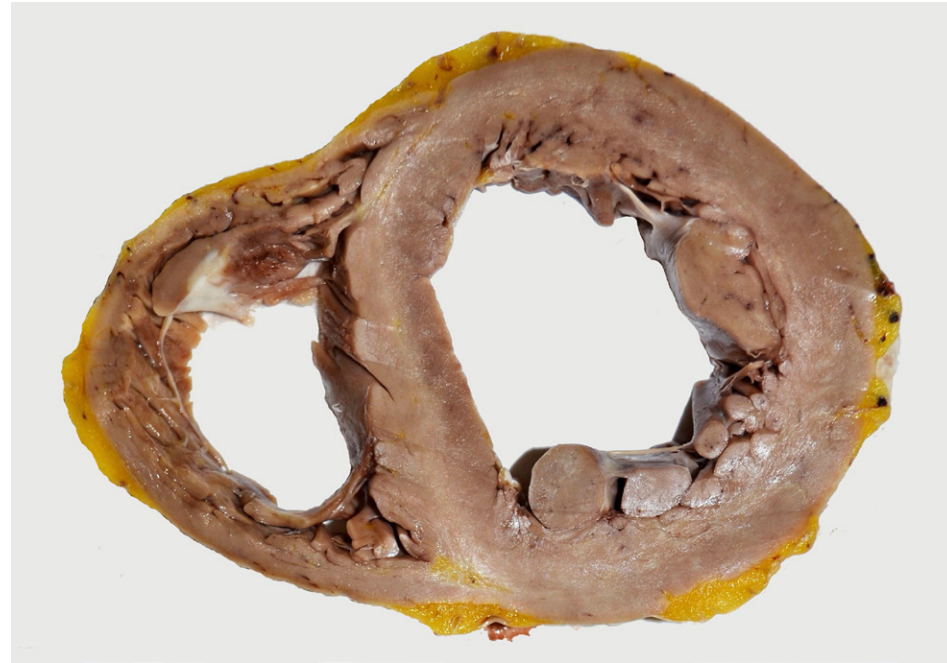
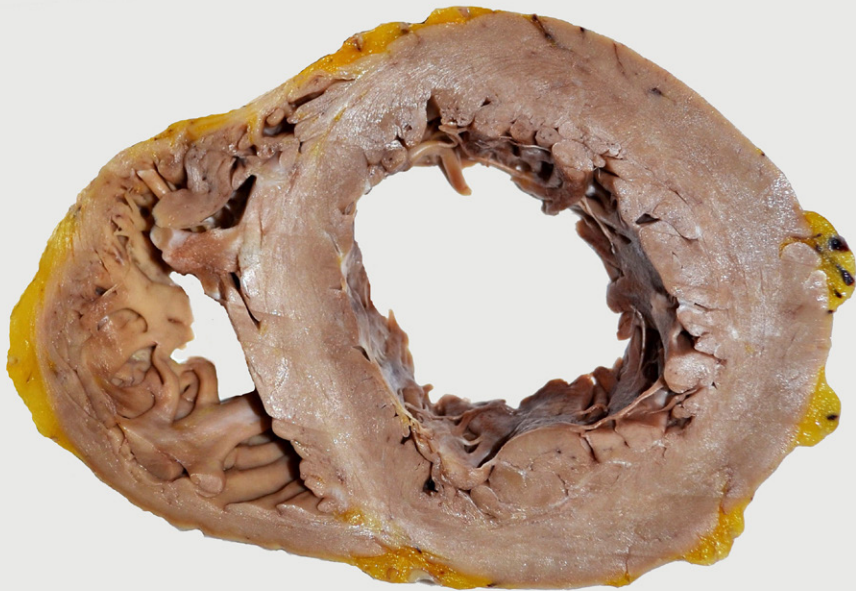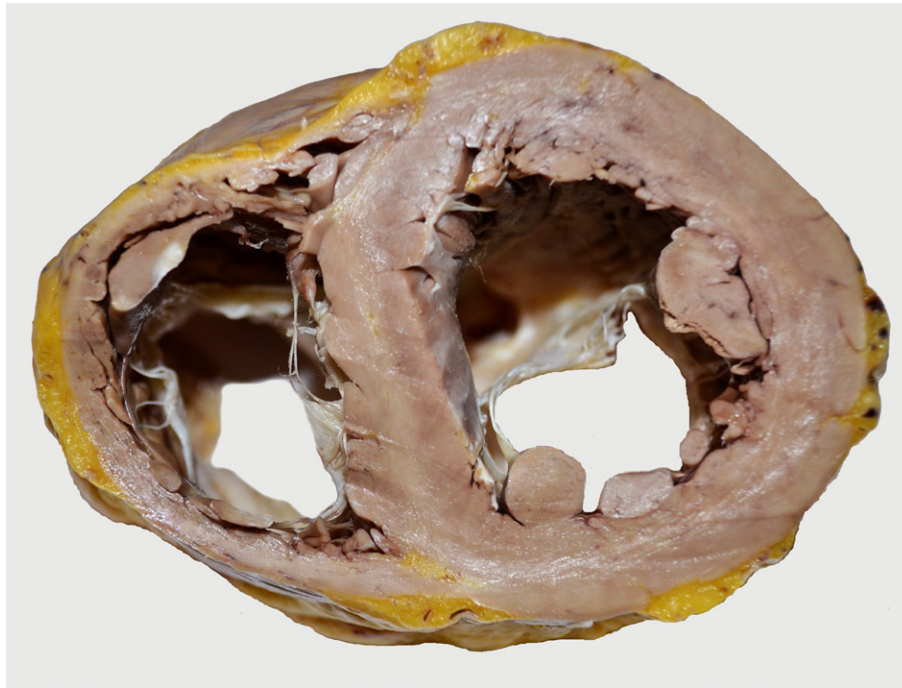
BELELLI – sarcoidosi



Becker Dystrophy



Laminopathy



Genes associated with ARVC

Desmosomal

Desmocollin-2 (DSC2)

Desmoglein-2 (DSG2)

Desmoplakin (DSP)

Junctional Plakoglobin (JUP)

Plakophilin-2 (PKP2)

Non-Desmosomal

Desmin (DES)

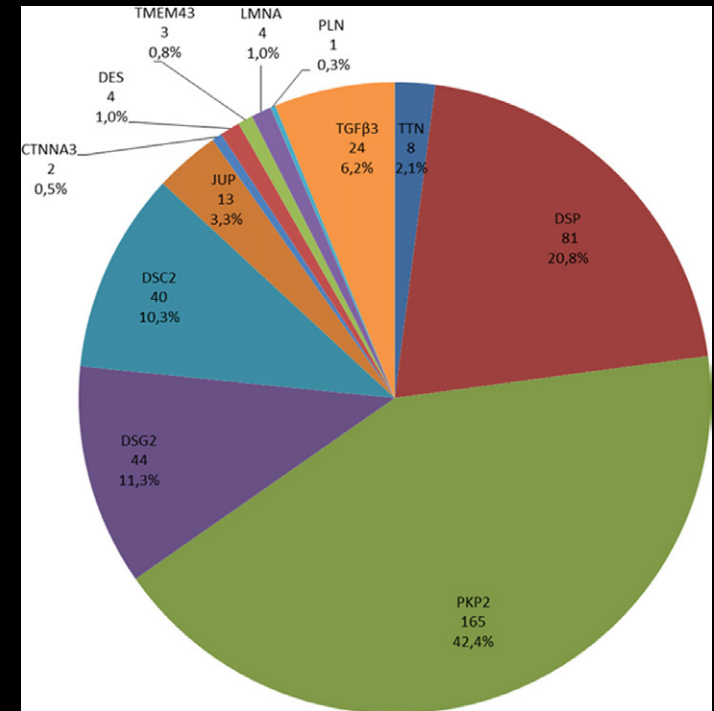
Lamin A/C (LMNA)

Phospholamban (PLN)

Ryanodine Receptor (RYR2)

Transmembrane Protein 43 (TMEM43)

Titin (TTN)



Arrhythmogenic RV Cardiomyopathy (a non-arrhythmologic perspective)

Agenda:

- **Diagnostic pitfalls, mimics and phenocopies**
- **Clinical role of molecular genetic**
- **Role of MRI**
- **ARVC as a cause of HF**
- **From right-side to left-side**
- **Commendation of the standard ECG**

Molecular Biology of CMPs

Paradigm shifts

1. One gene → one disease

2. Many genes → one disease

3. One gene → many diseases

Molecular genetics in diagnosis and prognosis of ARVC

> 11 identified genes

40 % of cases with definite ARVC and negative genetic analysis

6 times higher, is the risk of developing a disease in carriers, but....

> 50 % of carriers do not develop the disease

> 2 desmosomal mutations in the same patient probably = worse prognosis

Arrhythmogenic RV Cardiomyopathy (a non-arrhythmologic perspective)

Agenda:

- **Diagnostic pitfalls, mimics and phenocopies**
- **Role of molecular genetic**
- **Role of MRI**
- **ARVC as a cause of HF**
- **From right-side to left-side**
- **Commendation of the standard ECG**

MYOCARDIAL SUBSTRATE CHARACTERIZATION BY MR

- **Fat**
- **Water (oedema)**
- **Iron**
- **Extra Cellular Volume (fibrosis/inflammatoty cells/ amyloidosis)**

- **T1 fs**
- **T2**
- **T2***
- **LGE; Eq-CMR; T1 map**

La ricerca dell'infiltrazione miocardica adiposa mediante RM

Limiti tecnici

Pitfalls

Varianti normali

Scarsa riproducibilità

Aufferman W et al AJR 1999

Tandri H et al J Cardiovasc Electrophysiol 2003

Bluemke DA et al Cardiology 2003

Tandri H et al JACC 2006

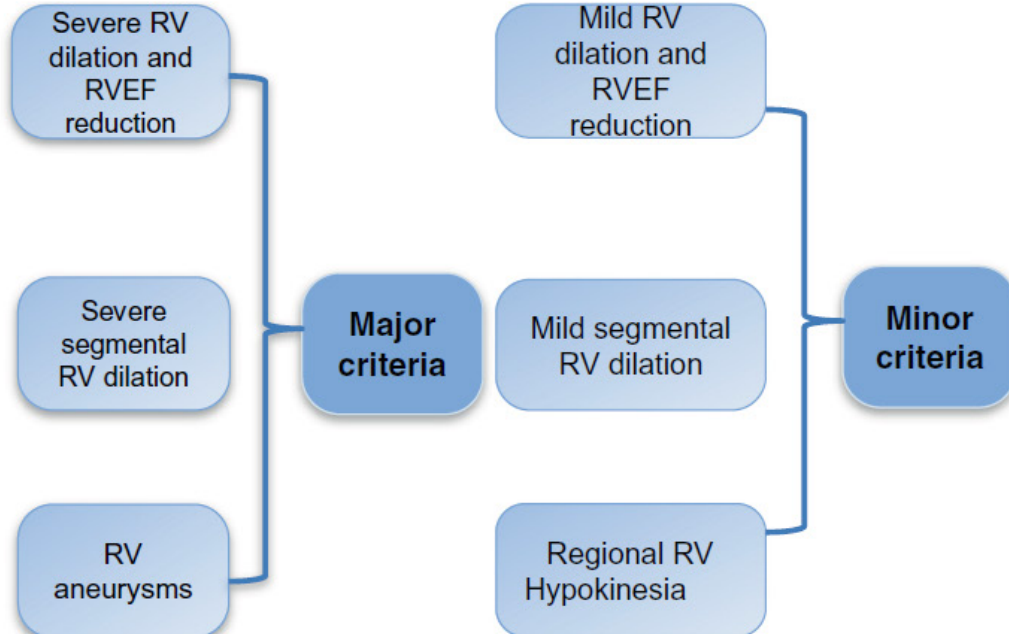
Tandri H et al AHJ 2008

MRI in ARVC

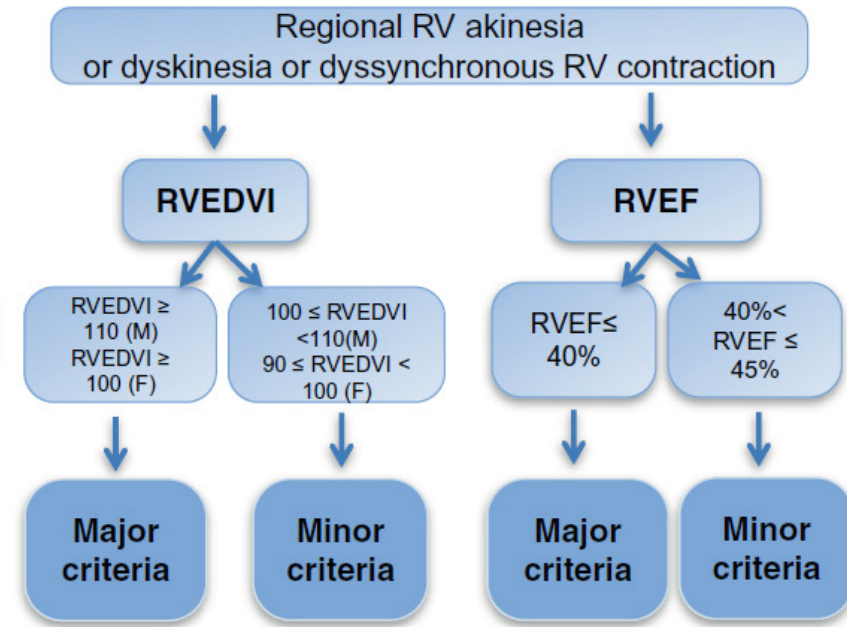
Change of focus

- **From search of fat infiltration to morpho-functional definition of the RV**
- **From fat to fibrosis**
- **From right to left**

1994 CMR TFC

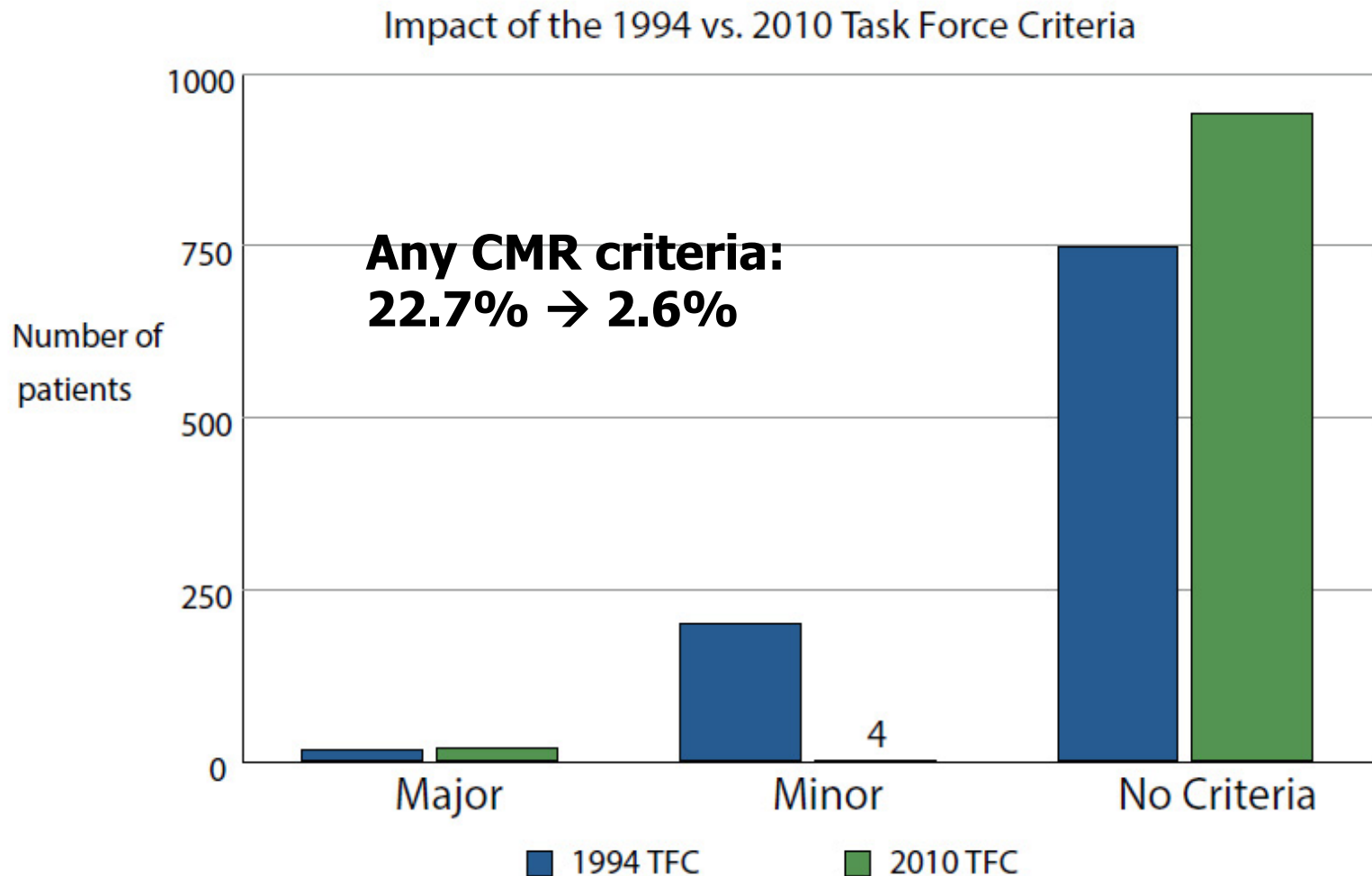


2010 CMR TFC



Effect of the 2010 task force criteria on reclassification of cardiovascular magnetic resonance criteria for arrhythmogenic right ventricular cardiomyopathy

Liu et al. *Journal of Cardiovascular Magnetic Resonance* 2014, **16**:47

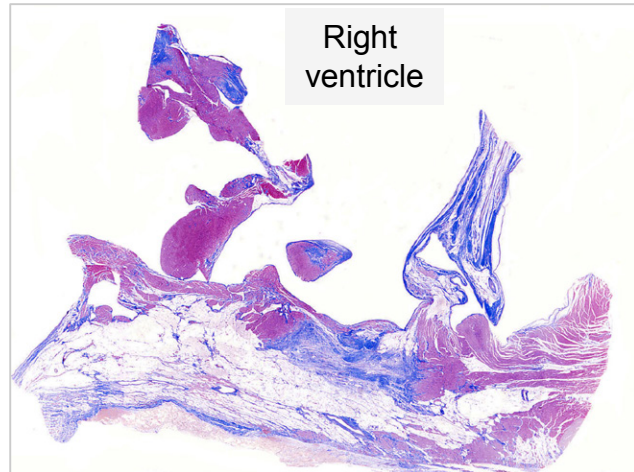
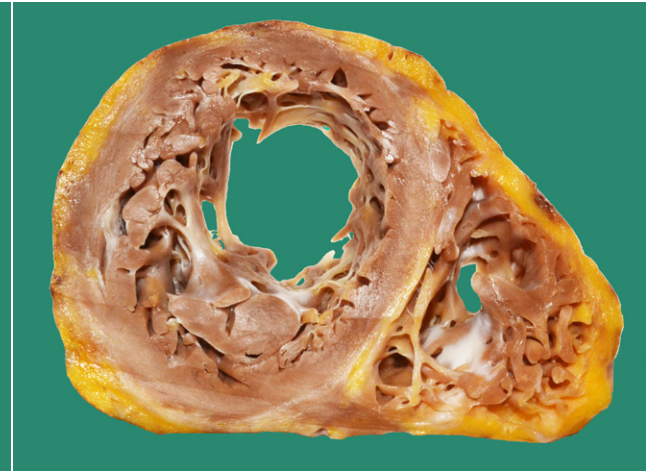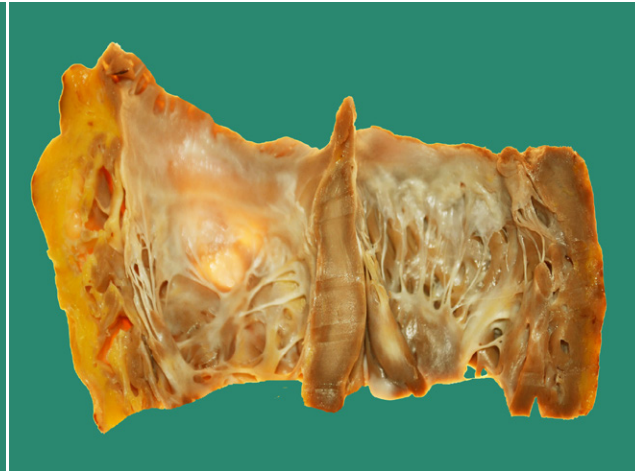
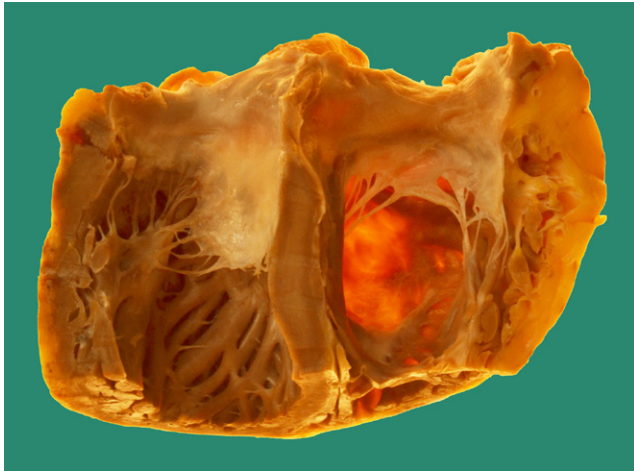


MRI in ARVC

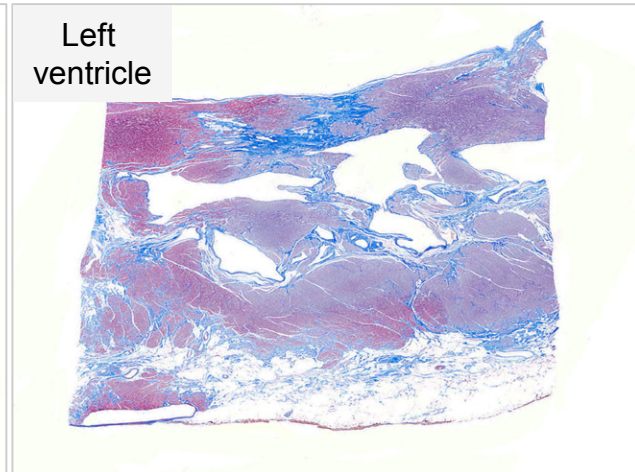
Change of focus

- From search of fat infiltration to morpho-functional definition of the RV
- From fat to fibrosis
- From right to left

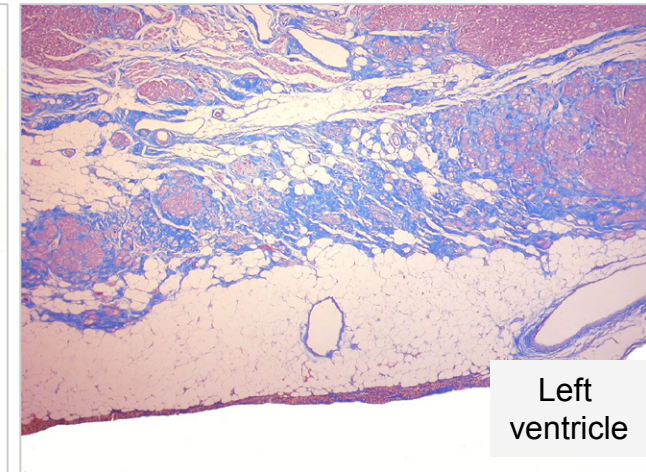
ARVC with LV involvement



Right
ventricle




Left
ventricle

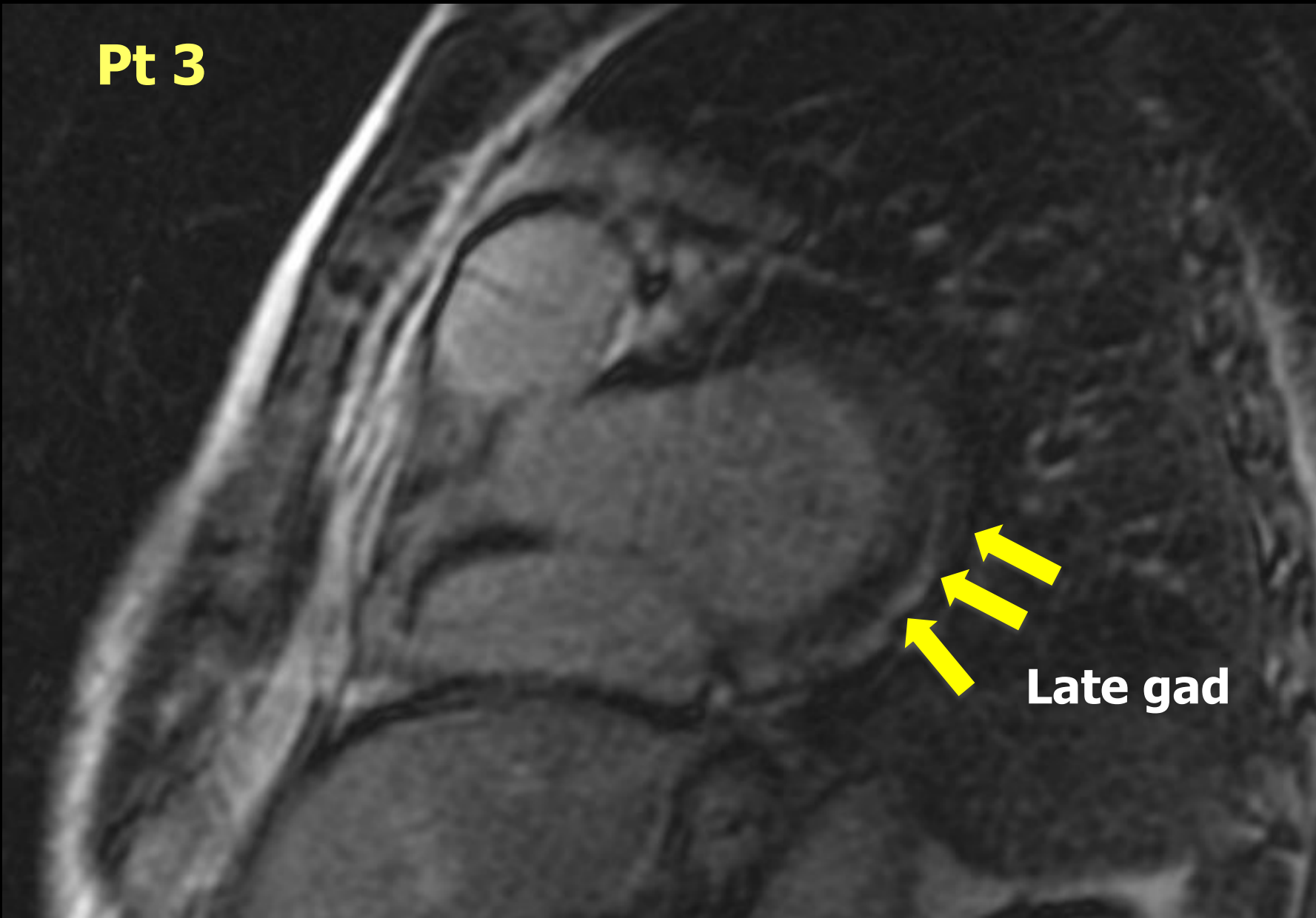


Left
ventricle

Pt 3



Late gad



ARVC and LV involvement

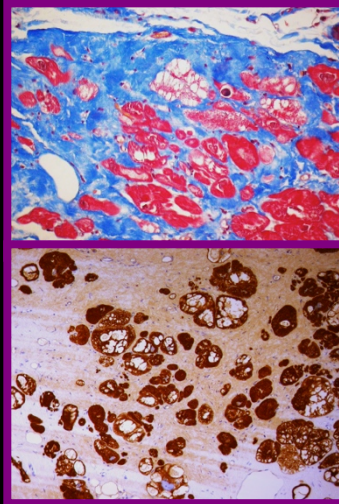
ARVC with associated segmental involvement of the LV

BIVENTRICULAR AC

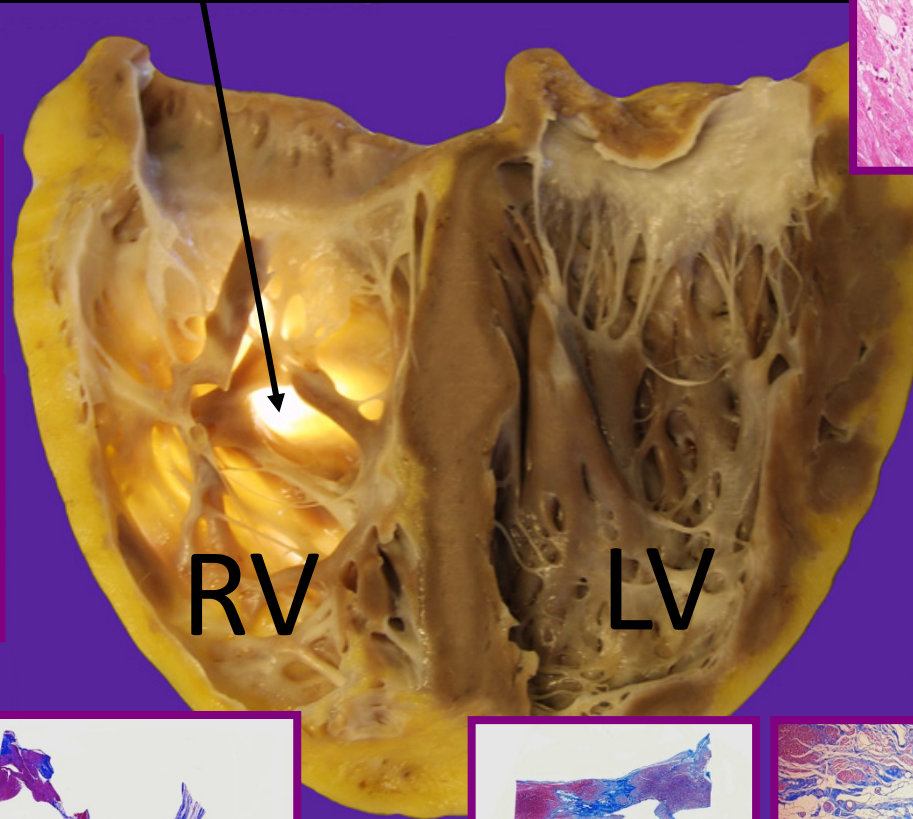
Isolated ALVC (left dominant)

36 explanted hearts

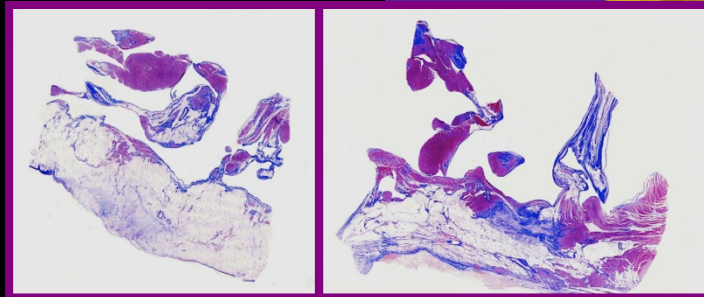
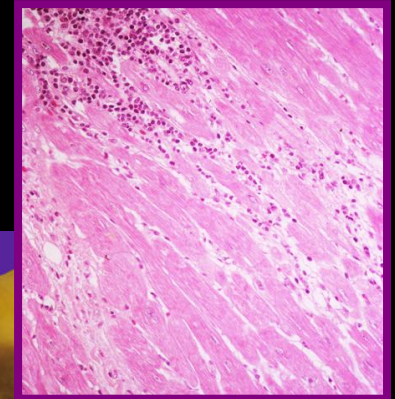
Damage of myocytes
(hypertrophy, dysmetry,
sarcoplasmic
vacuolization



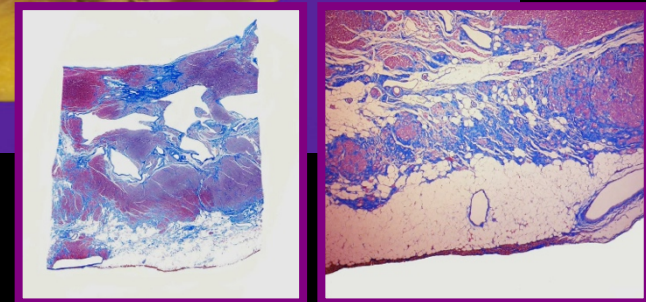
Wall
transillumination



Biventricular
flogistic
infiltration



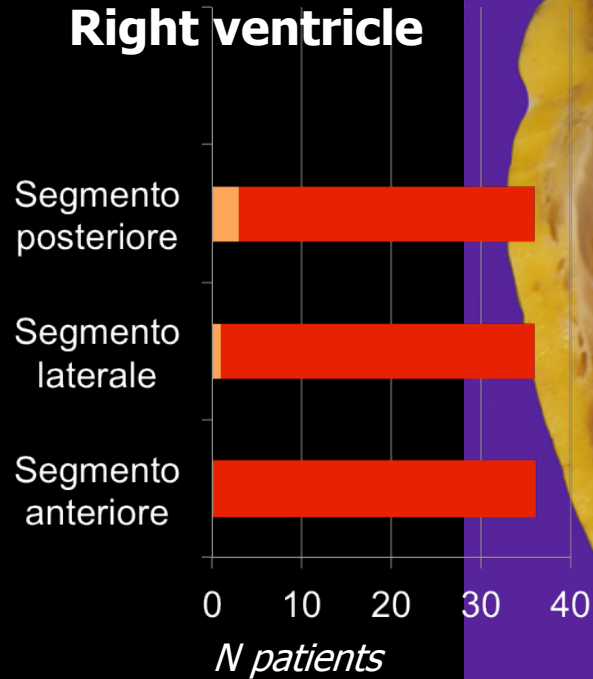
Transmurular fibro-fatty infiltration of RV



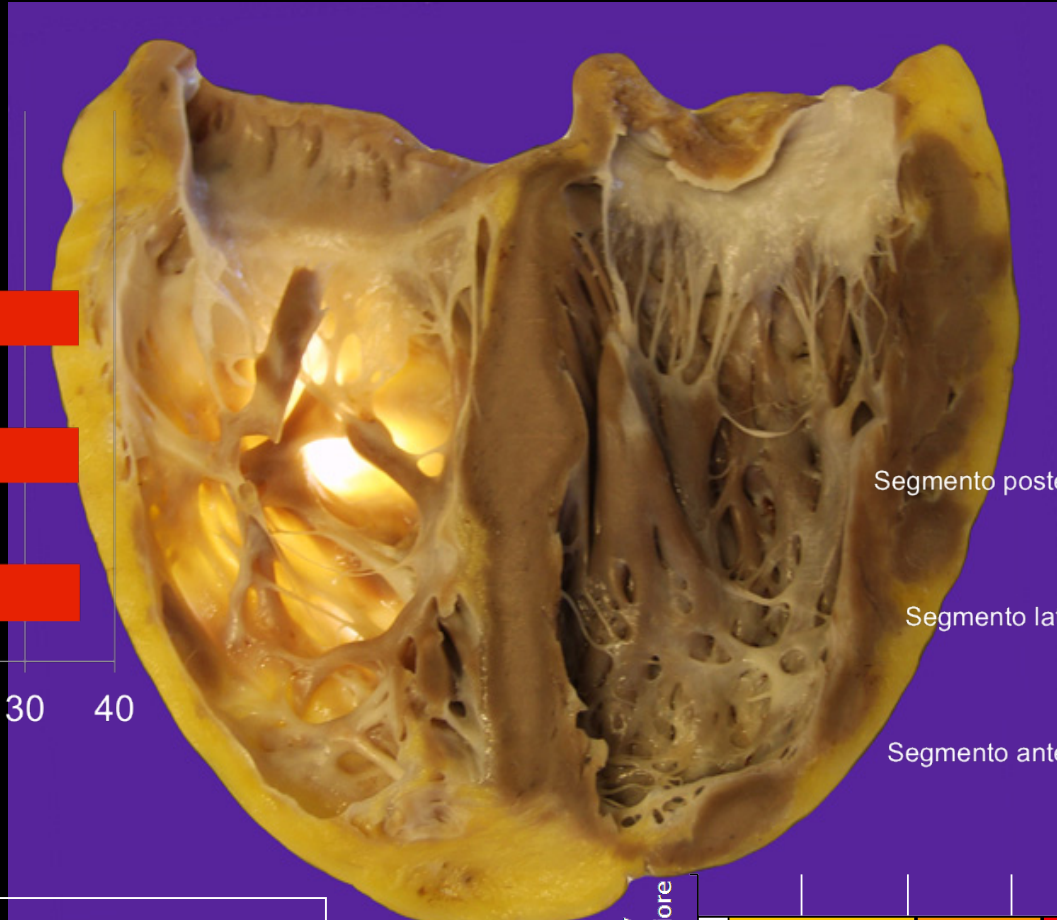
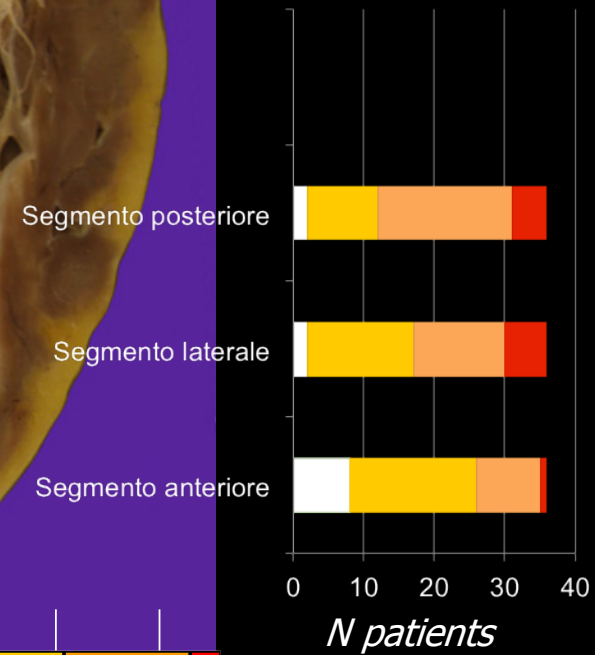
Fibro-fatty infiltration of LV
(prevalent fibrosis)

Different degrees of fibro-fatty infiltration of ventricles (medioventricular transversal section)

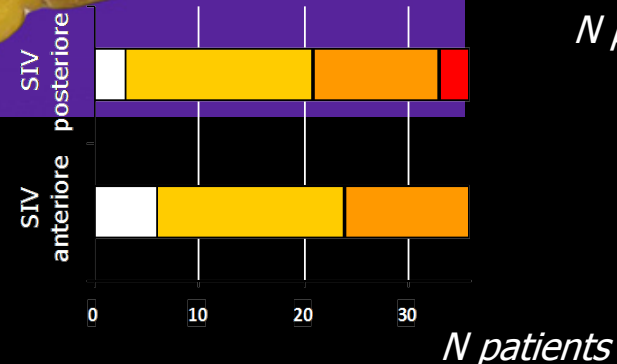
Right ventricle



Left ventricle



Septum



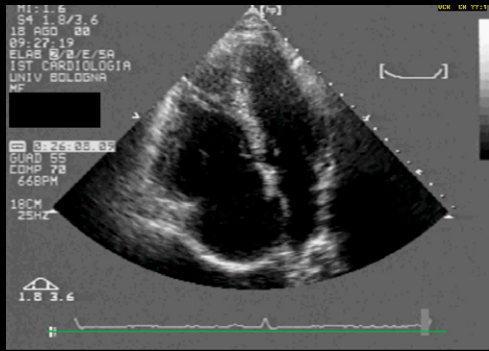
Legend

- Normal myocardium
- Subepicardial infiltration
- Mediomural infiltration
- Transmural infiltration

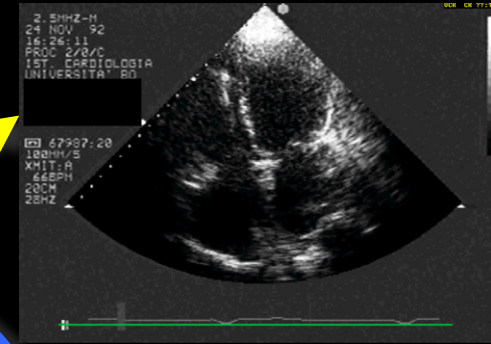


Pathophysiology of severe HF in ARVC

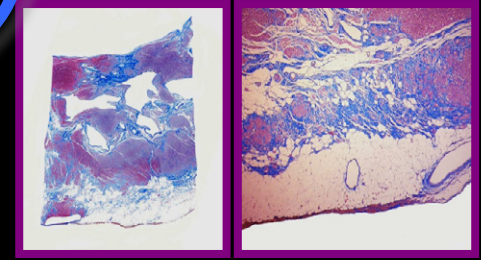
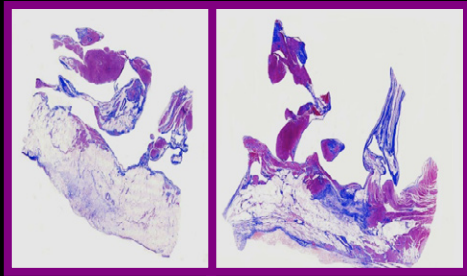
Severe global RV dysfunction



LV involvement



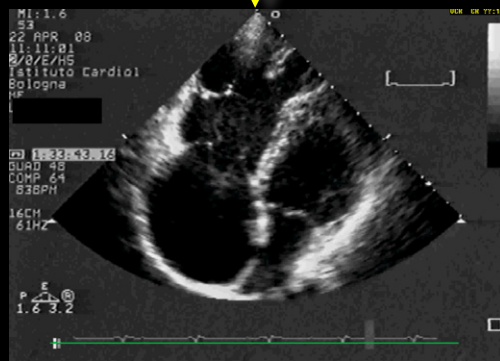
End stage HF




Transmurular fibro-fatty infiltration

Fibro-fatty infiltration with prevalent fibrosis

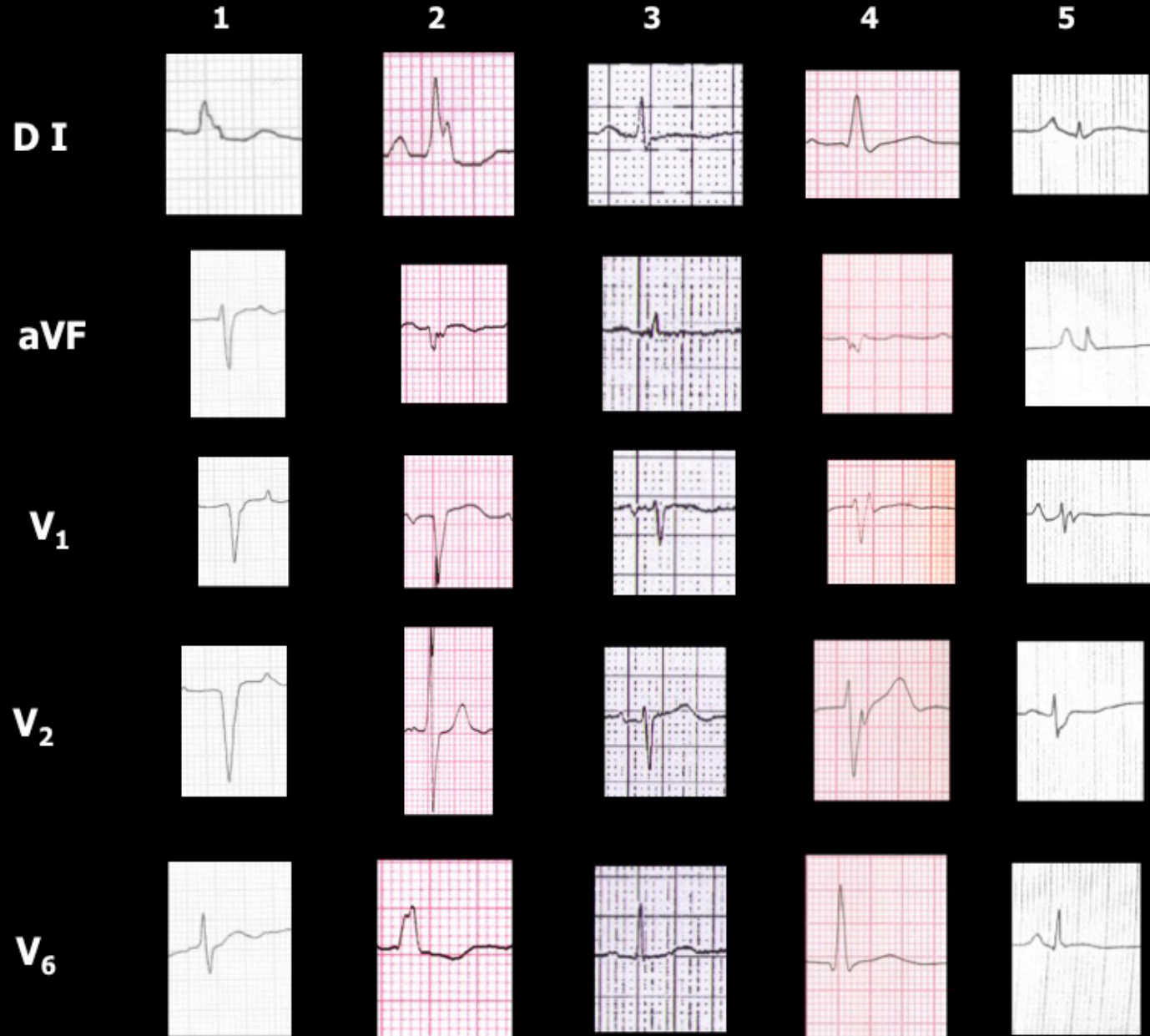
Extreme inflow dilation leading to massive TR



Peculiar ECG in pt who underwent heart transplantation: RBBB like



Peculiar ECG in pt who underwent heart transplantation: LBBB like



ARVC and LV involvement

ARVC with associated segmental involvement of the LV

BIVENTRICULAR AC

Isolated ALVC (left dominant)

Characterization of the Left-Sided Substrate in Arrhythmogenic Right Ventricular Cardiomyopathy

Benjamin Berte, MD; Arnaud Denis, MD; Sana Amraoui, MD; Seigo Yamashita, MD, PhD;
Yuki Komatsu, MD; Xavier Pillois, MD, PhD; Frédéric Sacher, MD, PhD;
Saagar Mahida, MD, PhD; Jean-Yves Wielandts, MD, MSc; Jean-Marc Sellal, MD;
Antonio Frontera, MD; Nora Al Jefairi, MD; Nicolas Derval, MD;
Michel Montaudon, MD, PhD; François Laurent, MD; Méléze Hocini, MD;
Michel Haïssaguerre, MD; Pierre Jaïs, MD, PhD; Hubert Cochet, MD, PhD

Circ Arrhythm Electrophysiol. 2015;8:1403-1412.

...Imaging abnormalities were found in 32 (100%) and **21 (66%)** patients on the RV and **LV**, respectively, intramyocardial fat on multidetector computed tomography being the most sensitive feature....

Prevalence of Desmosomal Protein Gene Mutations in Patients With Dilated Cardiomyopathy

Perry Elliott, MD; Constantinos O'Mahony, MBBS (Lond); Petros Syrris, PhD; Alison Evans, PhD; Christina Rivera Sorensen, MSc; Mary N. Sheppard, MD; Gerald Carr-White, PhD; Antonios Pantazis, MD; William J. McKenna, DSc

- Mutation screening of 5 genes implicated in ARVC (plakoglobin, desmoplakin, plakophilin-2, desmoglein-2, desmocollin-2) in 100 consecutive unrelated pt with idiopathic dilated cardiomyopathy
- 5 pt were found to carry pathogenic mutation
- 13 pt had sequence variants of uncertain significance
- None of 5 carriers of desmosomal mutation fulfilled current diagnostic criteria for ARVC, but 1 ah fibrofatty infiltration at autopsy
- Pt with desmosomal mutation had a phenotype indistinguishable from the other

Desmosomal protein gene mutations in patients with idiopathic dilated cardiomyopathy undergoing cardiac transplantation: a clinicopathological study

Pablo Garcia-Pavia,¹ Petros Syrris,² Clara Salas,³ Alison Evans,² Jesus G Mirelis,¹ Marta Cobo-Marcos,¹ Carlos Vilches,⁴ Belen Bornstein,⁵ Javier Segovia,¹ Luis Alonso-Pulpon,¹ Perry M Elliott²

- Genetic screening of 5 desmosomal genes (PKP2, DSP, DSC2, DSG2 and JUP) in 89 unrelated pt transplanted for end-stage DCM
- Pathogenic mutations identified in 12 pt (13%). Five additional pt (6%) had genetic variant of unknown significance

PHILIPS

TISO.6 JPEg CR 20:1 MI 1.3

PHILIPS

TISO.6 JPEg CR 21:1 MI 1.3

S5-1/MF

S5-1/MF

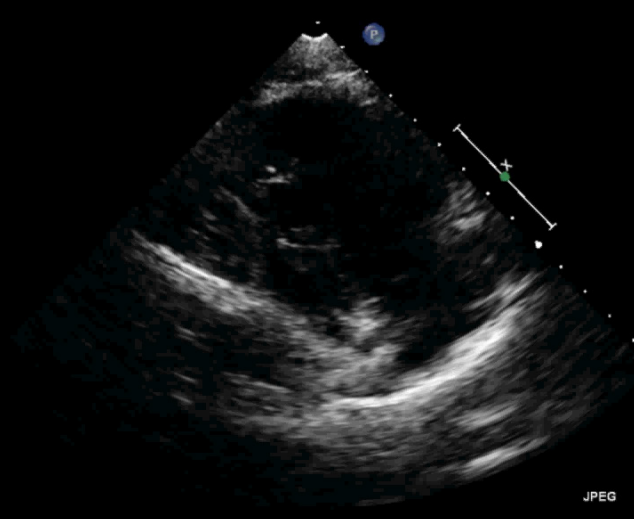
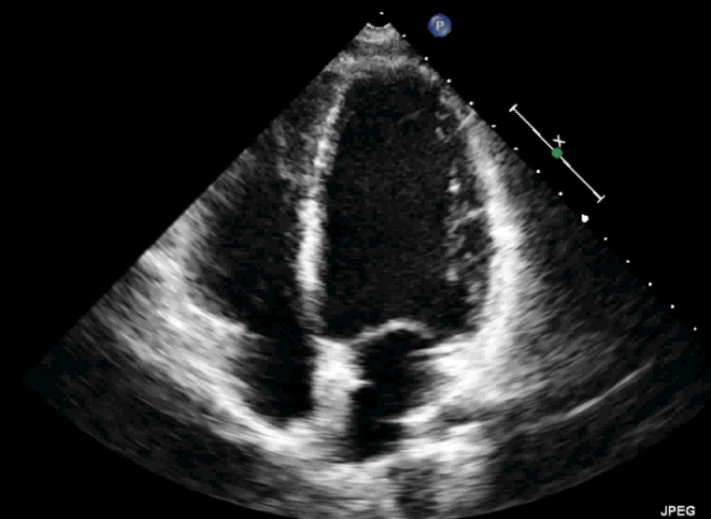
Pt 1

FR 49Hz
16cm

FR 53Hz
14cm

2D
70%
C 50
P Bassa
AGen

2D
70%
C 50
P Bassa
AGen



JPEG

JPEG

67 bpm

63 bpm

Pt 2

PHILIPS

TISO.8 JPEg CR 21:1 MI 1.4

PHILIPS

TISO.8 JPEg CR 21:1 MI 1.4

S5-1/MF

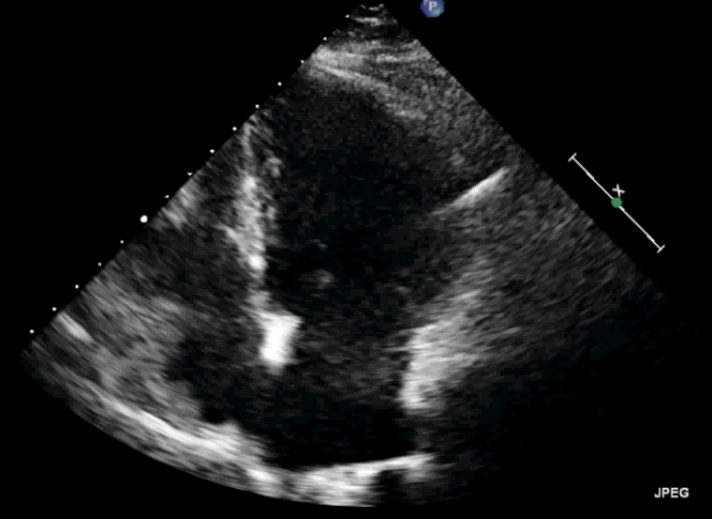
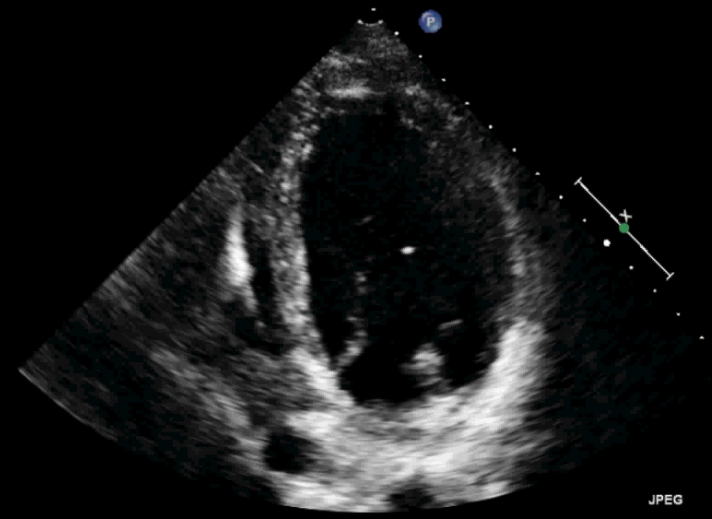
S5-1/MF

FR 50Hz
15cm

FR 49Hz
16cm

2D
63%
C 50
P Bassa
AGen

2D
58%
C 50
P Bassa
AGen

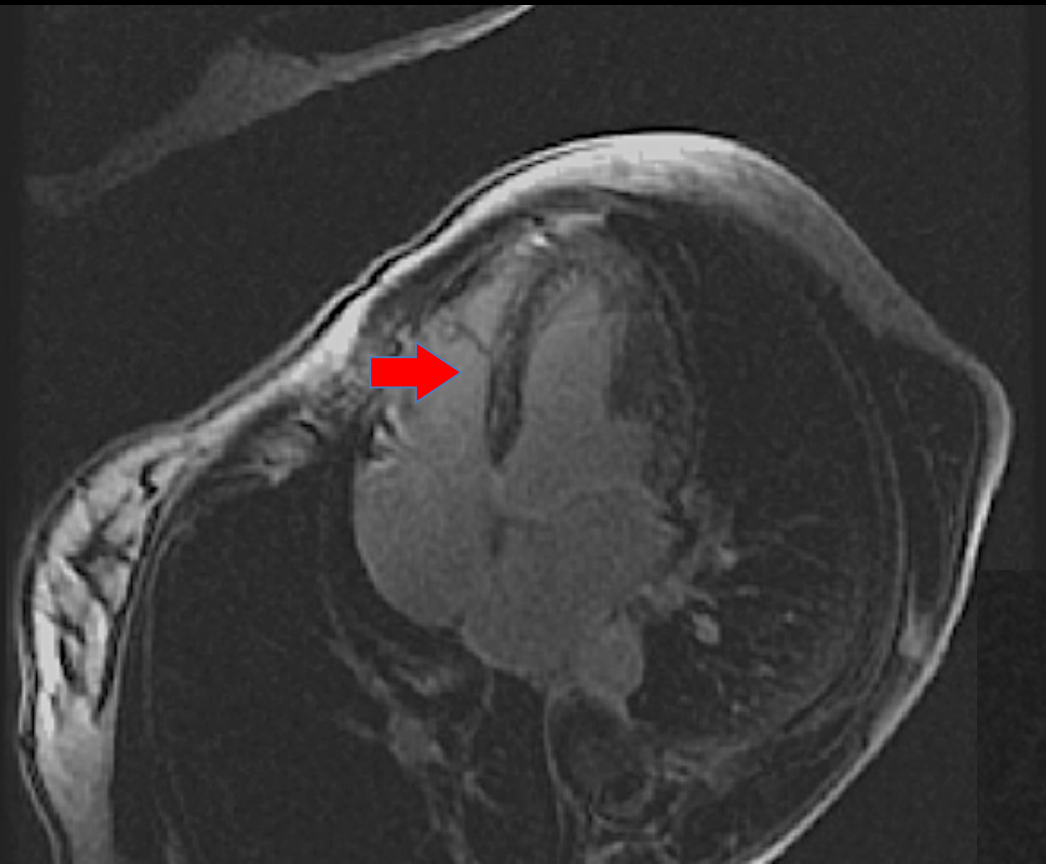


JPEG

JPEG

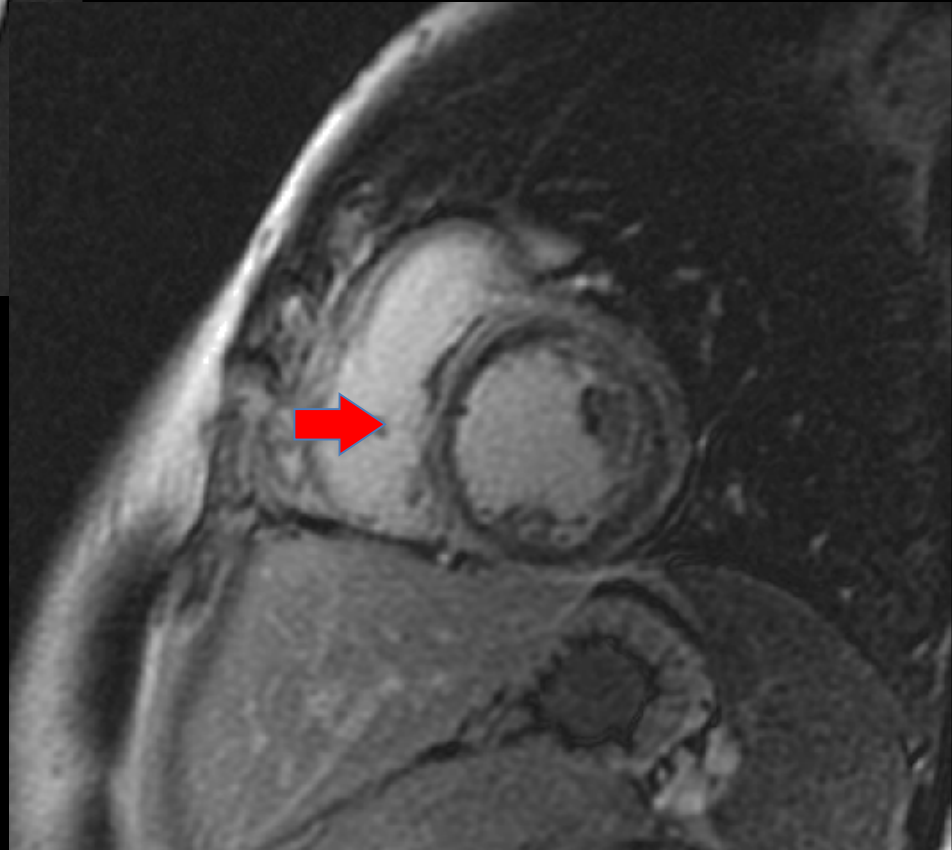47 bpm

65 bpm



Pt 1

Late gad



Pt 2


Late gad

RA

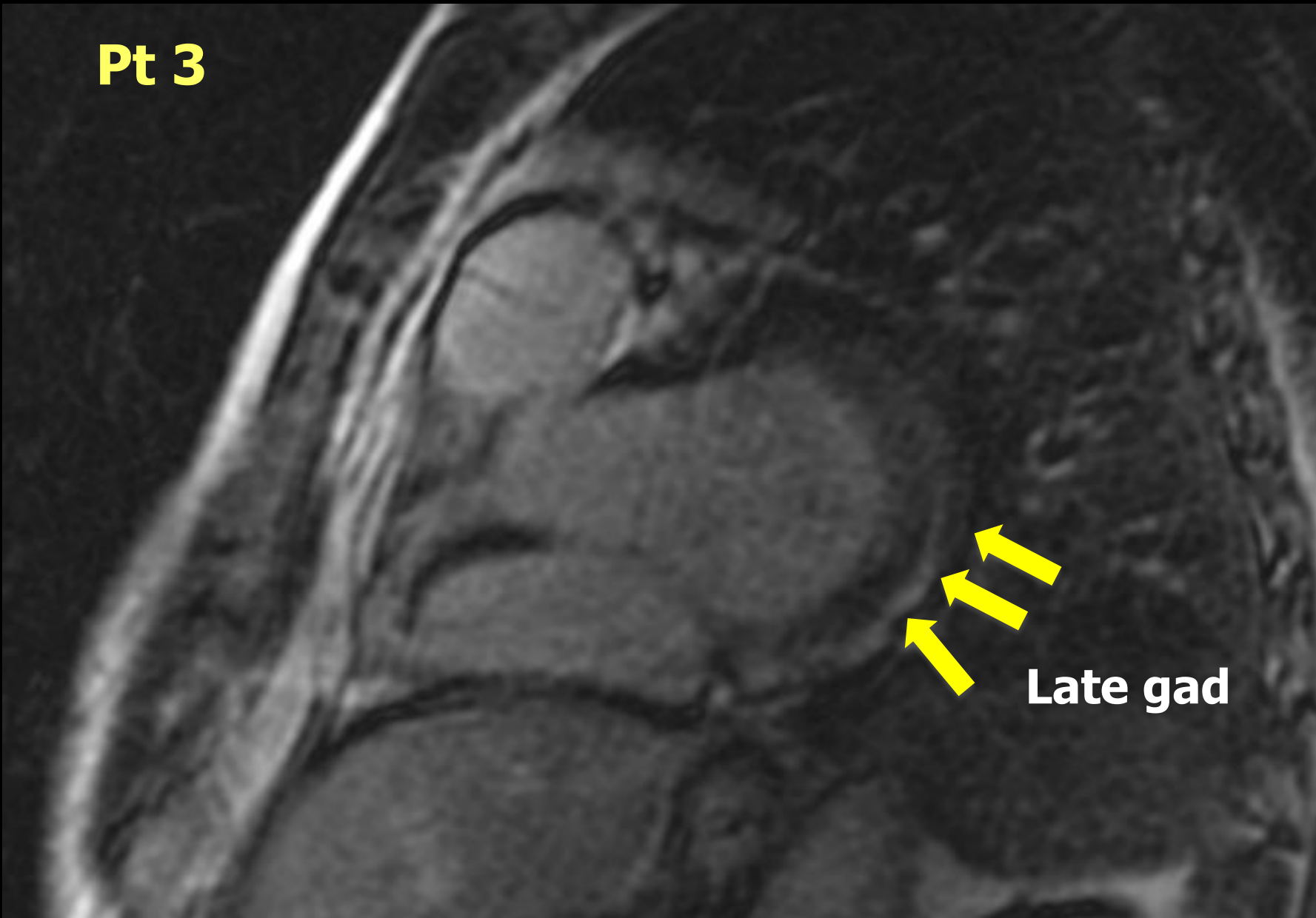
7/310/2
Et: 1 TA: 20
512x512
8mm
Enc: ^
1nex



Pt 3



Late gad



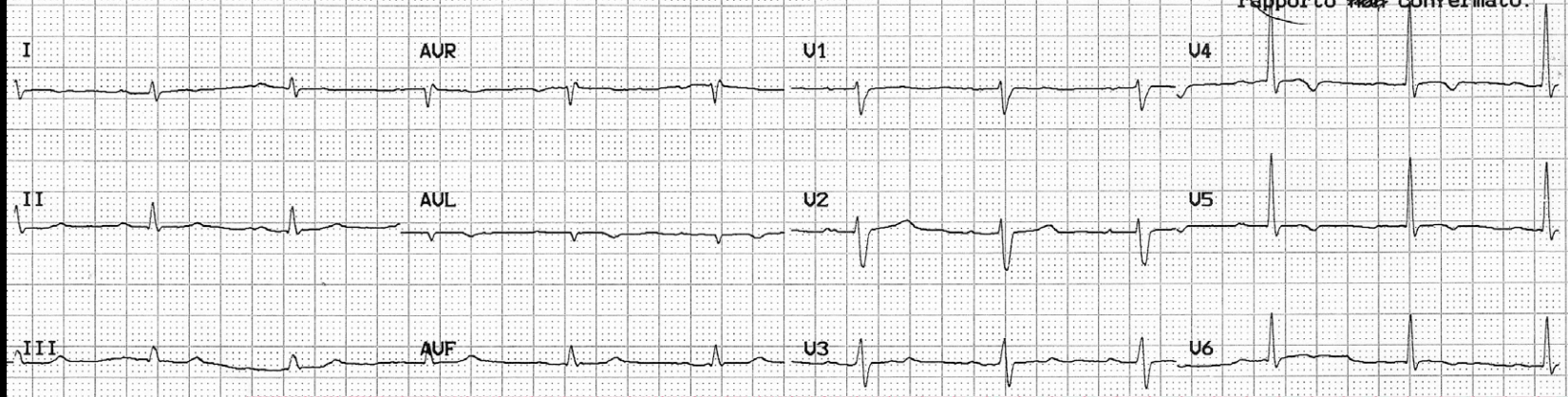
- **Molecular screening:**

Desmoplakin + 3 pt

Titin 1 pt

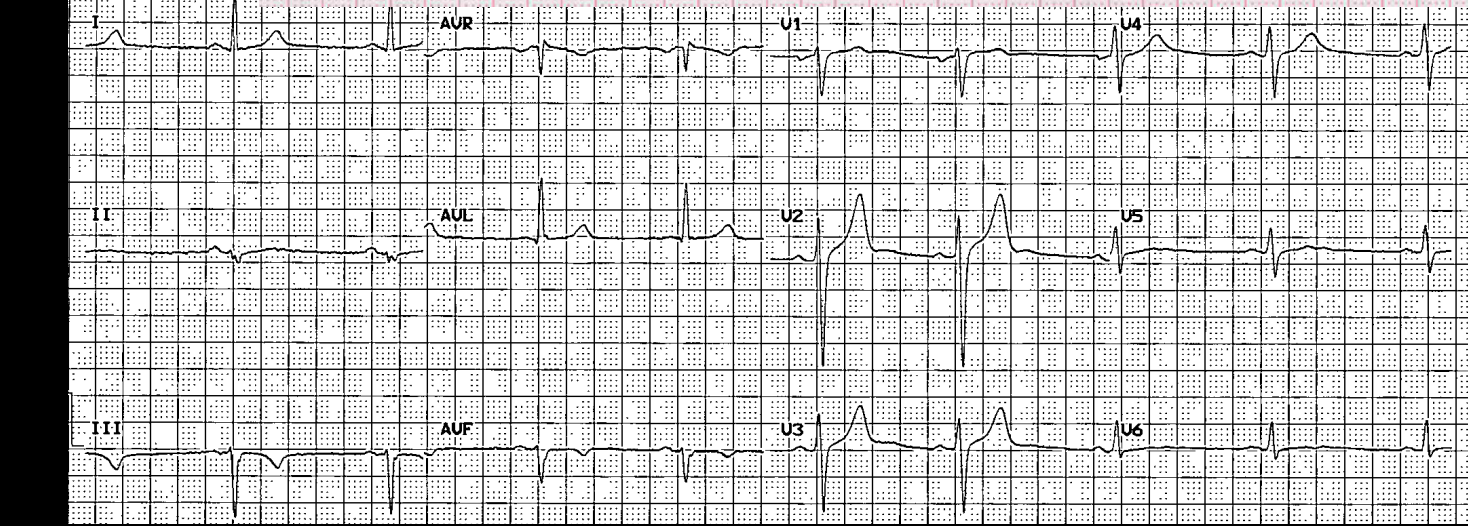
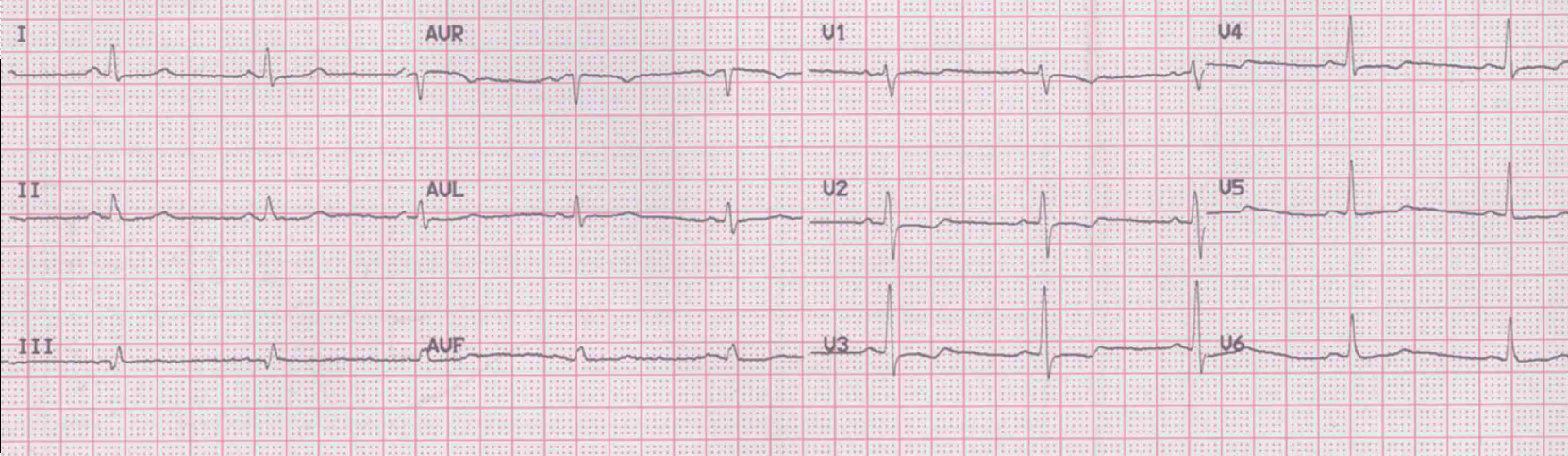
Negative 1 pt

Ongoing 7pt

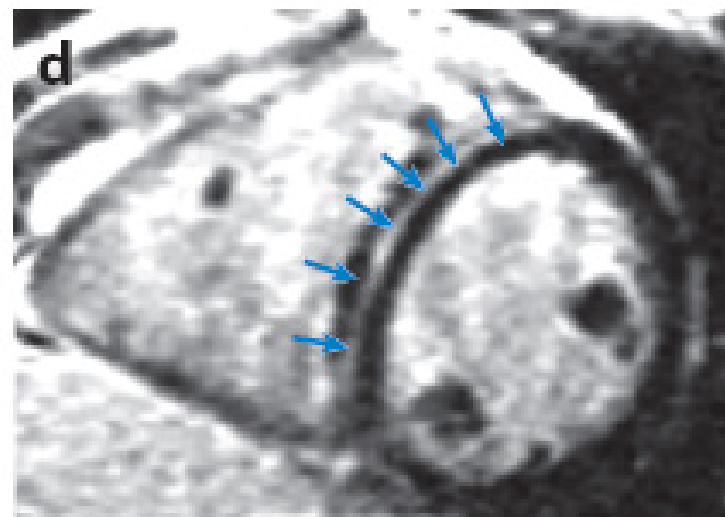
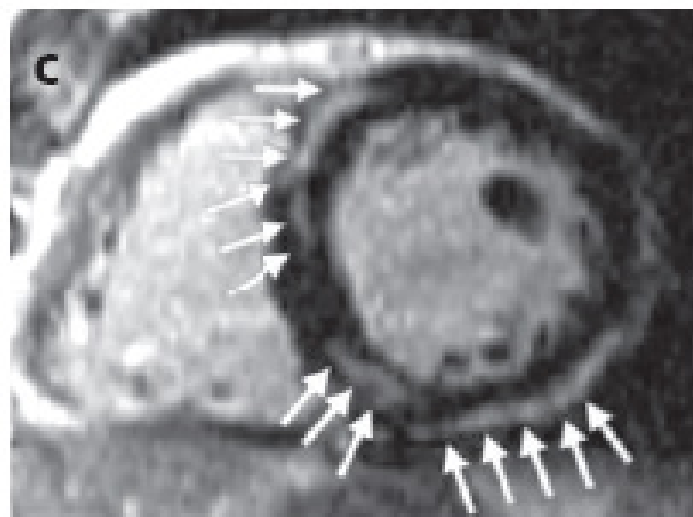
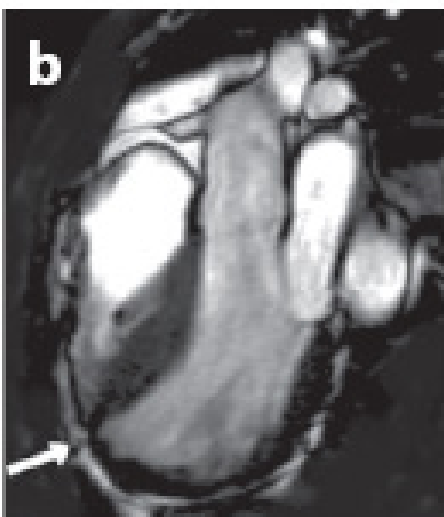
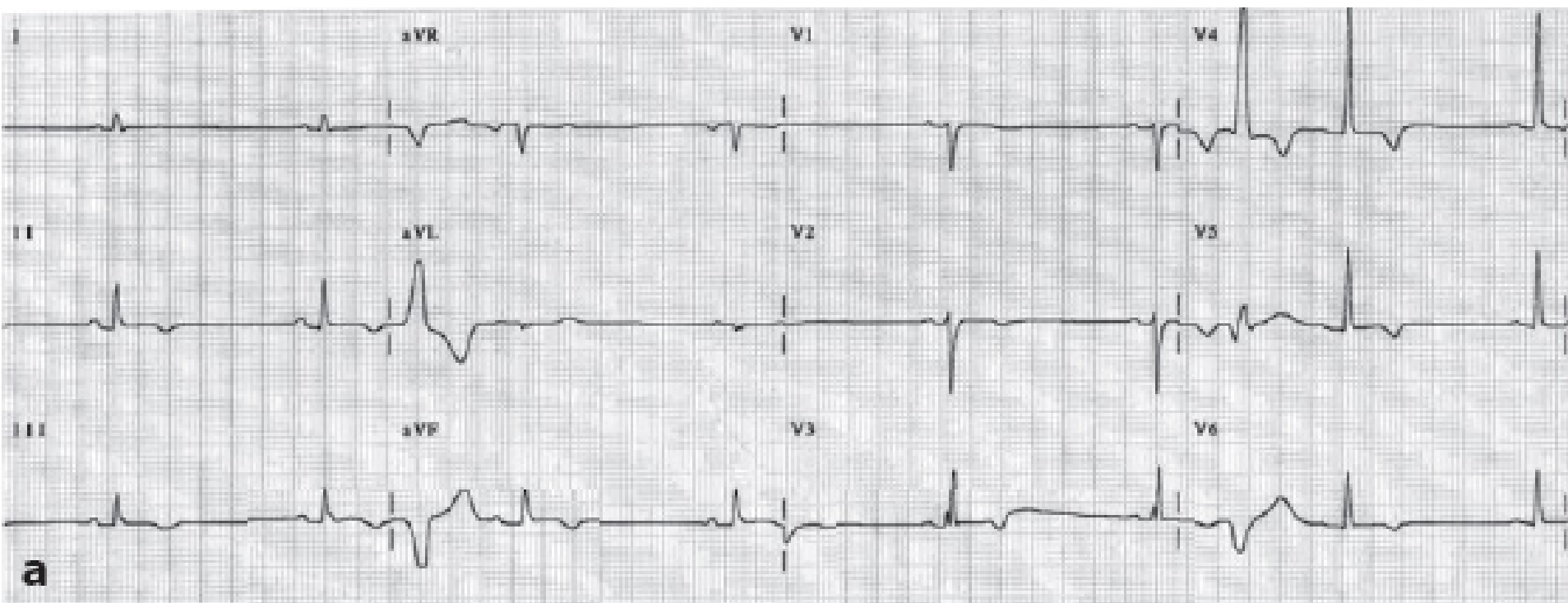


Pt 1


Pt 2



Pt 3



ARVC

- Phenotypic and genotypic spectrum wider than expected
- Risk of under- but also of over-diagnosis (cognitive error from excess of recent culture)
- Genetics clinically useful only for cascade family screening; **limited** role in identifying probands
- MRI useful mainly for morpho-functional definition and evaluation of myocardial LGE
- ALVC  true "challenge" for clinicians
- Don't forget standard ECG