

ADVANCES IN CARDIAC
ARRHYTHMIAS
and
GREAT INNOVATIONS
IN CARDIOLOGY

Directors

Fiorenzo Gaita
Sebastiano Marra

Scientific Committee

Malcolm R. Bell, *Usa*
Martin Borggrefe, *Germany*
Leonardo Calò, *Italy*
Jean François Leclercq, *France*
Amir Lerman, *Usa*
Dipen Shah, *Switzerland*

Organization Committee

Matteo Anselmino, *Italy*
Carlo Budano, *Italy*
Davide Castagno, *Italy*



Turin

October 13-15, 2016

Centro Congressi
Unione Industriale di Torino



II PATTERN DI BRUGADA
Giuseppe Oreto

The American Heart Journal

VOL. V

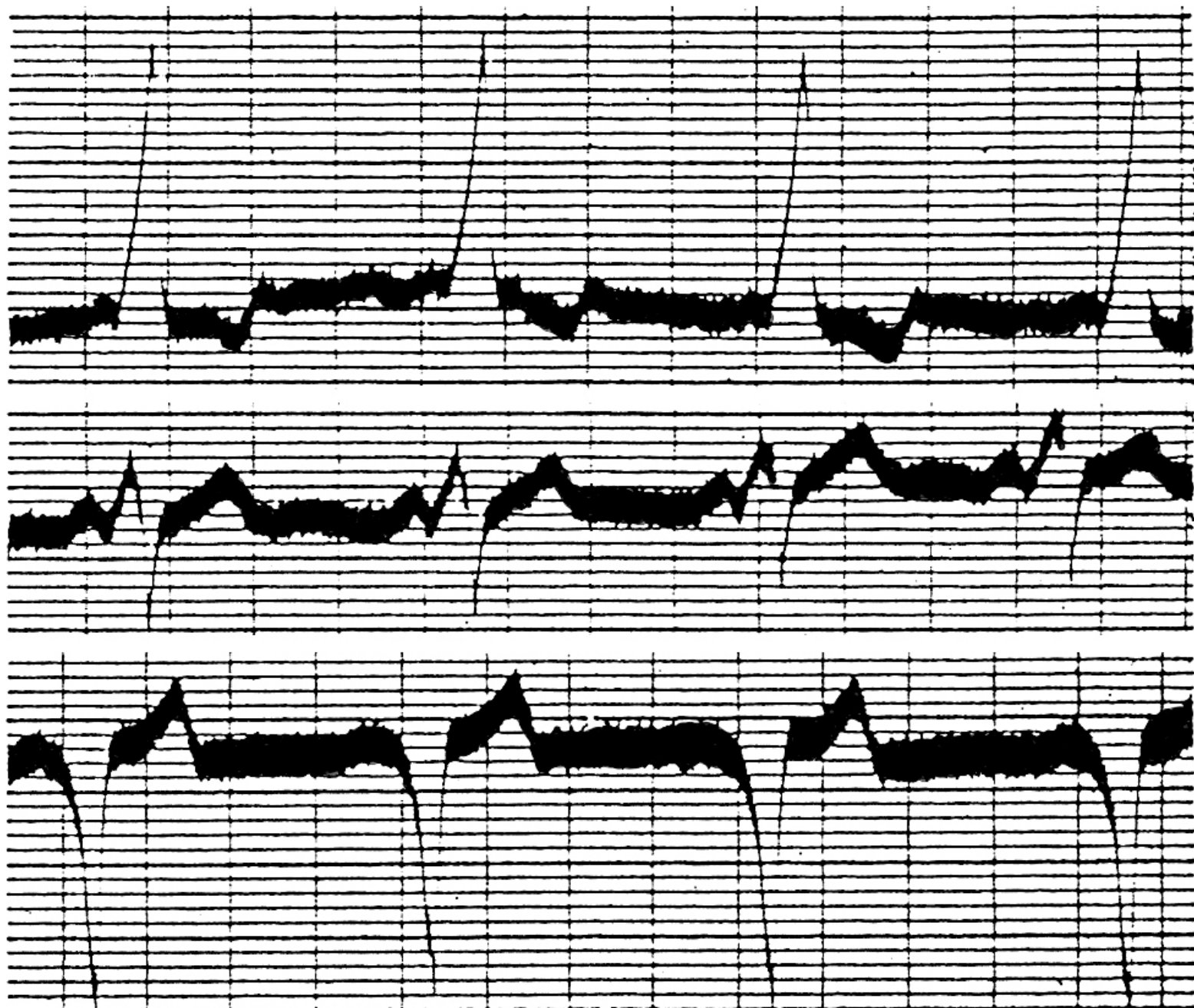AUGUST, 1930

No. 6

Original Communications

BUNDLE-BRANCH BLOCK WITH SHORT P-R INTERVAL
IN HEALTHY YOUNG PEOPLE PRONE TO
PAROXYSMAL TACHYCARDIA

LOUIS WOLFF, M.D., BOSTON, MASS., JOHN PARKINSON, M.D., LONDON,
ENG., AND PAUL D. WHITE, M.D., BOSTON, MASS.



I

II

III

Right Bundle Branch Block, Persistent ST Segment Elevation and Sudden Cardiac Death: A Distinct Clinical and Electrocardiographic Syndrome

A Multicenter Report

PEDRO BRUGADA, MD, JOSEP BRUGADA, MD*†

Aalst, Belgium and Barcelona, Spain

Objectives. The objectives of this study were to present data on eight patients with recurrent episodes of aborted sudden death unexplainable by currently known diseases whose common clinical and electrocardiographic (ECG) features define them as having a distinct syndrome different from idiopathic ventricular fibrillation.

Background. Among patients with ventricular arrhythmias who have no structural heart disease, several subgroups have been defined. The present patients constitute an additional subgroup with these findings.

Methods. The study group consisted of eight patients, six male and two female, with recurrent episodes of aborted sudden death. Clinical and laboratory data and results of electrocardiography, electrophysiology, echocardiography, angiography, histologic study and exercise testing were available in most cases.

Results. The ECG during sinus rhythm showed right bundle branch block, normal QT interval and persistent ST segment elevation in precordial leads V₁ to V₂-V₃ not explainable by electrolyte disturbances, ischemia or structural heart disease. No histologic abnormalities were found in the four patients in

whom ventricular biopsies were performed. The arrhythmia leading to (aborted) sudden death was a rapid polymorphic ventricular tachycardia initiating after a short coupled ventricular extrasystole. A similar arrhythmia was initiated by two to three ventricular extrastimuli in four of the seven patients studied by programmed electrical stimulation. Four patients had a prolonged HV interval during sinus rhythm. One patient receiving amiodarone died suddenly during implantation of a demand ventricular pacemaker. The arrhythmia of two patients was controlled with a beta-adrenergic blocking agent. Four patients received an implantable defibrillator that was subsequently used by one of them, and all four are alive. The remaining patient received a demand ventricular pacemaker and his arrhythmia is controlled with amiodarone and diphenylhydantoin.

Conclusions. Common clinical and ECG features define a distinct syndrome in this group of patients. Its causes remain unknown.

(J Am Coll Cardiol 1992;20:1391-6)

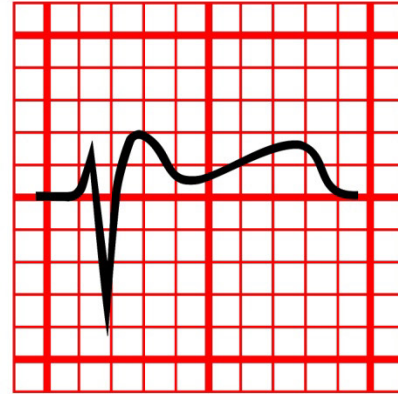
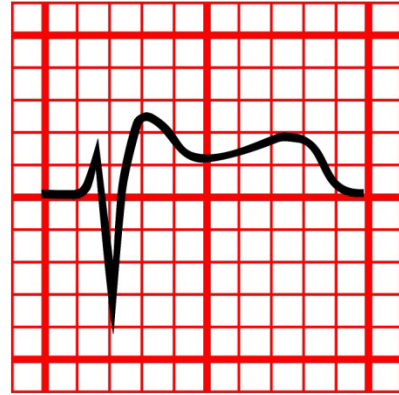
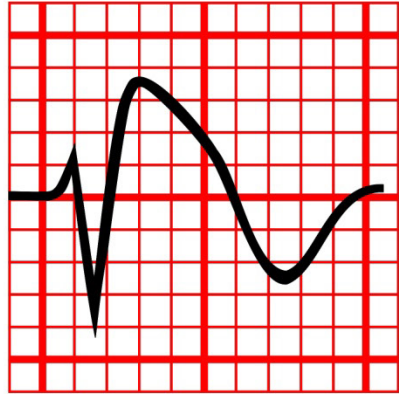
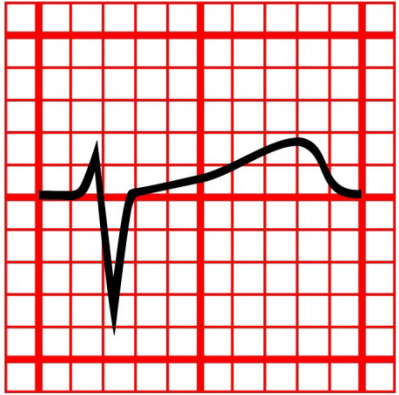
Dubbi del cardiologo davanti ad un elettrocardiogramma che presenta in V1-V3 complessi QRS con onda positiva terminale e soprasslivellamento del segmento ST

Consensus Conference promossa dalla Società Italiana di Cardiologia

Giuseppe Oreto¹, Domenico Corrado², Pietro Delise³, Francesco Fedele⁴, Fiorenzo Gaita⁵, Federico Gentile⁶, Carla Giustetto⁵, Antonio Michelucci⁷, Luigi Padeletti⁷, Silvia Priori⁸

¹Dipartimento di Medicina e Farmacologia, Università degli Studi, Messina, ²Dipartimento di Scienze Cardiovascolari e Toraciche, Università degli Studi, Padova, ³Divisione di Cardiologia, Ospedale Civile, Conegliano Veneto (TV), ⁴Dipartimento di Scienze Cardiovascolari, Respiratorie, Nefrologiche e Geriatriche, Università degli Studi "La Sapienza", Roma, ⁵Dipartimento di Medicina, Università degli Studi, Torino, ⁶Centro Medico Diagnostico, Napoli, ⁷Istituto di Clinica Medica e Cardiologia, Università degli Studi, Firenze, ⁸Dipartimento di Cardiologia, Fondazione Salvatore Maugeri, Università degli Studi, Pavia

When an ECG shows (or is suspicious for) a Brugada pattern, i.e. the association of a positive terminal deflection and ST segment elevation in the right precordial leads, the cardiologist often faces several problems. Three important questions are raised by this ECG pattern: 1) is this really a Brugada ECG pattern? 2) How can be determined whether this patient is at risk for sudden death? and 3) Should this patient receive an implantable cardioverter-defibrillator (ICD)? The term "Brugada syndrome" should be restricted to patients who have diagnostic ECG changes,



Normale

tipo 1

tipo 2

tipo 3



ELSEVIER

Available online at www.sciencedirect.com

SciVerse ScienceDirect

Journal of Electrocardiology 45 (2012) 433–442

JOURNAL OF
Electrocardiology

www.jecgonline.com

Current electrocardiographic criteria for diagnosis of Brugada pattern: a consensus report[☆]

Antonio Bayés de Luna, MD, PhD,^{a,*} Josep Brugada, MD, PhD,^b Adrian Baranchuk, MD,^c
Martin Borggrefe, MD,^d Guenter Breithardt, MD,^e Diego Goldwasser, MD,^a
Pier Lambiase, MD,^f Andrés Pérez Riera, MD, PhD,^g Javier Garcia-Niebla, RN,^h
Carlos Pastore, MD, PhD,ⁱ Giuseppe Oreto, MD,^j William McKenna, MD,^f
Wojciech Zareba, MD, PhD,^k Ramon Brugada, MD, PhD,^l Pedro Brugada, MD, PhD^m

^a*Institut Català Ciències Cardiovasculars–Hospital Sant Pau, Barcelona, Spain*

^b*Hospital Clínico, Barcelona, Spain*

^c*Kingston General Hospital, Kingston, Canada*

^d*Universitätsmedizin Mannheim-I. Medizinische Klinik, Mannheim, Germany*

^e*Med.Klinik & Poliklinik, Universität Münster, Münster, Germany*

^f*Heart Hospital, UCL, London, UK*

^g*Facultad de Medicina del ABC-Santo André, Sao Paulo, Brasil*

^h*Canary Islands, Spain*

ⁱ*Instituto do Coração, Sao Paulo, Brasil*

^j*Universita de Messina, Messina, Italy*

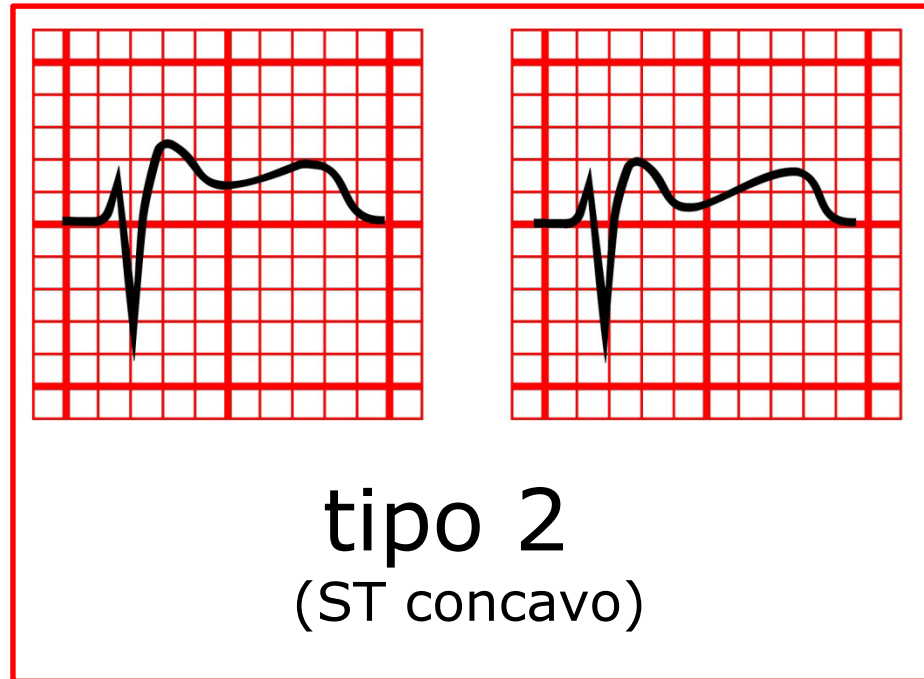
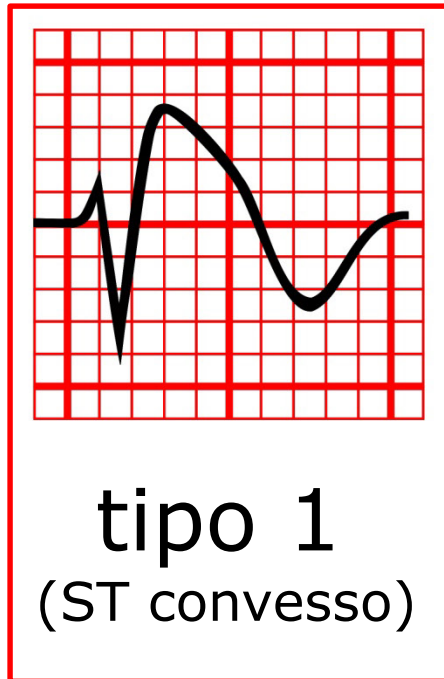
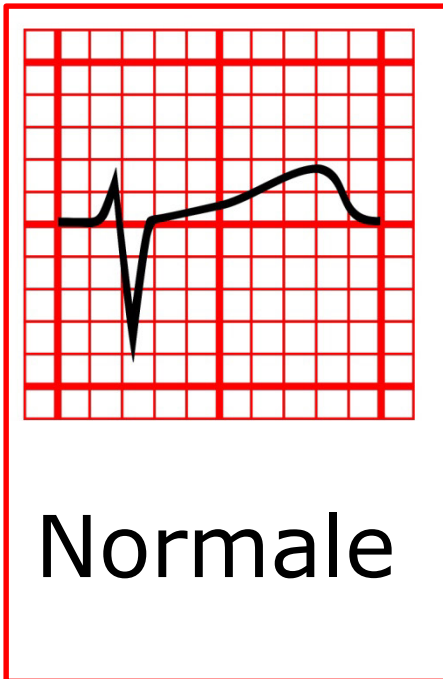
^k*University of Rochester Medical Center, Rochester, NY, USA*

^l*Cardiovascular Genetic Center UdG-IDIBGI, Girona, Spain*

^m*Free University of Brussels (UZ Brussel) VUB, Brussels, Belgium*

Received 20 March 2012

Bayes de Luna et al: Current Electrocardiographic criteria for diagnosis of Brugada pattern: a consensus document. *J Electrocardiol*, 2012;45:433-442



PROBLEMI CON IL PATTERN DI BRUGADA

- ✓ Solo il tipo 1 è diagnostico
- ✓ Il tipo 2 è "innocente"?
- ✓ Il quadro ECG è ampiamente variabile, da un tracciato normale al più ovvio pattern tipo 1
- ✓ ECG simili a quello dal pattern di Brugada si osservano in diverse condizioni
- ✓ Il rischio di sovrastimare o sottovalutare il quadro è elevato

BRUGADA SYNDROME VERSUS BRUGADA PATTERN

In the presence of ECG criteria of Brugada pattern, Brugada Syndrome is diagnosed if one/more of the following clinical factors are present:

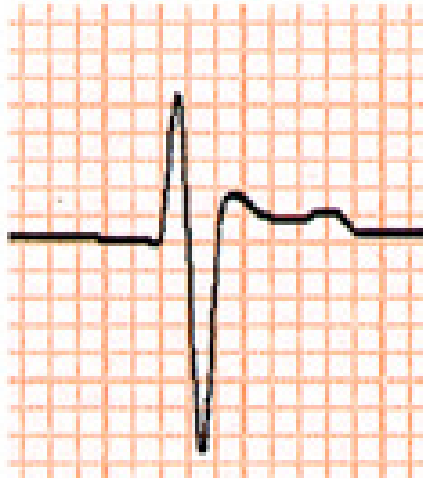
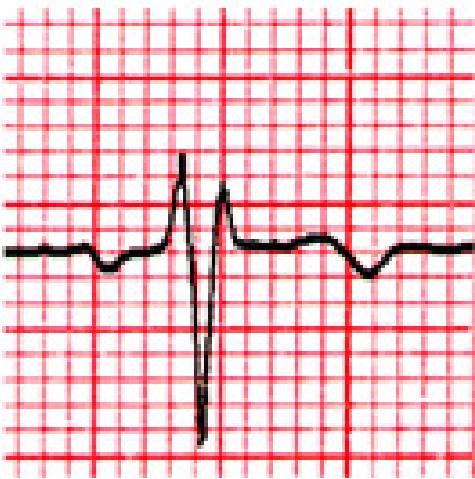

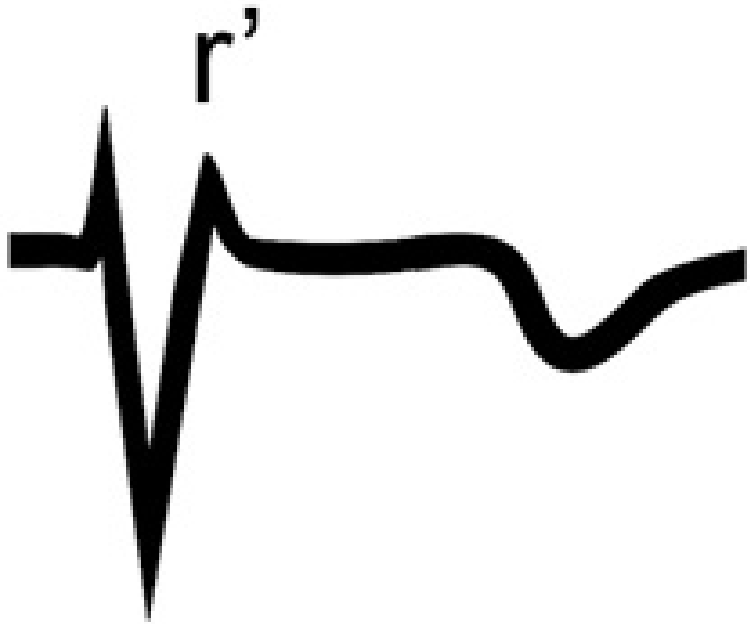
- a) Survivors of cardiac arrest
- b) Presence of polymorphic ventricular tachycardia
- c) History of nonvagal syncope
- d) Familial antecedents of sudden death in patients younger than 45 years without acute coronary syndrome
- e) Type 1 Brugada pattern in relatives.

QUADRI ECG CHE SIMULANO IL PATTERN DI BRUGADA

- ✓ Blocco di branca destra
- ✓ Ripolarizzazione precoce
- ✓ Ischemia miocardica transmurale
- ✓ Pericardite
- ✓ Ipotermia
- ✓ Compressione sul tratto di efflusso del VD
- ✓ Iperkaliemia
- ✓ Ipercalcemia
- ✓ Embolia polmonare
- ✓ Effetto di Farmaci
- ✓ Elettrocardiografo con filtri scorretti

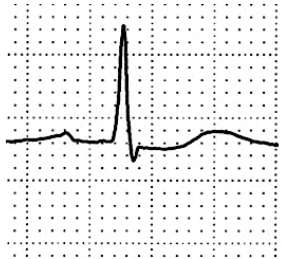QUADRI ECG CHE SIMULANO IL PATTERN DI BRUGADA

- ✓ **Blocco di branca destra**
- ✓ Ripolarizzazione precoce
- ✓ Ischemia miocardica transmurale
- ✓ Pericardite
- ✓ Ipotermia
- ✓ Compressione sul tratto di efflusso del VD
- ✓ Iperkaliemia
- ✓ Ipercalcemia
- ✓ Embolia polmonare
- ✓ Effetto di Farmaci
- ✓ Elettrocardiografo con filtri scorretti

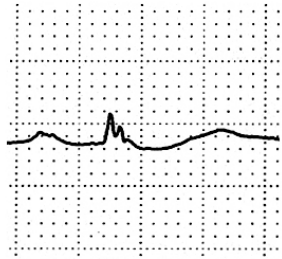


QUADRI ECG CHE SIMULANO IL PATTERN DI BRUGADA

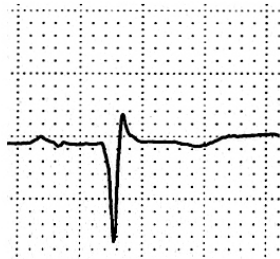
- ✓ Blocco di branca destra
- ✓ Ripolarizzazione precoce
- ✓ **Ischemia miocardica transmurale**
- ✓ Pericardite
- ✓ Ipotermia
- ✓ Compressione sul tratto di efflusso del VD
- ✓ Iperkaliemia
- ✓ Ipercalcemia
- ✓ Embolia polmonare
- ✓ Effetto di Farmaci
- ✓ Elettrocardiografo con filtri scorretti



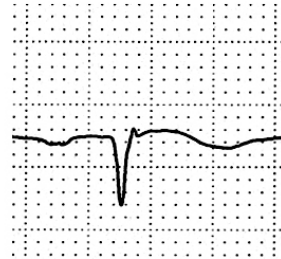
I



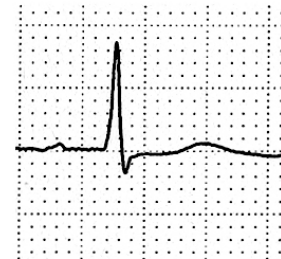II



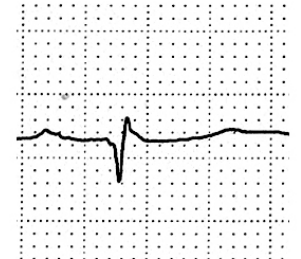
III



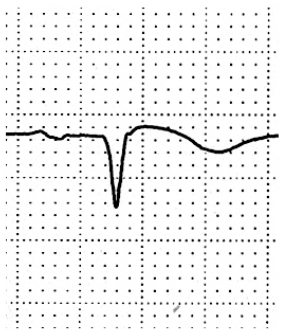
aVR



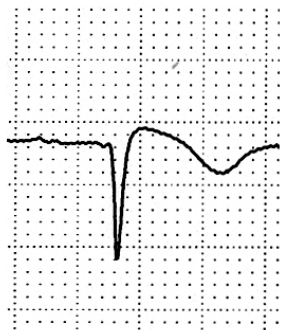aVL



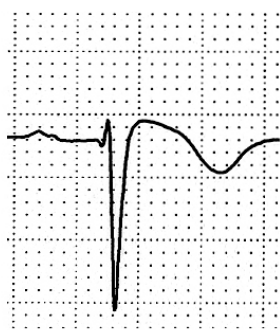aVF



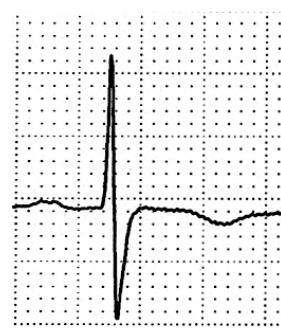V1



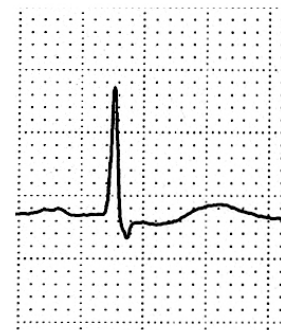V2



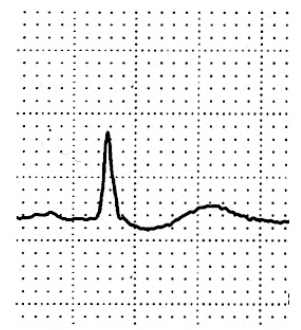
V3



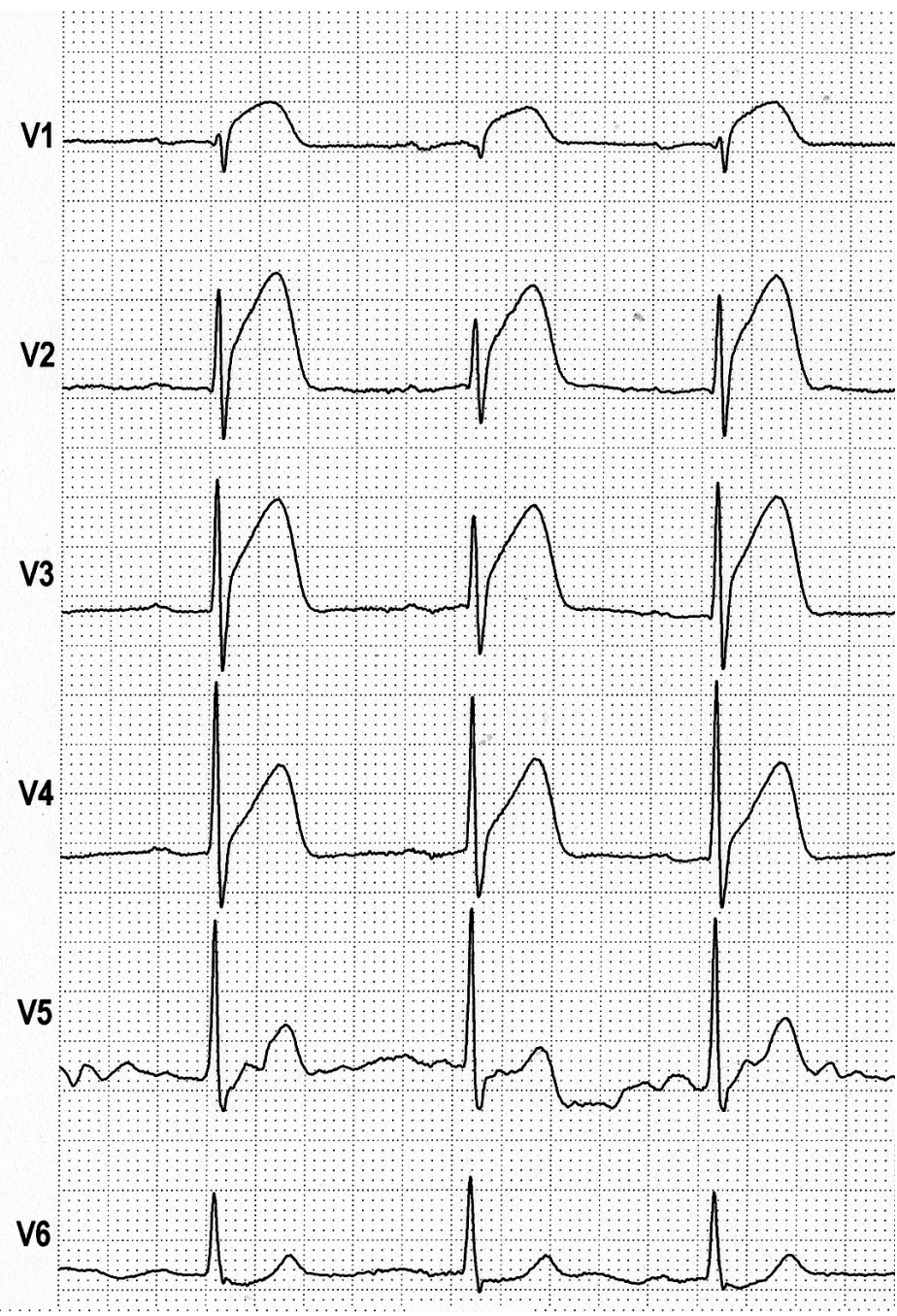
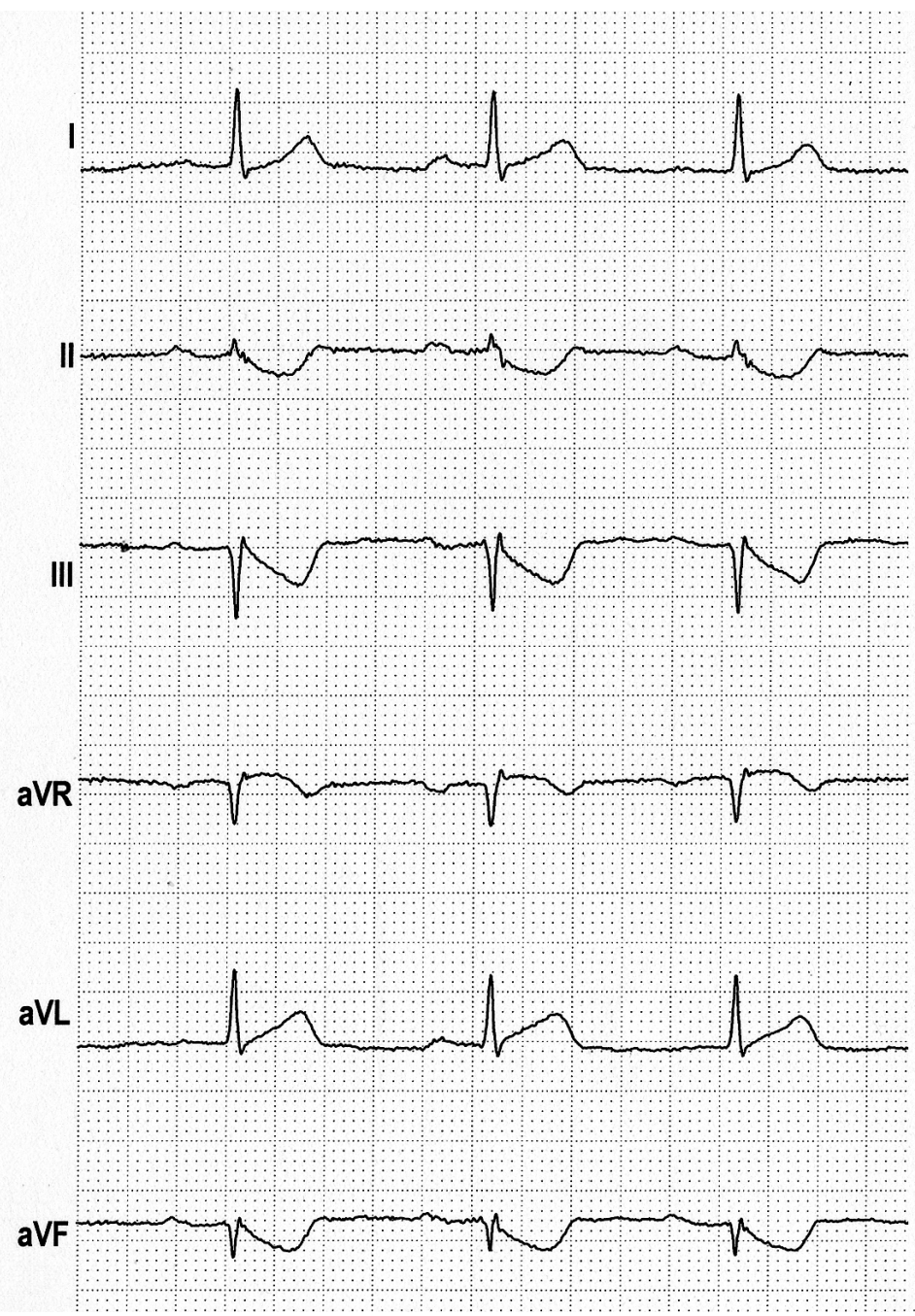
V4



V5



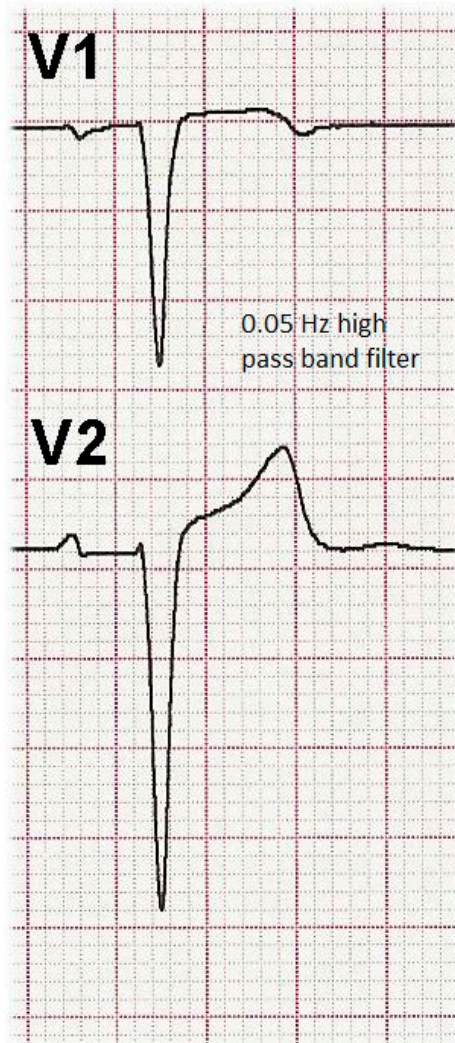
V5



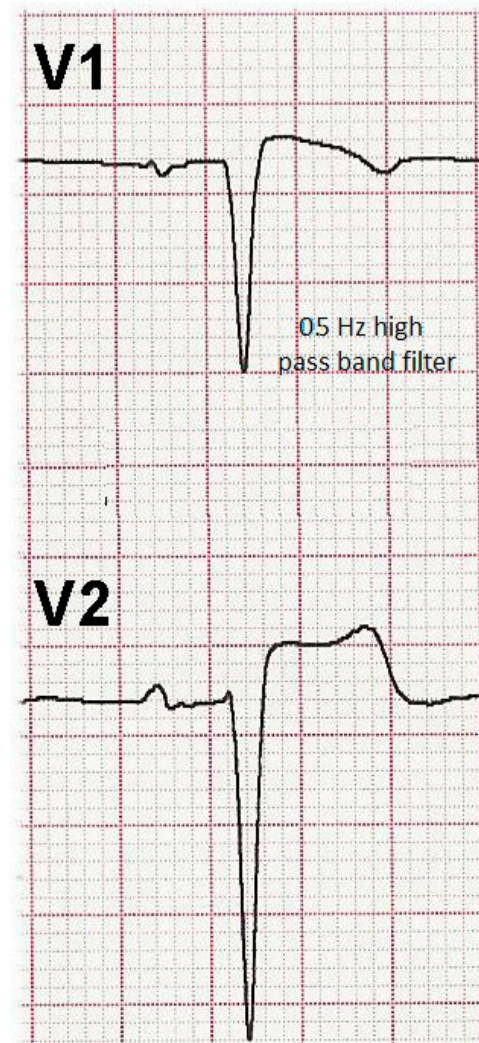
QUADRI ECG CHE SIMULANO IL PATTERN DI BRUGADA

- ✓ Blocco di branca destra
- ✓ Ripolarizzazione precoce
- ✓ Ischemia miocardica transmurale
- ✓ Pericardite
- ✓ Ipotermia
- ✓ Compressione sul tratto di efflusso del VD
- ✓ Iperkaliemia
- ✓ Ipercalcemia
- ✓ Embolia polmonare
- ✓ Effetto di Farmaci
- ✓ **Elettrocardiografo con filtri scorretti**

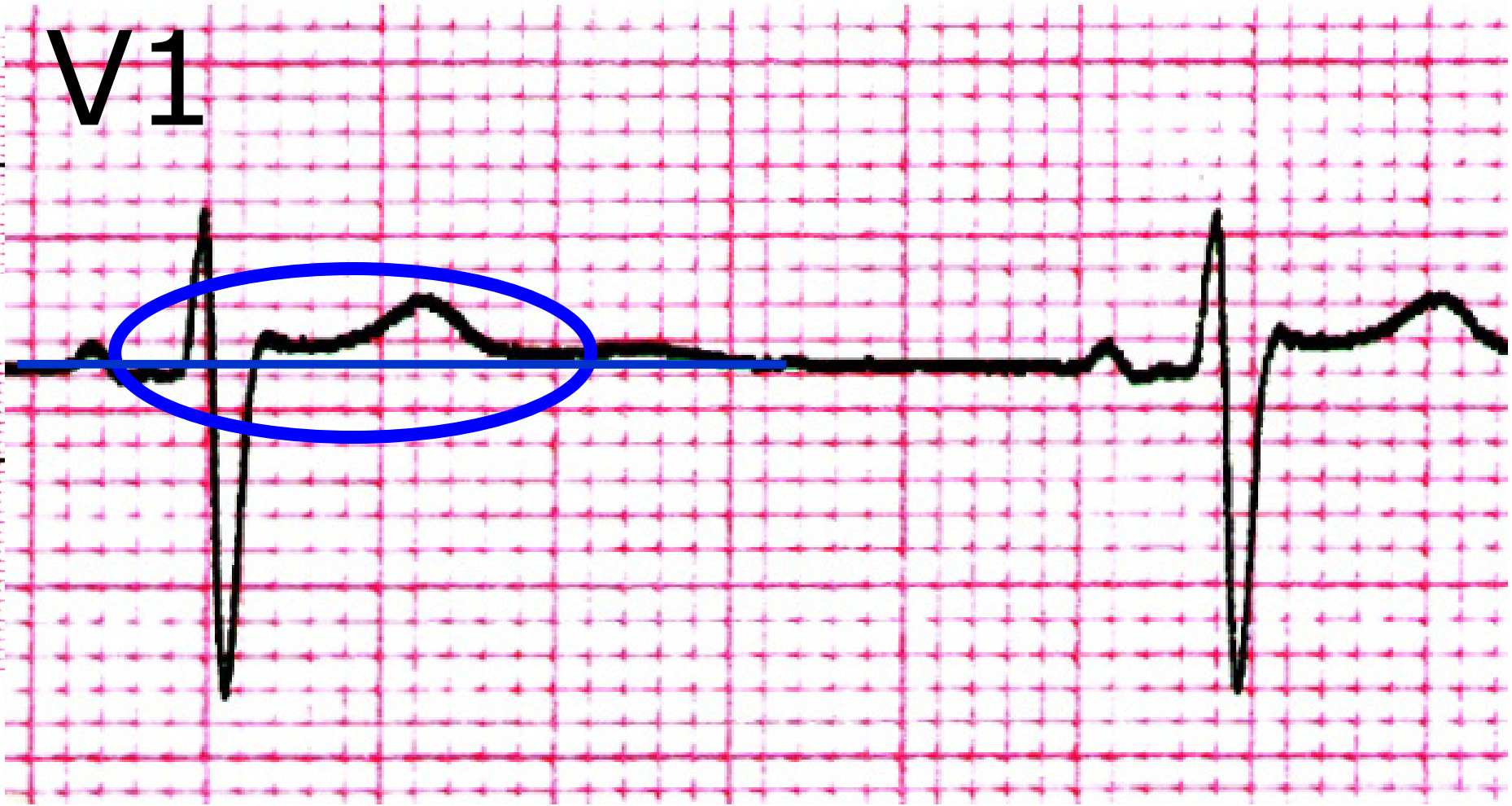0.05 Hz high pass band filter

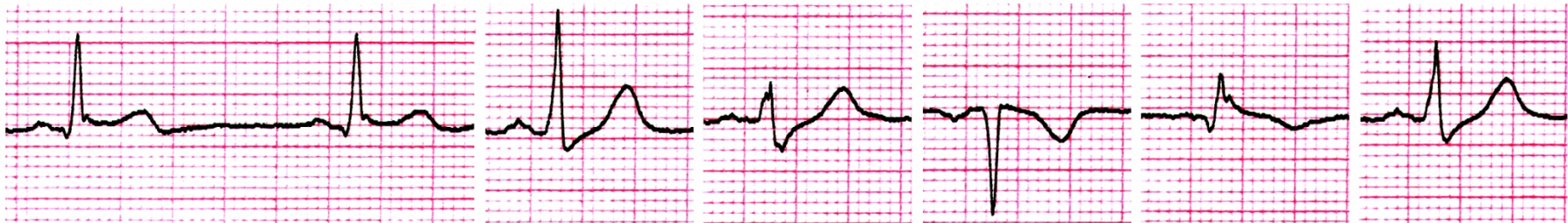

0.5 Hz high pass band filter

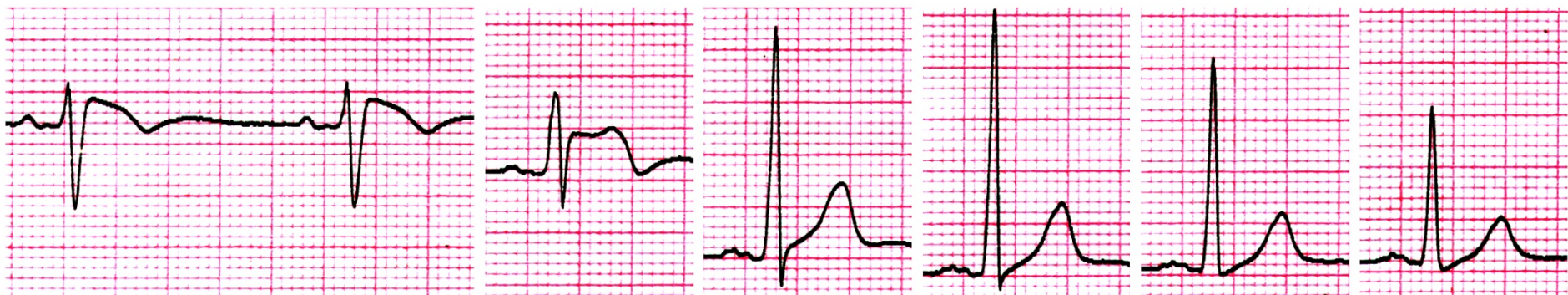

V1

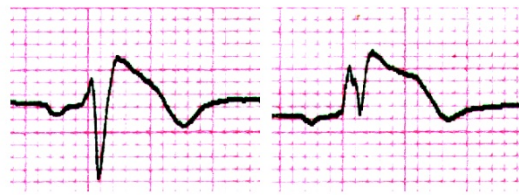




I II III aVR aVL aVF



V1 V2 V3 V4 V5 V6



V1^{3°sp} V2^{3°sp}

Dopo Ajmalina

ANALISI DELL'ECG IN PRESENZA DI ONDA POSITIVA TERMINALE IN V1-V2

Valutare:

- ✓ Le derivazioni V1-V3 al 3° e 2° spazio
- ✓ La morfologia dell'onda positiva terminale
- ✓ La durata dell'onda positiva terminale
- ✓ La durata del QRS in V1-V2 paragonata a quella rilevata in V6
- ✓ Il sottoslivellamento di ST in II, III, aVF

ANALISI DELL'ECG IN PRESENZA DI ONDA POSITIVA TERMINALE IN V1-V2

Valutare:

- ✓ Le derivazioni V1-V3 al 3° e 2° spazio
- ✓ La morfologia dell'onda positiva terminale
- ✓ La durata dell'onda positiva terminale
- ✓ La durata del QRS in V1-V2 paragonata a quella rilevata in V6
- ✓ Il sottoslivellamento di ST in II, III, aVF

4° spazio

3° spazio

2° spazio

5° spazio

I

aVR

V1



II

aVL

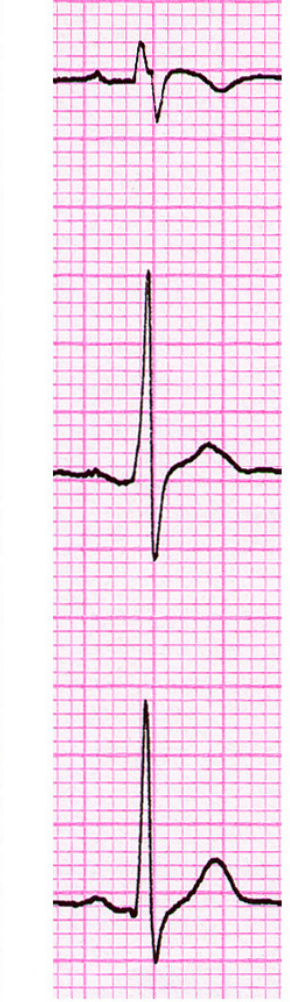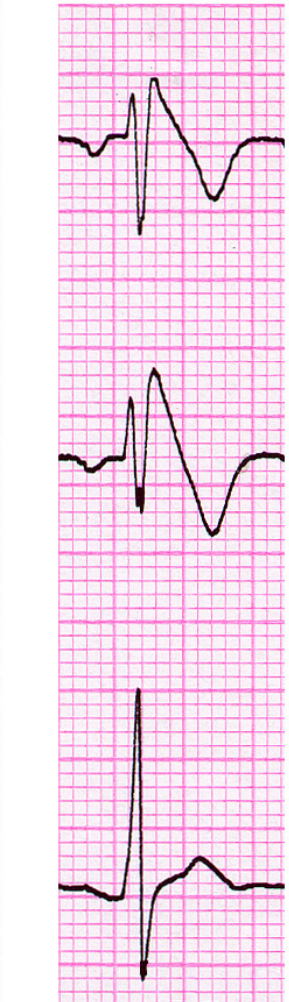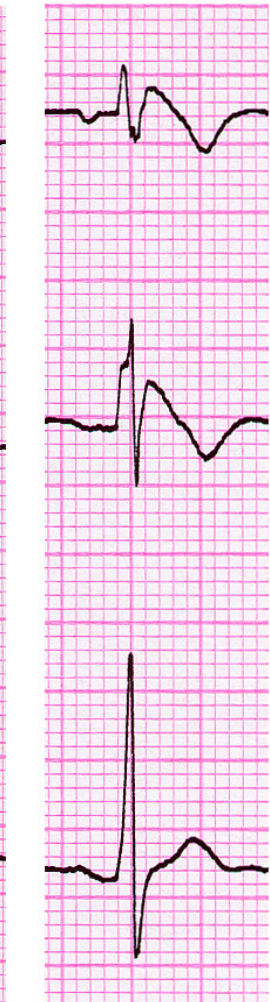
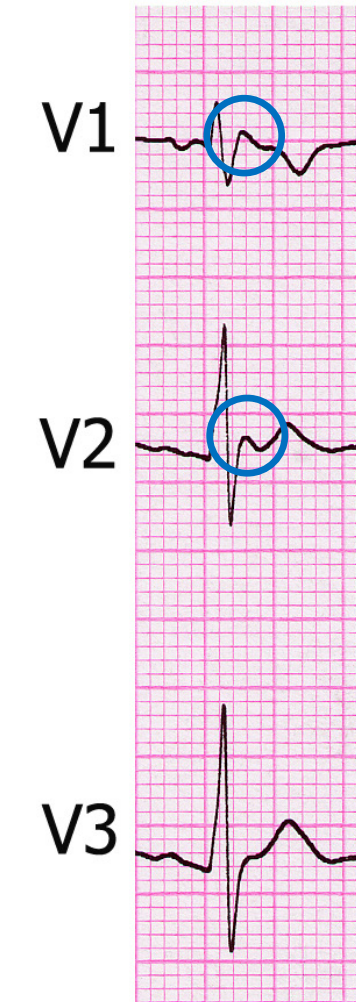
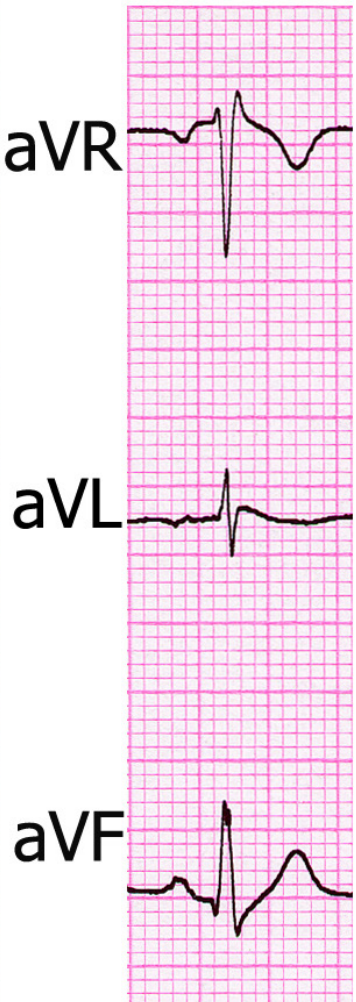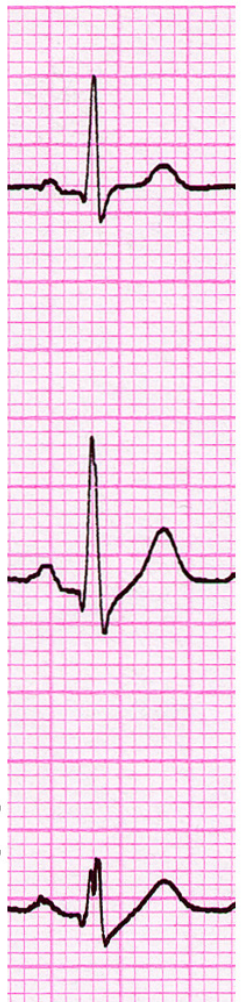V2

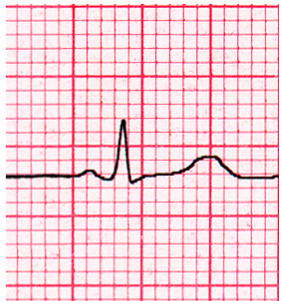


III

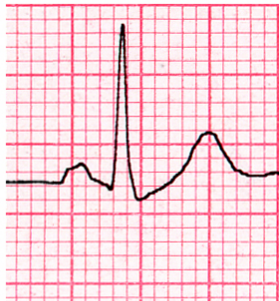aVF

V3

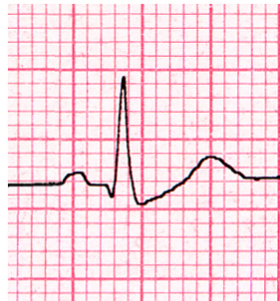



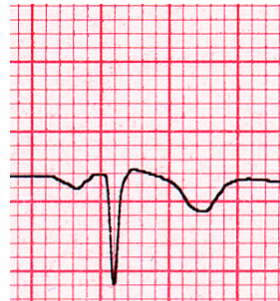
I



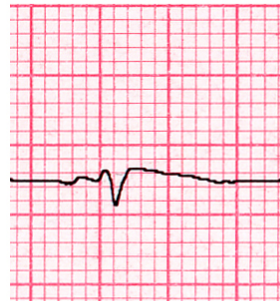
II



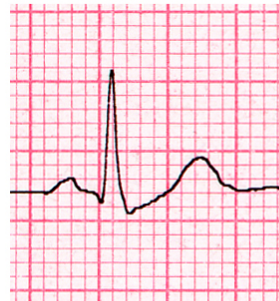III



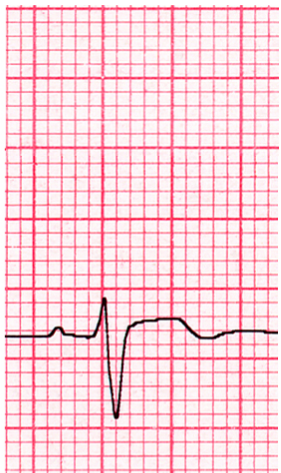
aVR



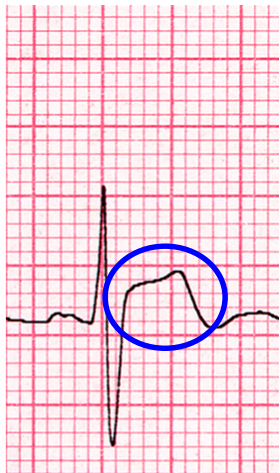aVL



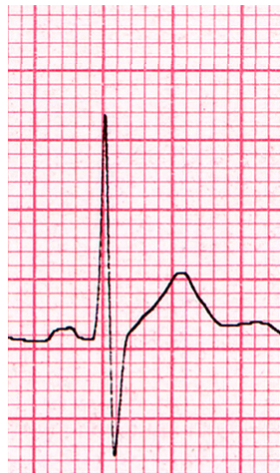aVF



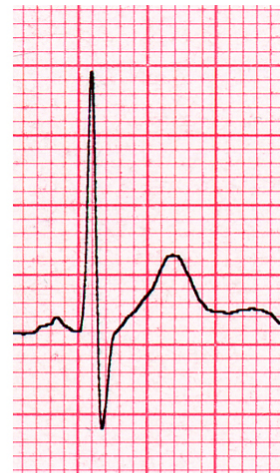V1



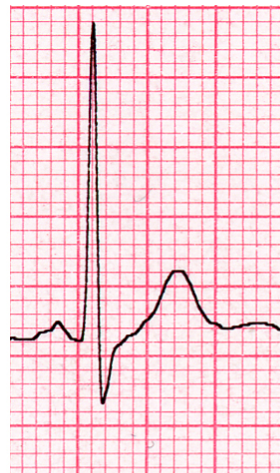V2



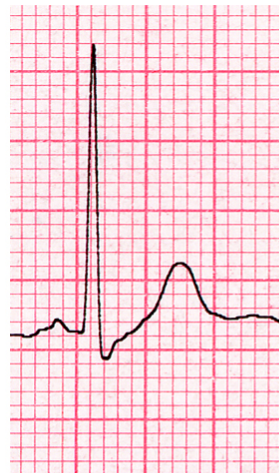V3



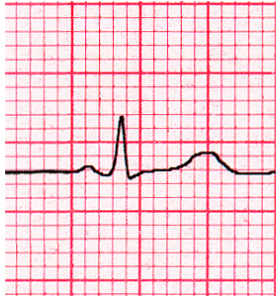
V4



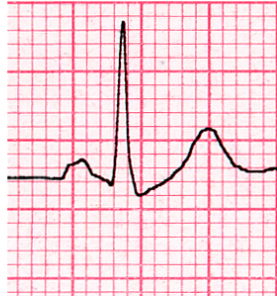V5



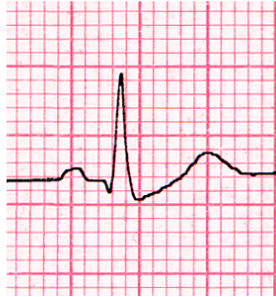
V6



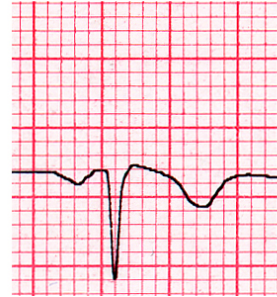I



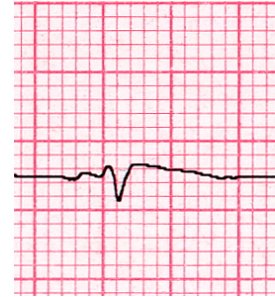
II



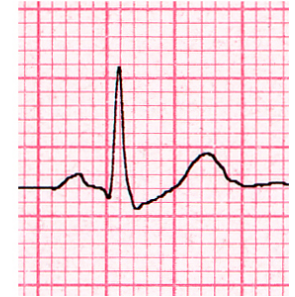III



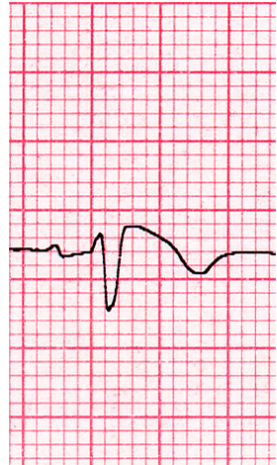
aVR



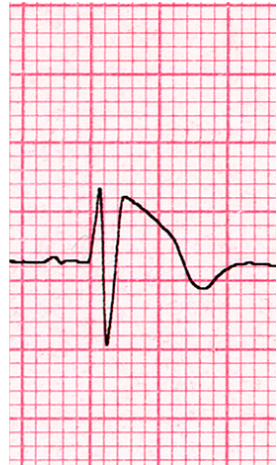aVL



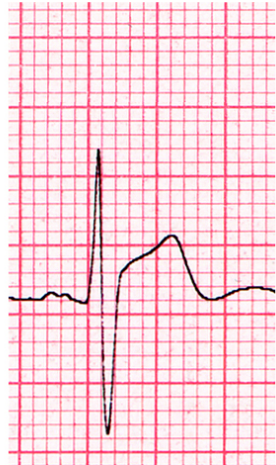aVF



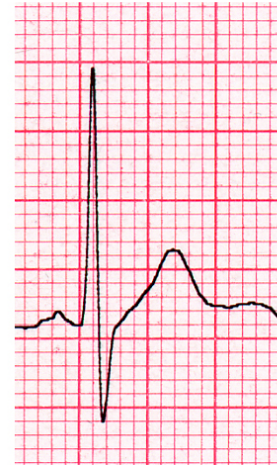V1
3rd i.s.



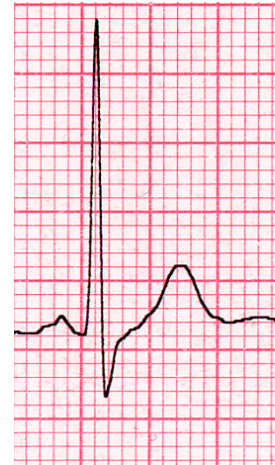V2
3rd i.s.



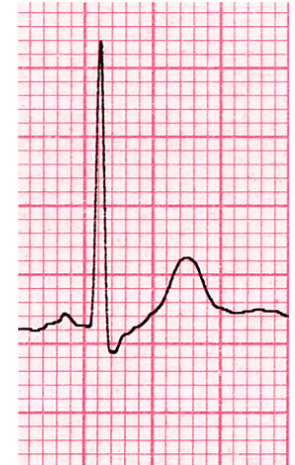V3
3rd i.s.



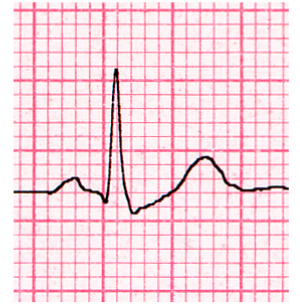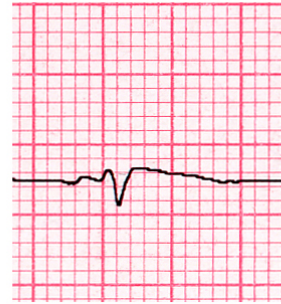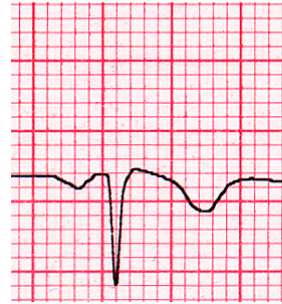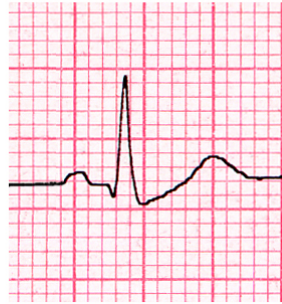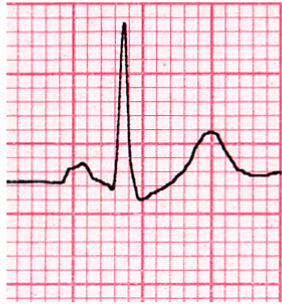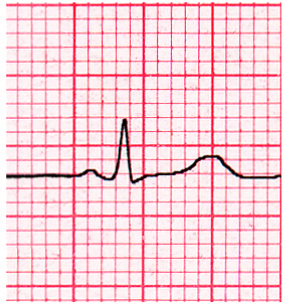
V4



V5



V6



I

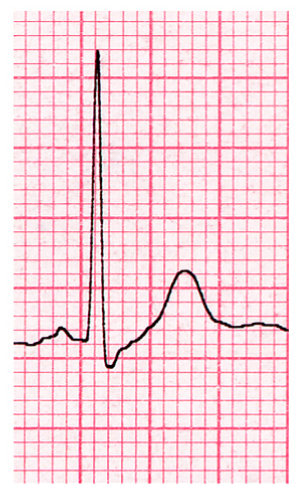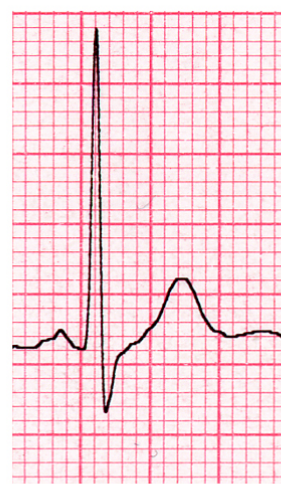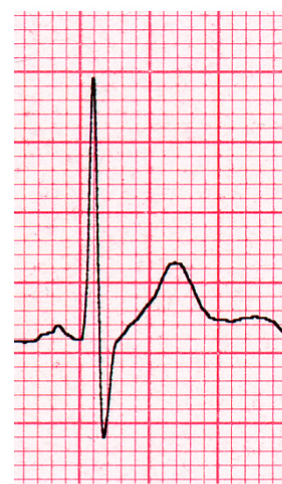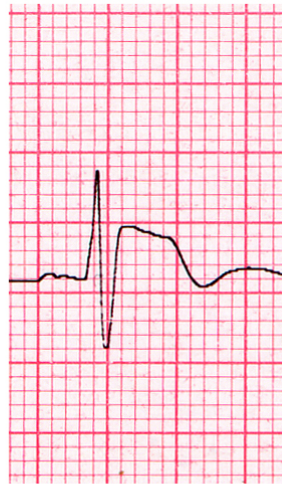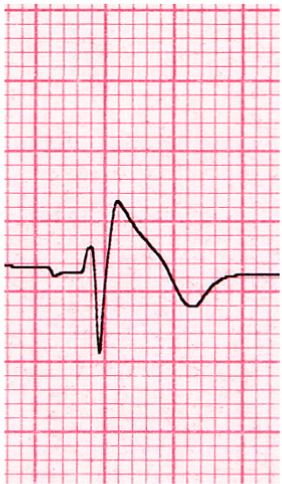
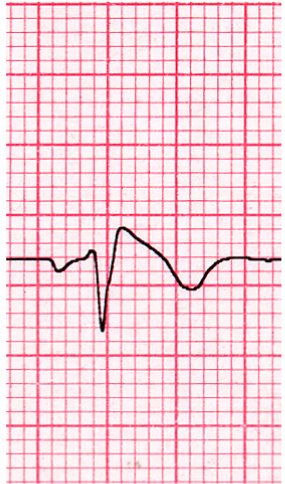
II

III

aVR

aVL

aVF



V1

2nd i.s.

V2

2nd i.s.

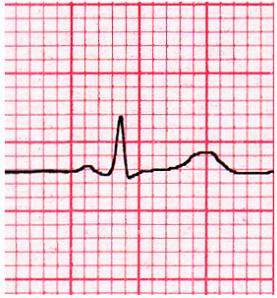
V3

2nd i.s.

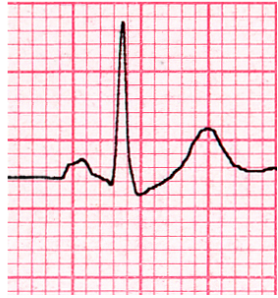
V4

V5

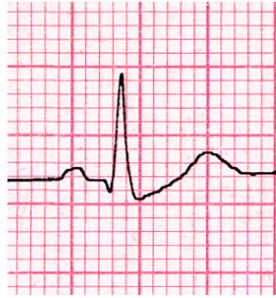
V6



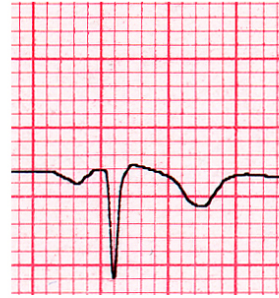I



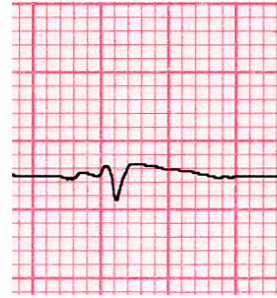
II



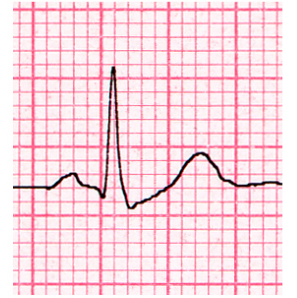
III



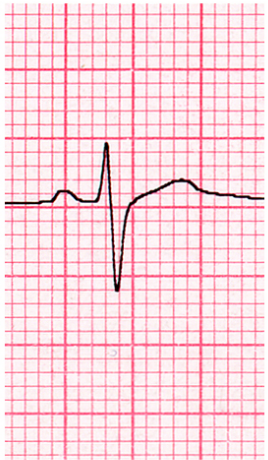
aVR



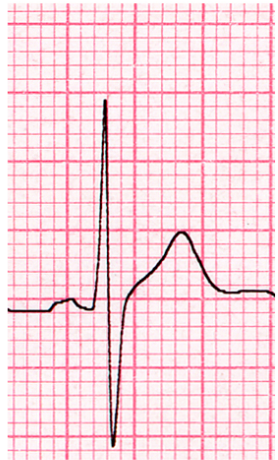
aVL



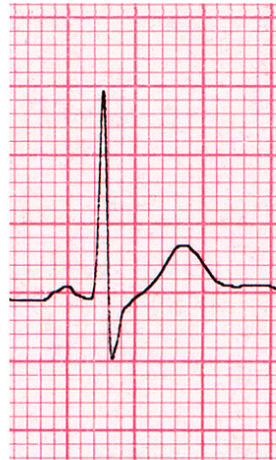aVF



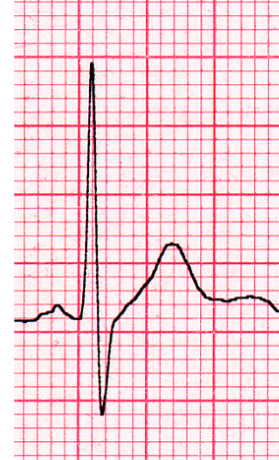V1
5th i.s.



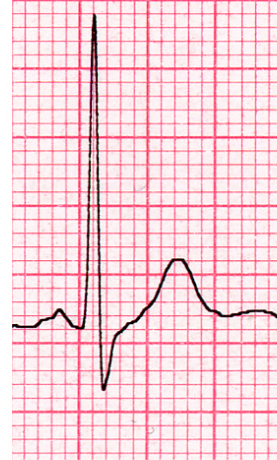V2
5th i.s.



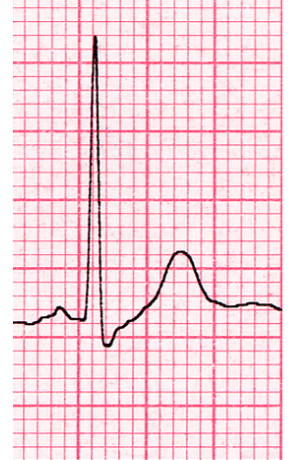
V3
5th i.s.



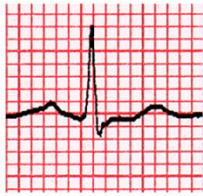V4



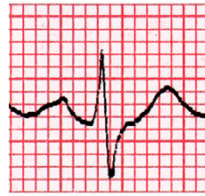V5



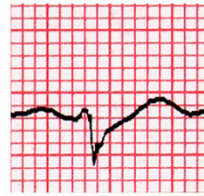
V6



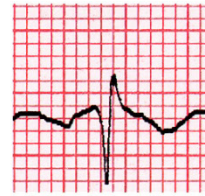
I



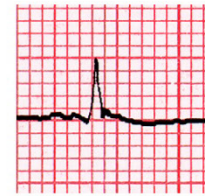II



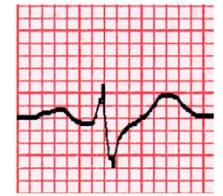
III



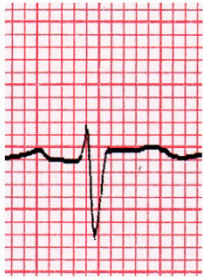aVR



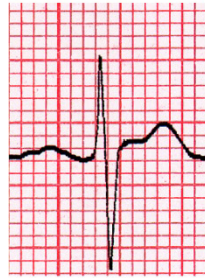aVL



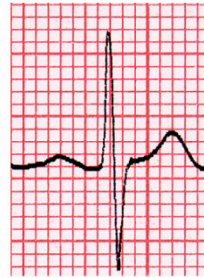aVF



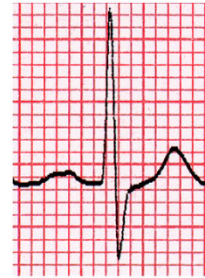V1



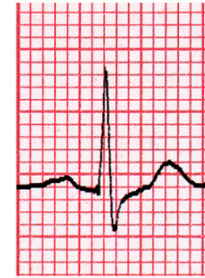V2



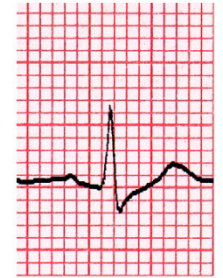V3



V4

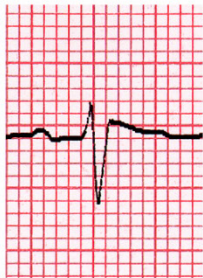

V5

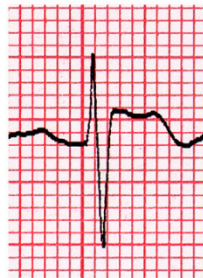

V6

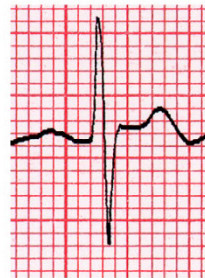3rd
i.s.



V1

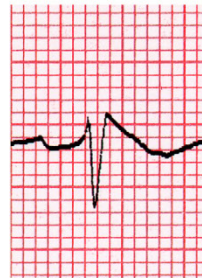

V2

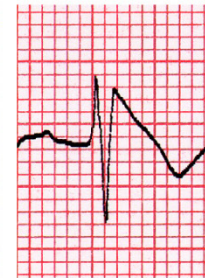

V3

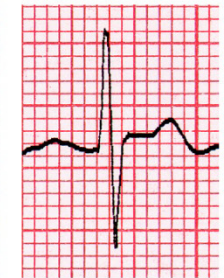
2nd
i.s.



V1

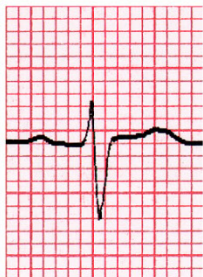

V2

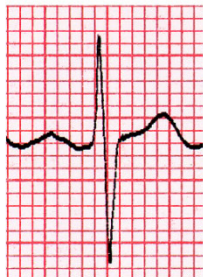

V3

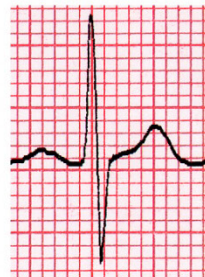5th
i.s.



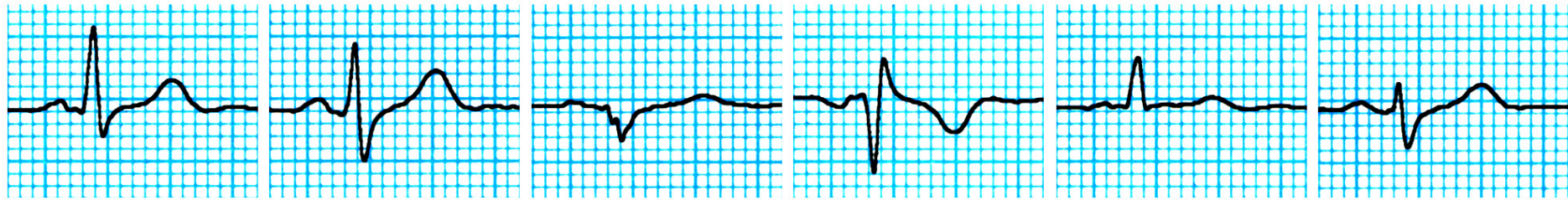
V1



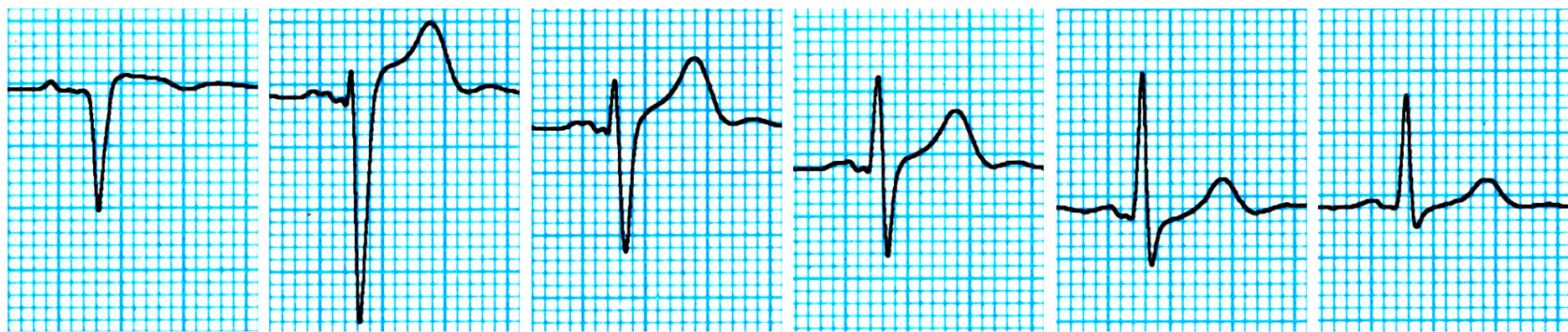
V2



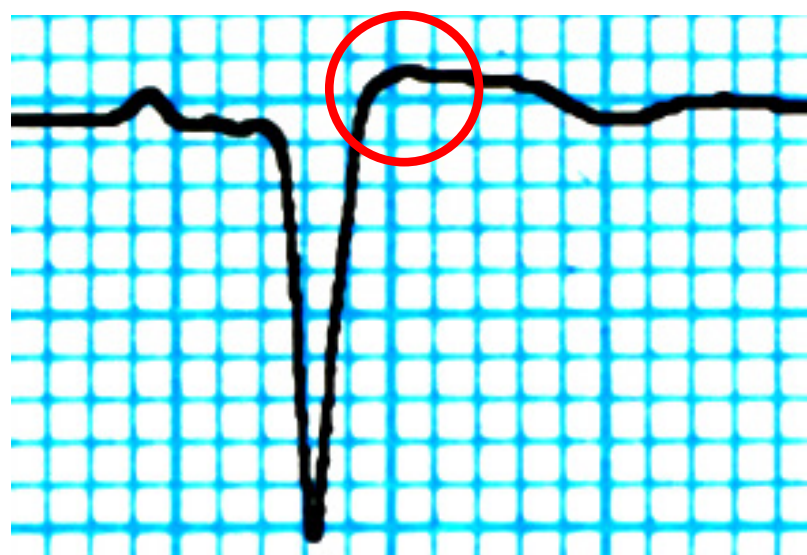V3

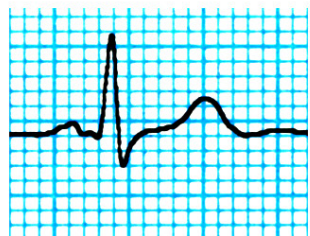


I II III aVR aVL aVF

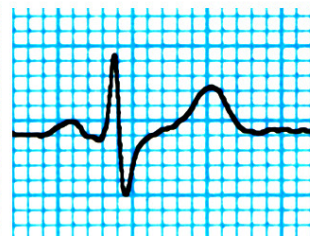


V1 V2 V3 V4 V5 V6

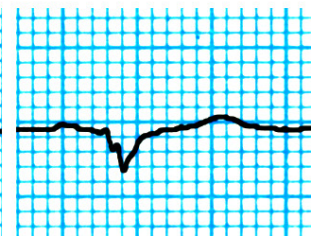




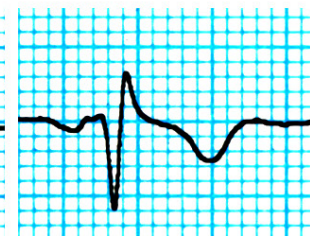I



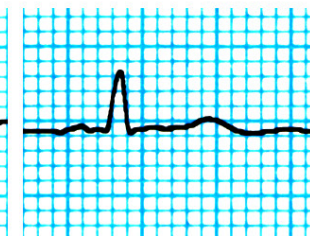
II



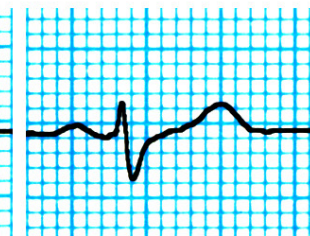
III



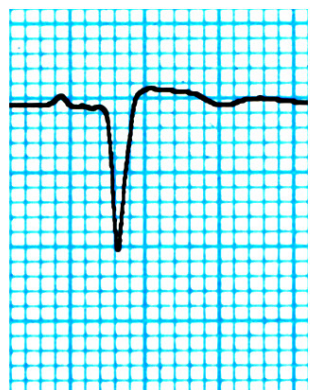
aVR



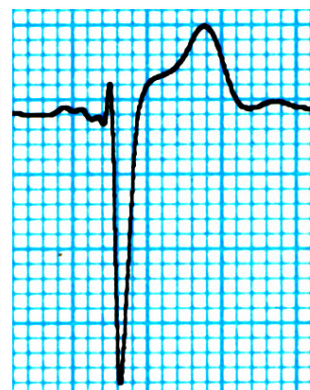
aVL



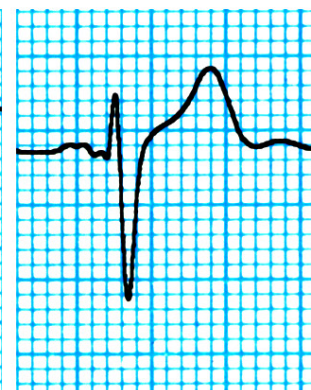
aVF



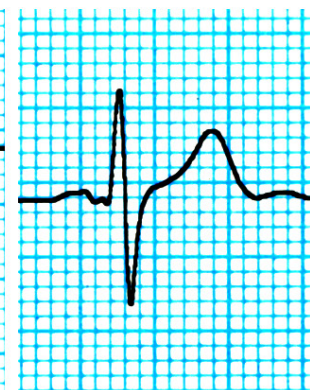
V1



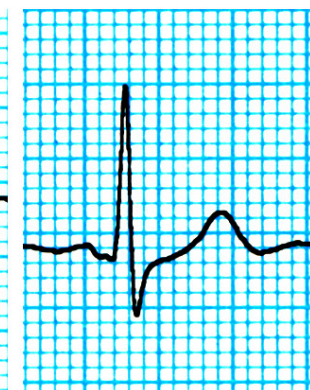
V2



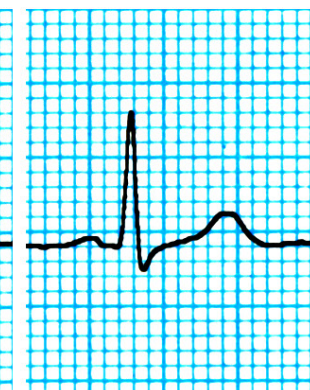V3



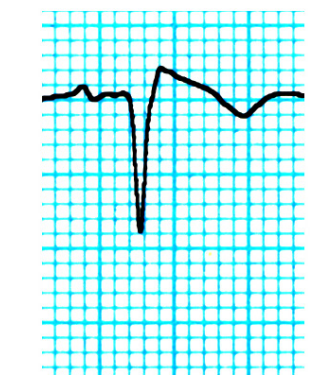V4



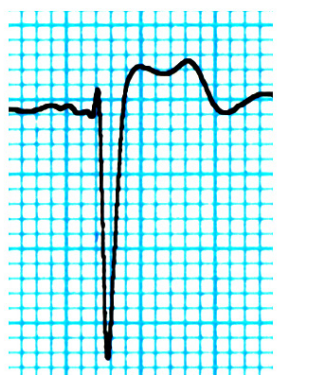V5



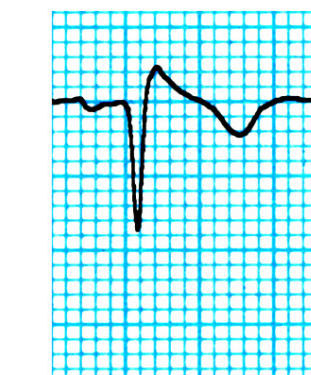V6



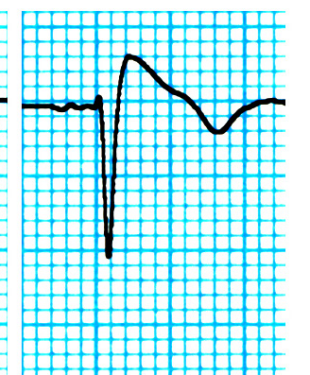V1(3°sp)



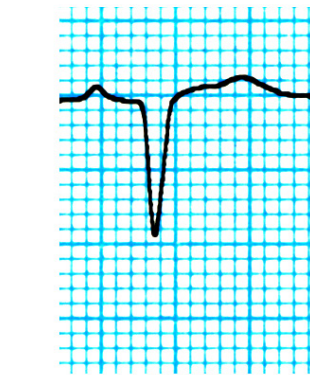V2(3°sp)



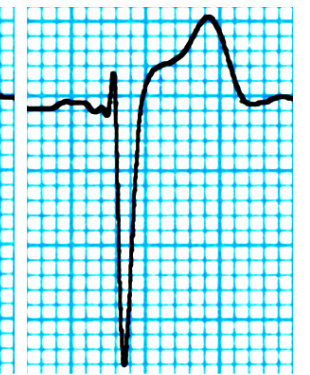
V1(2° sp)



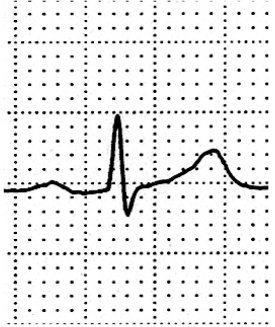
V2(2°sp)



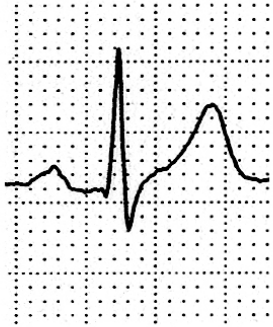V1(5°sp)



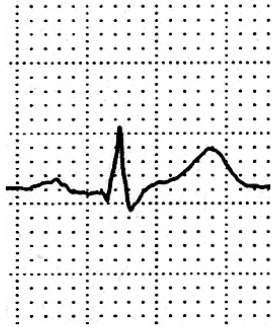V2(5°sp)



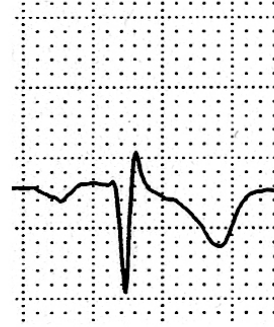I



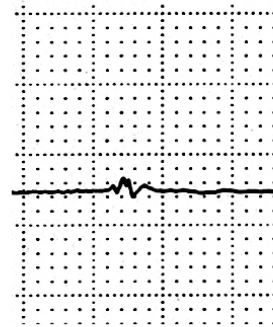
II



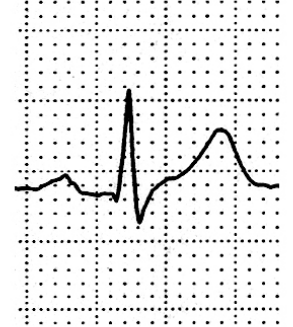
III



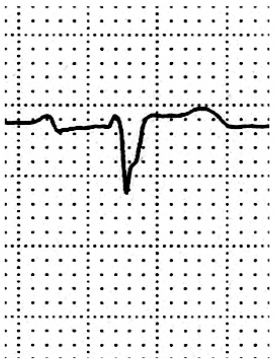
aVR



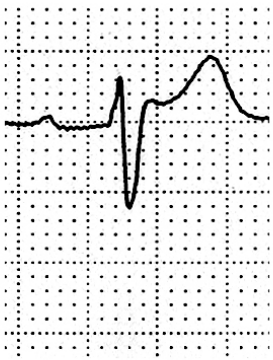aVL



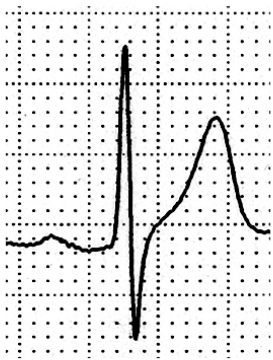
aVF



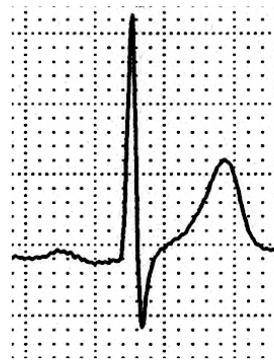V1



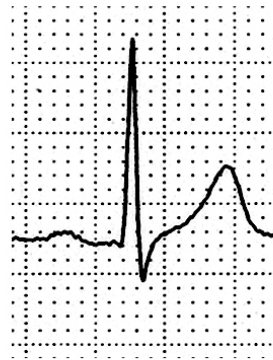V2



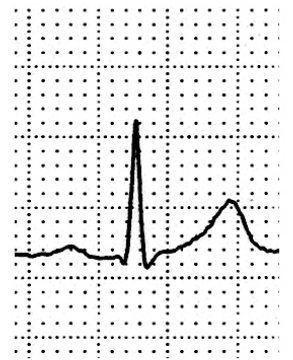
V3



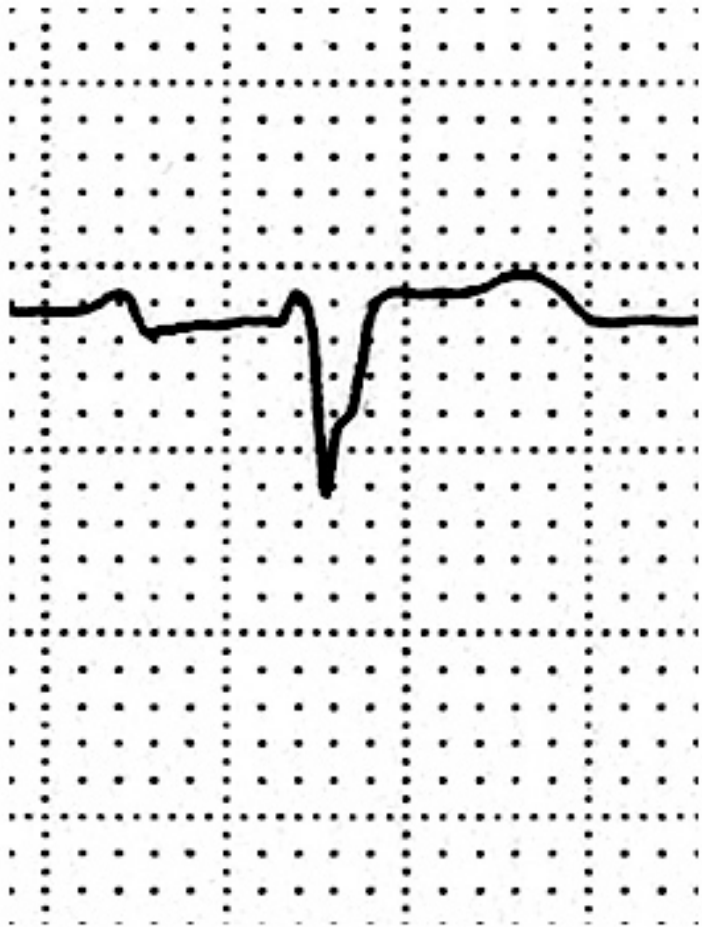V4



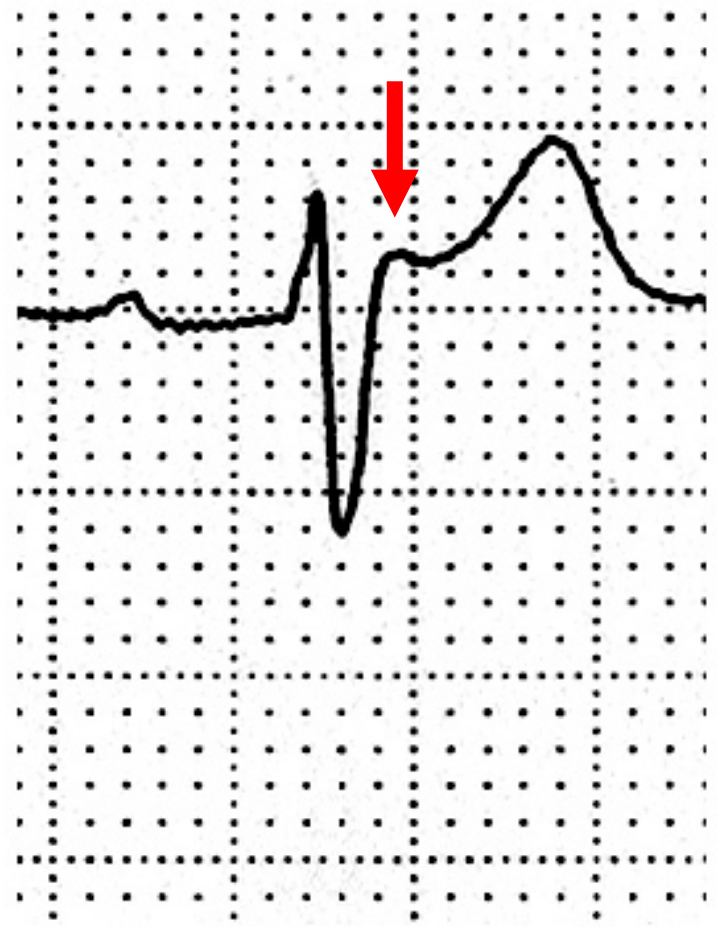
V5



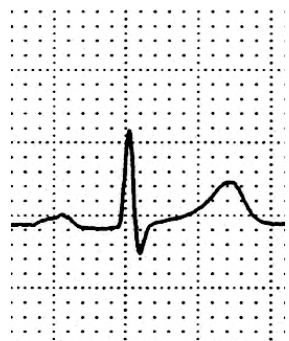V6



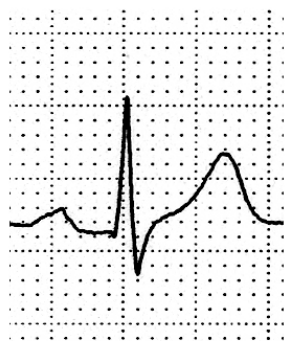
V1



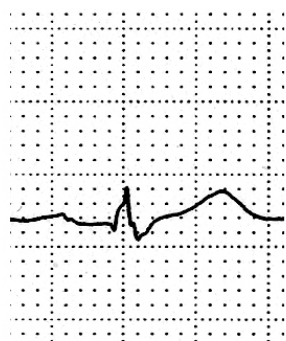
V2



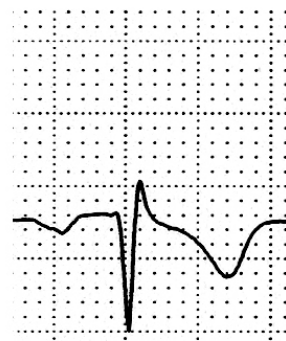I



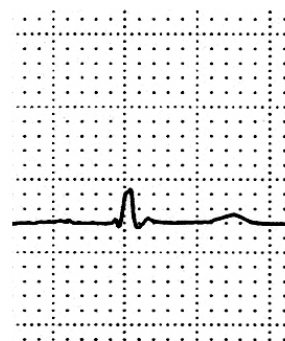
II



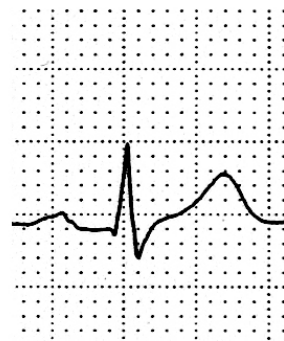III



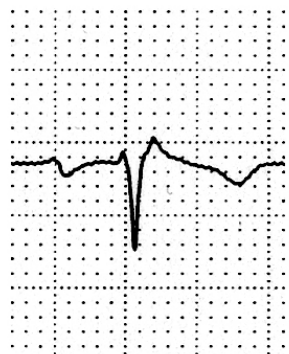aVR



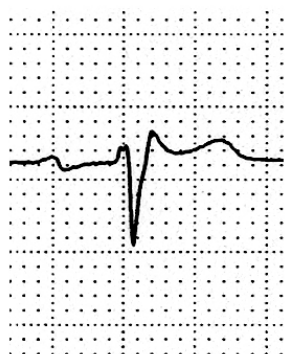
aVL



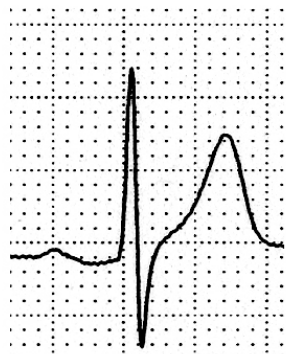aVF



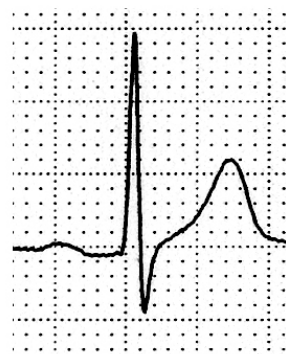
V1



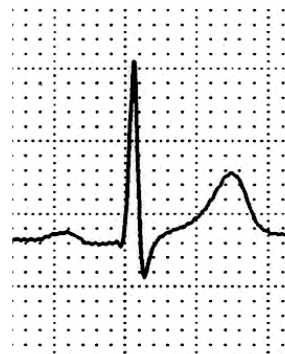V2



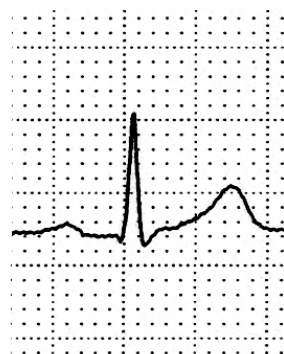V3



V4

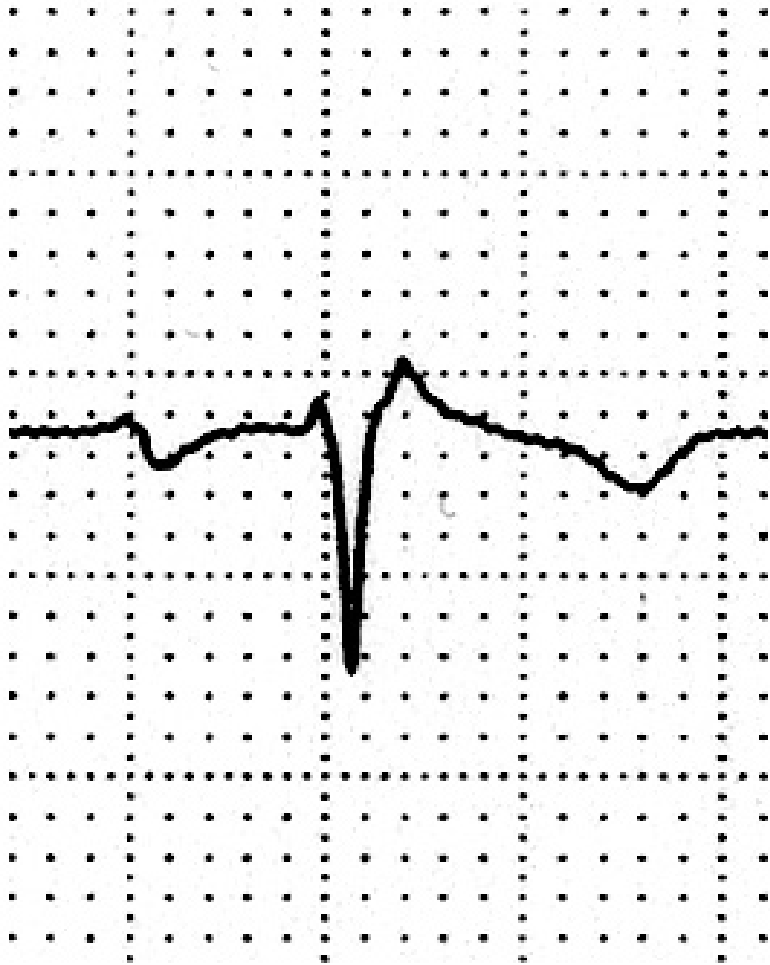

V5

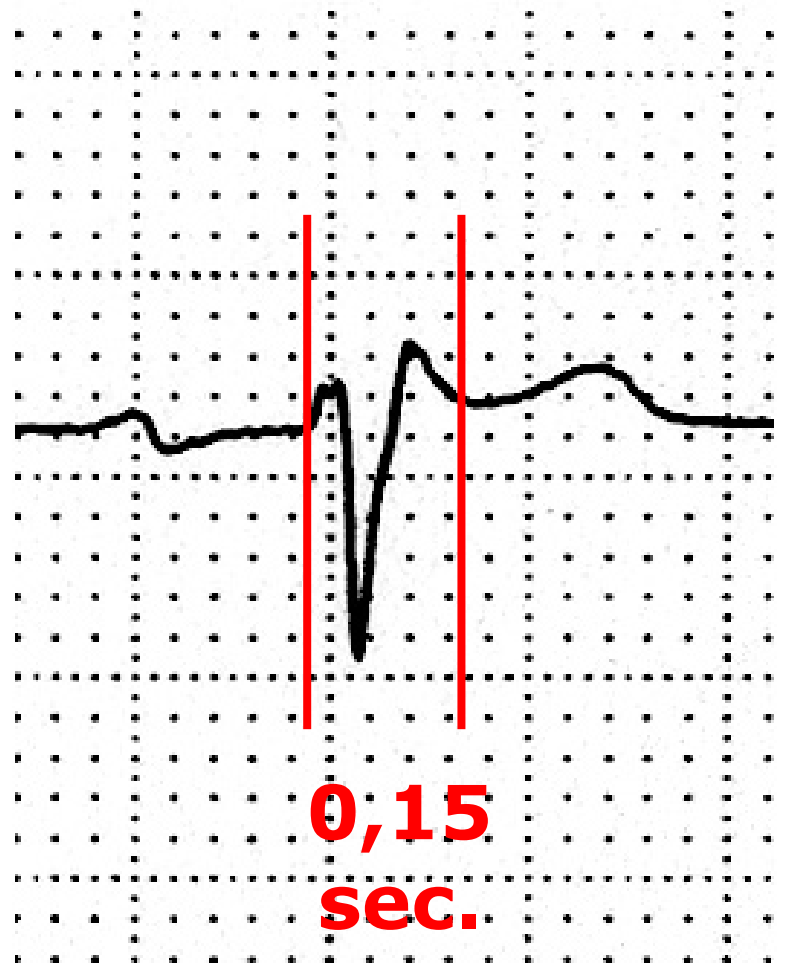

V6

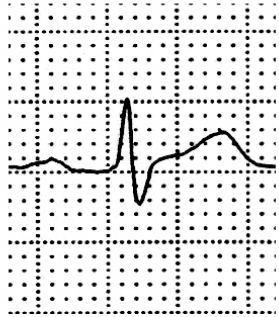
2° spazio intercostale



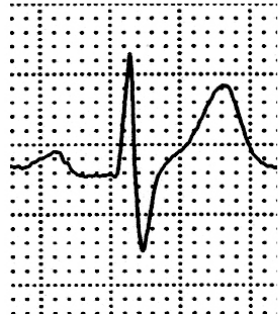V1



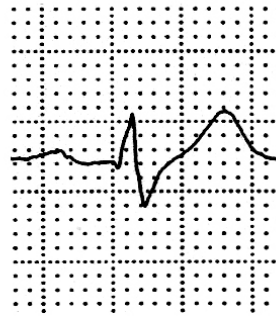V2



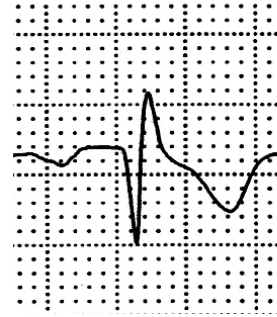I



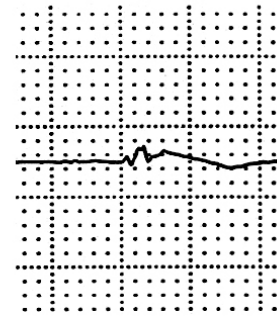
II



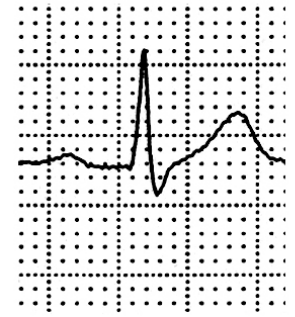III



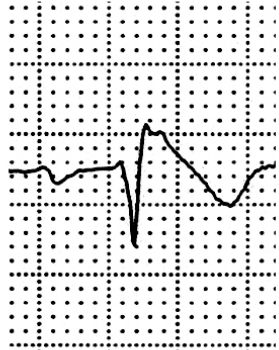aVR



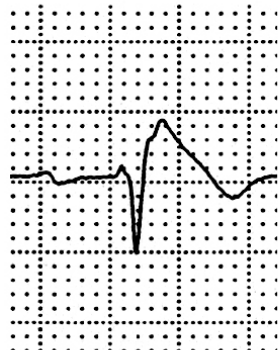
aVL



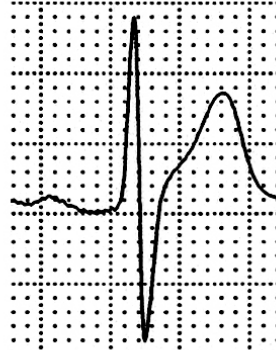
aVF



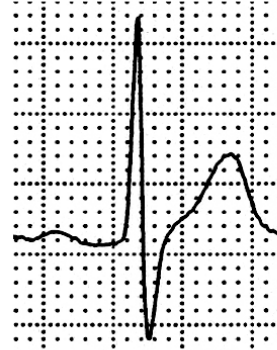
V1



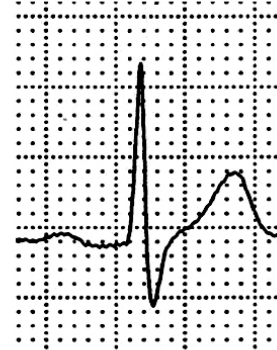
V2



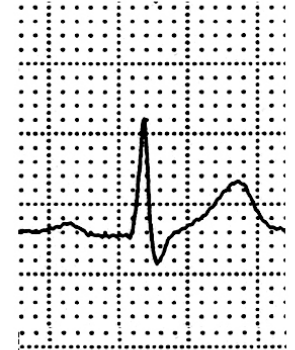V3



V4



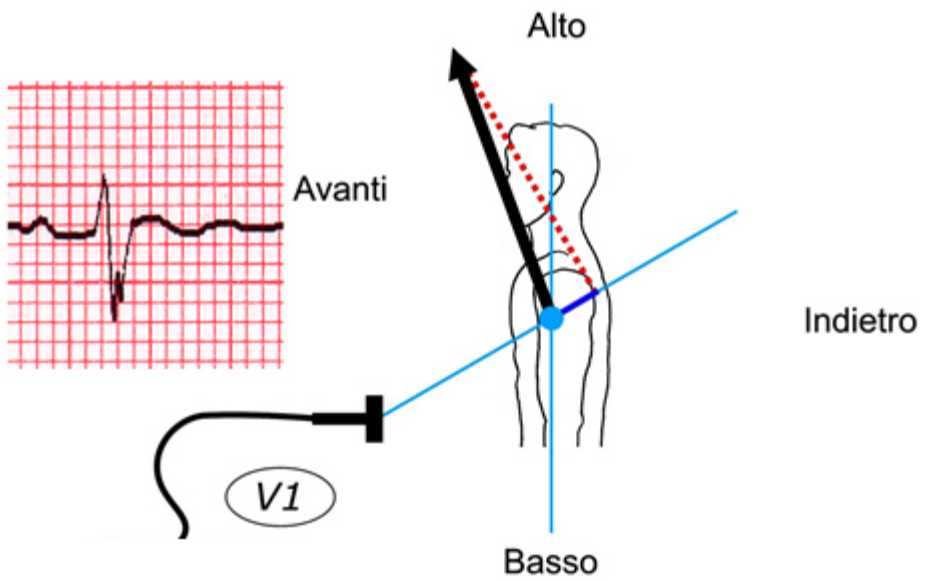
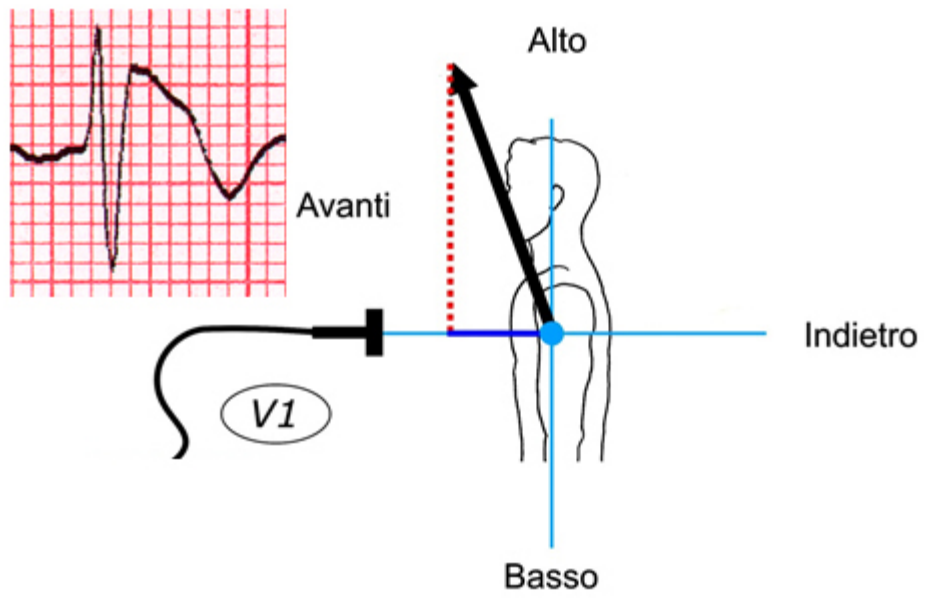
V5



V6

Flecainide

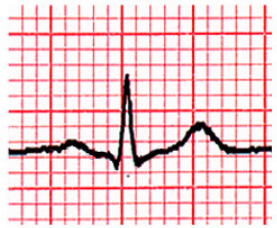**Ma perché bisogna spostare
più in alto gli elettrodi
per riconoscere
il pattern di Brugada?**



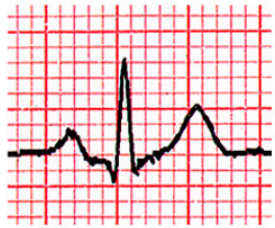ANALISI DELL'ECG IN PRESENZA DI ONDA POSITIVA TERMINALE IN V1-V2

Valutare:

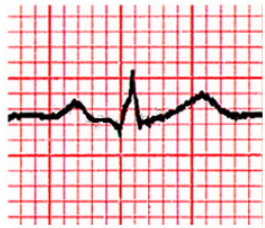- ✓ Le derivazioni V1-V3 al 3° e 2° spazio
- ✓ La morfologia dell'onda positiva terminale
- ✓ La durata dell'onda positiva terminale
- ✓ La durata del QRS in V1-V2 paragonata a quella rilevata in V6
- ✓ Il sottoslivellamento di ST in II, III, aVF



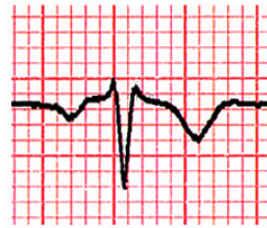I



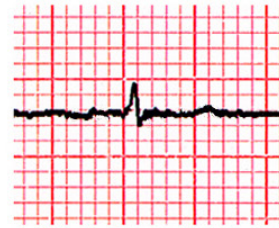II



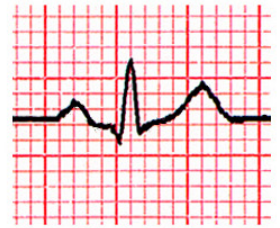III



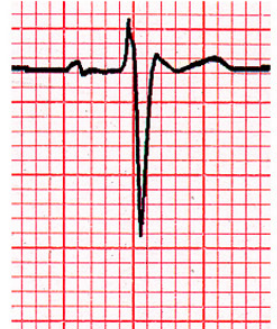
aVR



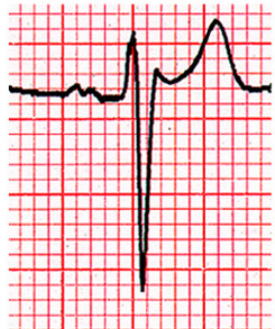aVL



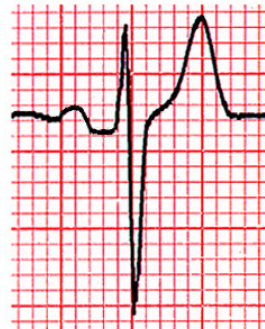aVF



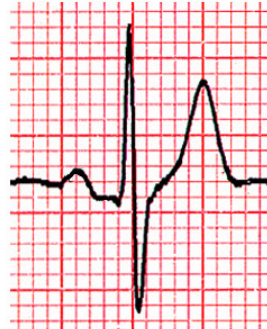V1



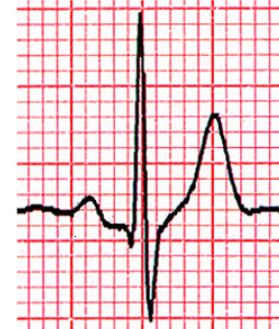V2



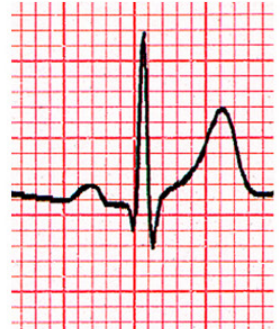
V3



V4

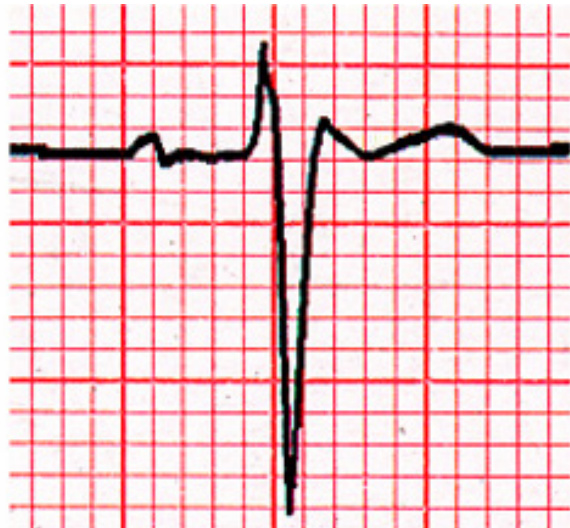


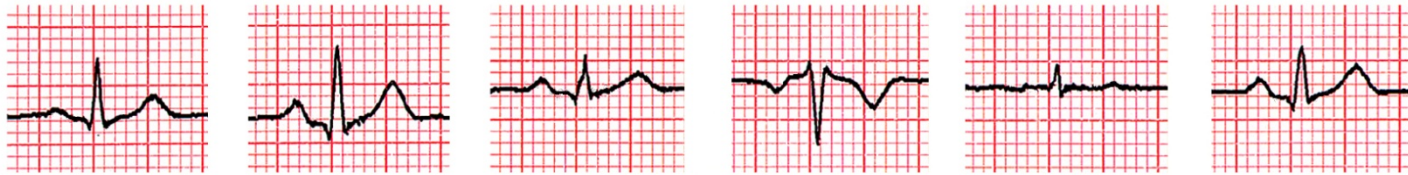
V5



V6

V1





I

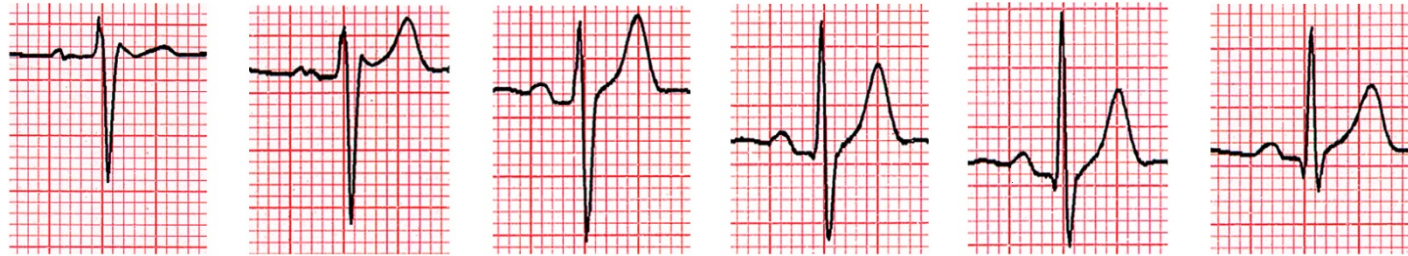II

III

aVR

aVL

aVF



V1

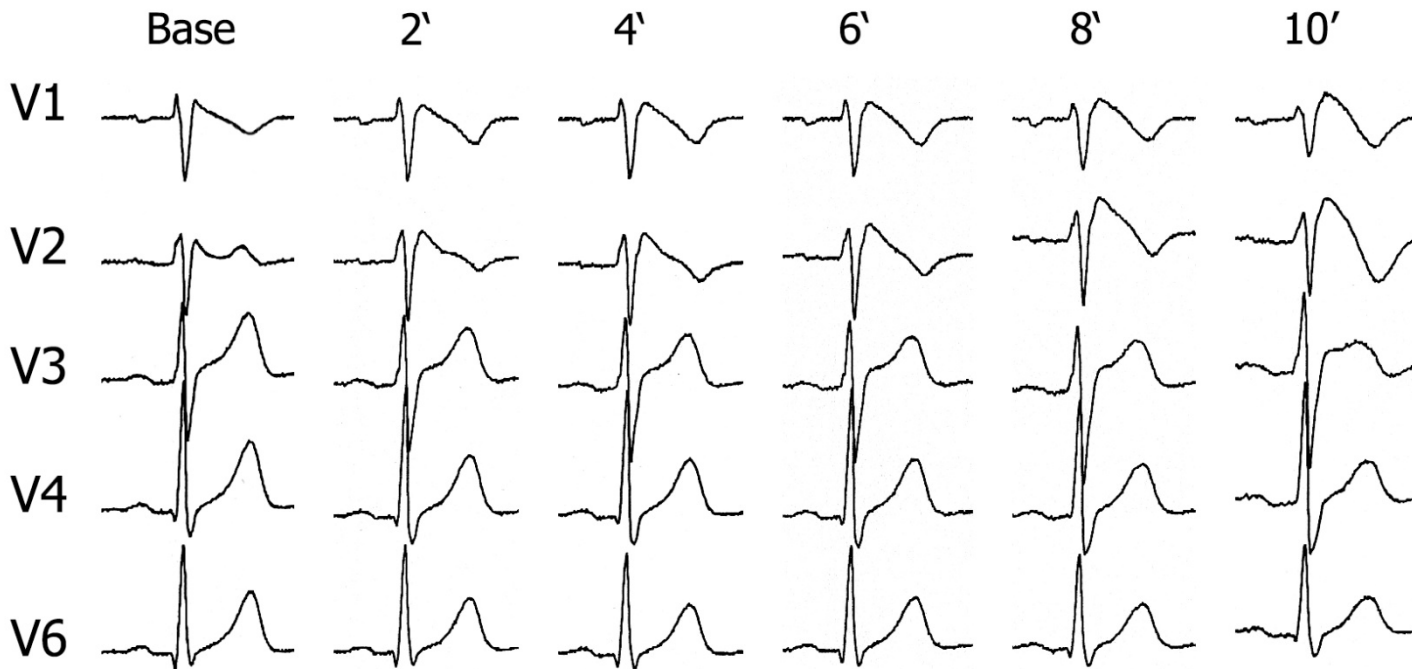
V2

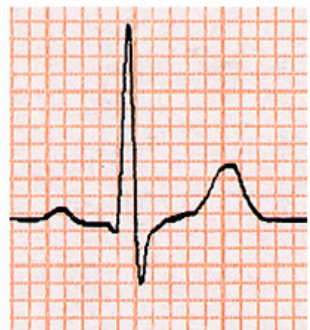V3

V4

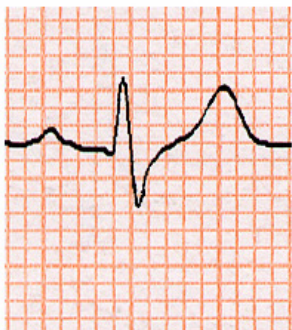
V5

V6

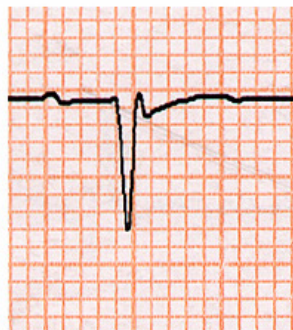




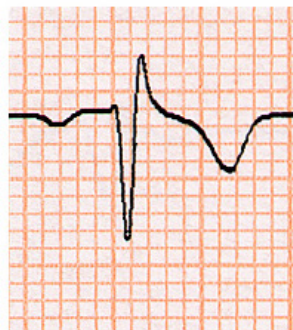
I



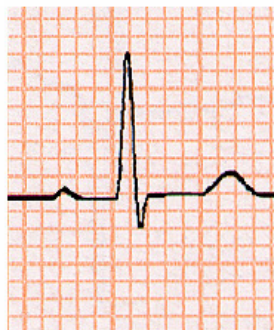II



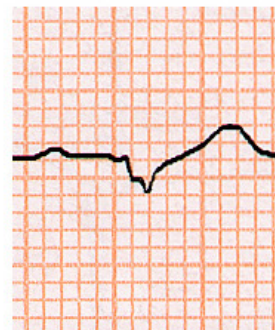
III



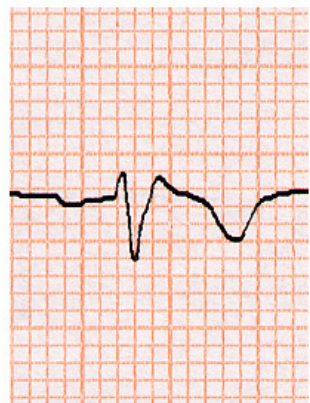aVR



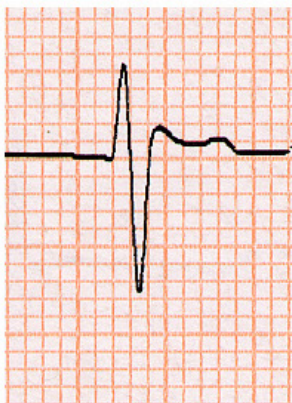aVL



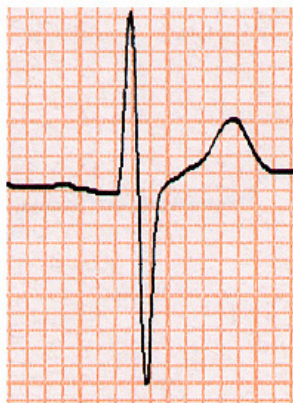
aVF



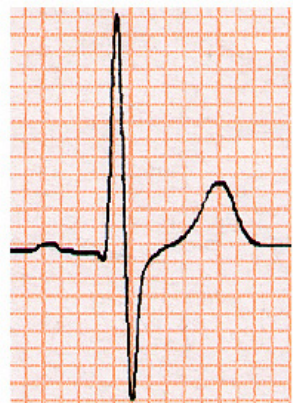
V1



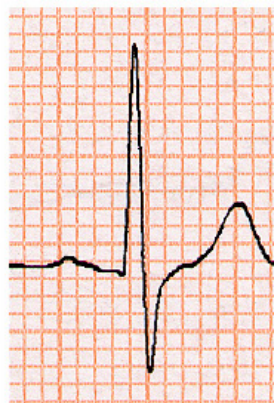V2



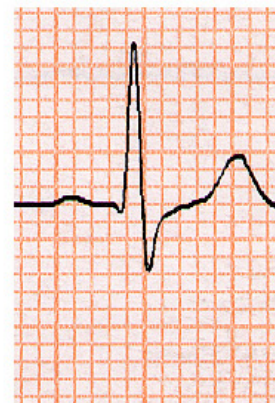V3



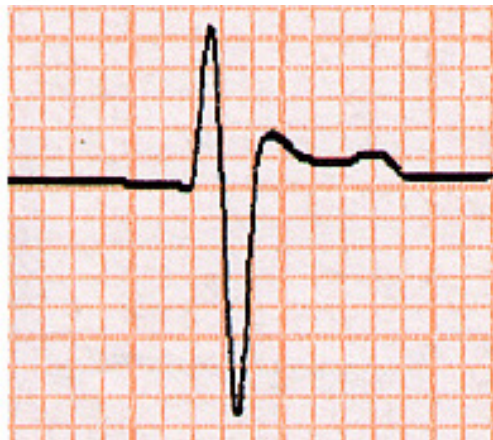V4



V5



V6



**BUNDLE-BRANCH BLOCK WITH SHORT P-R INTERVAL
IN HEALTHY YOUNG PEOPLE PRONE TO
PAROXYSMAL TACHYCARDIA**

LOUIS WOLFF, M.D., BOSTON, MASS., JOHN PARKINSON, M.D., LONDON,
ENG., AND PAUL D. WHITE, M.D., BOSTON, MASS.

**Right Bundle Branch Block, Persistent ST Segment Elevation
and Sudden Cardiac Death: A Distinct Clinical and
Electrocardiographic Syndrome**

A Multicenter Report

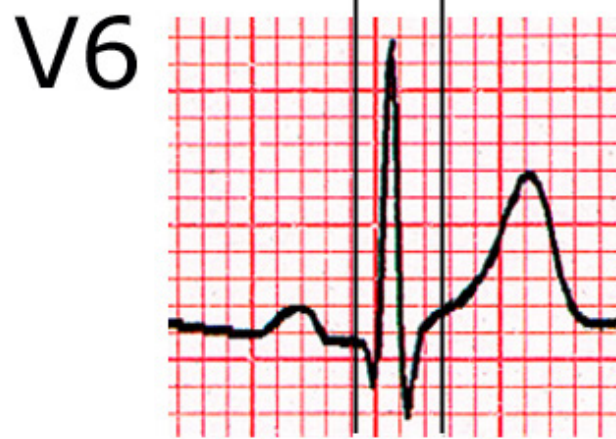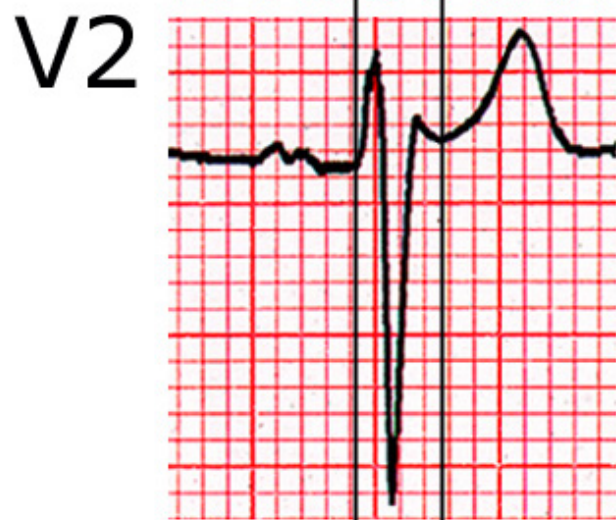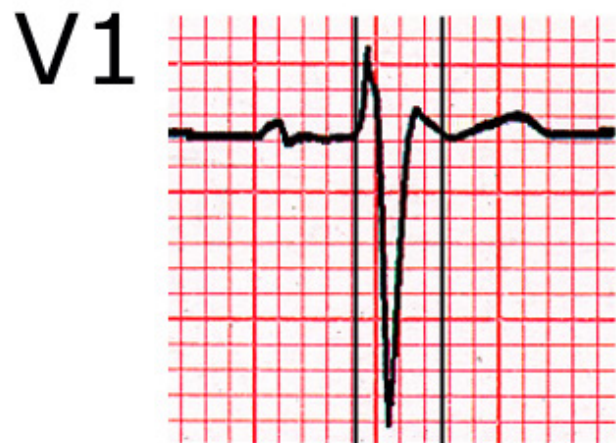PEDRO BRUGADA, MD, JOSEP BRUGADA, MD*†

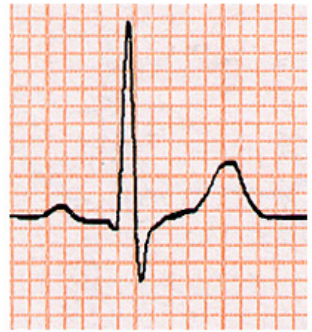
Aalst, Belgium and Barcelona, Spain

ANALISI DELL'ECG IN PRESENZA DI ONDA POSITIVA TERMINALE IN V1-V2

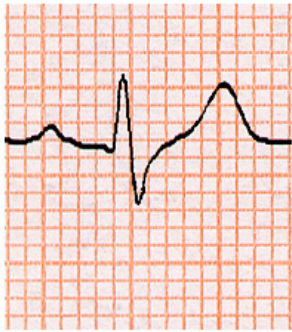
Valutare:

- ✓ Le derivazioni V1-V3 al 3° e 2° spazio
- ✓ La morfologia dell'onda positiva terminale
- ✓ La durata dell'onda positiva terminale
- ✓ La durata del QRS in V1-V2 paragonata a quella rilevata in V6
- ✓ Il sottoslivellamento di ST in II, III, aVF

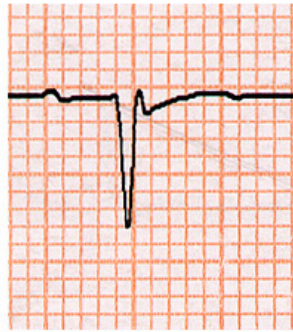




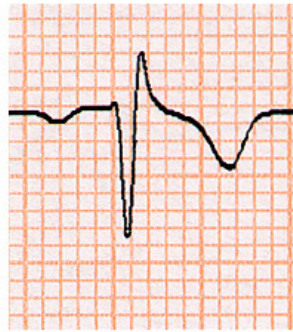
I



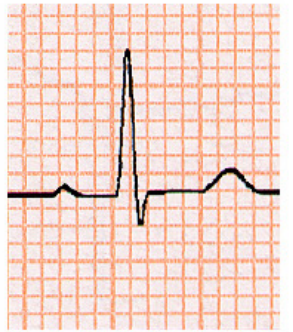II



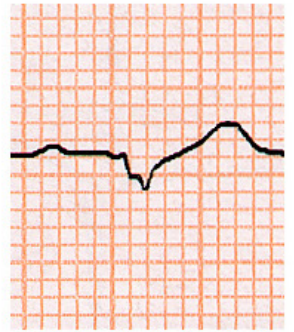
III



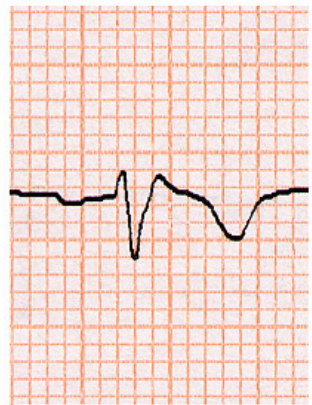
aVR



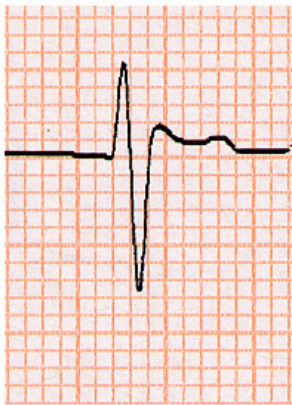
aVL



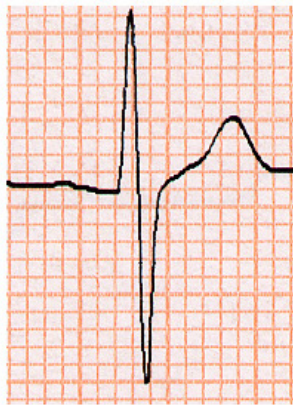
aVF



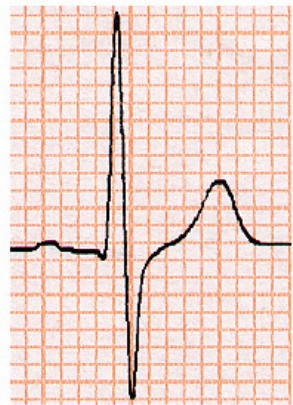
V1



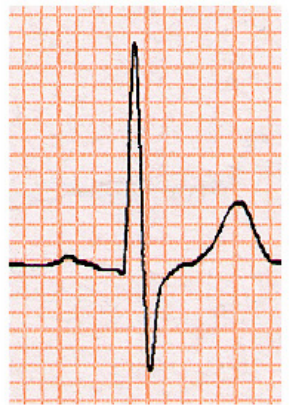
V2



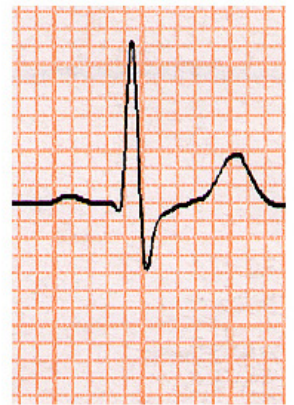V3



V4

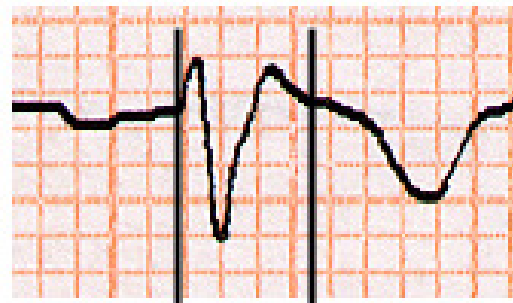

V5

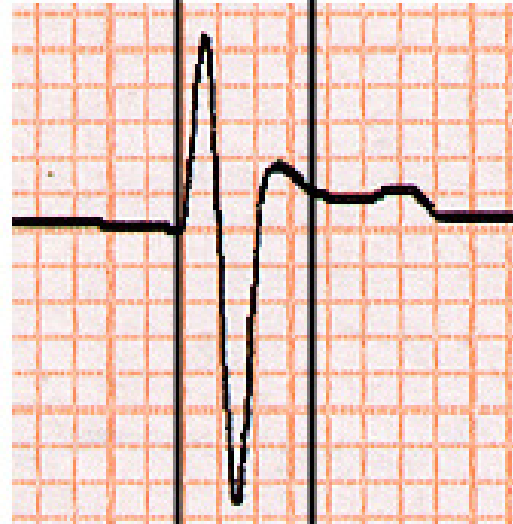

V6

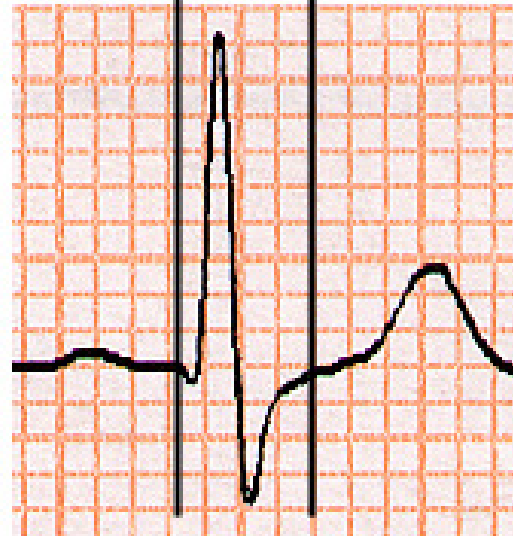
V1

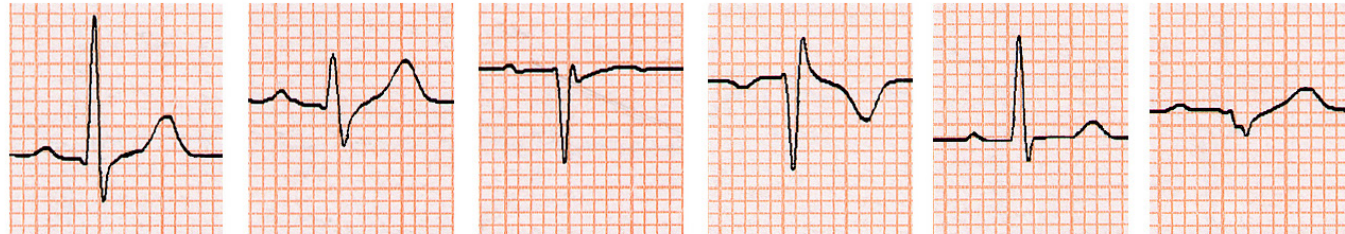


V2

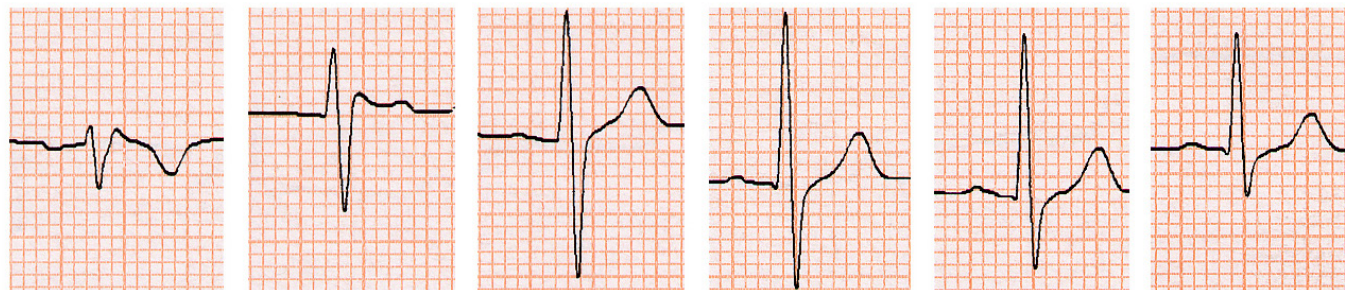


V6

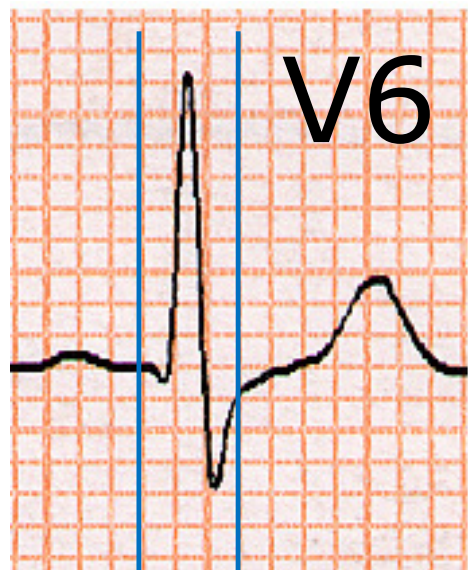




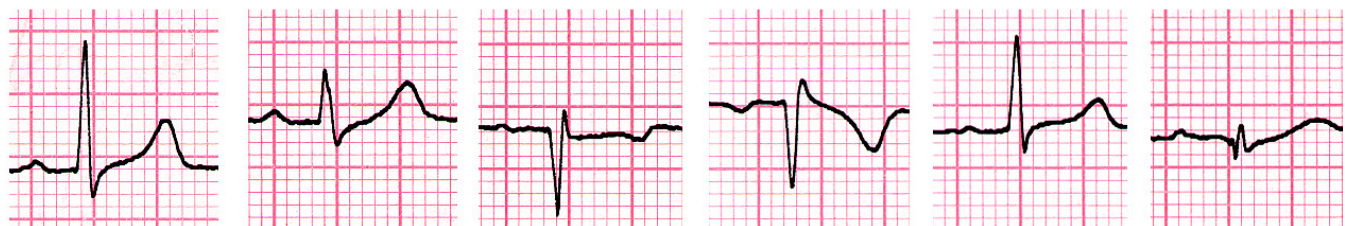
I II III aVR aVL aVF



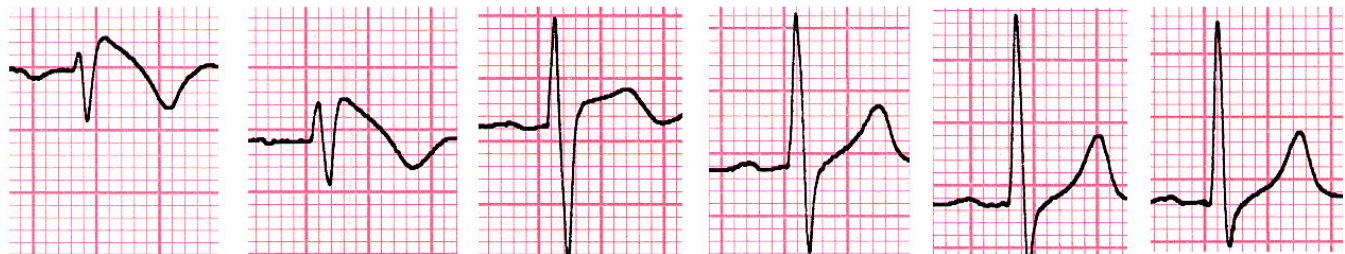V1 V2 V3 V4 V5 V6



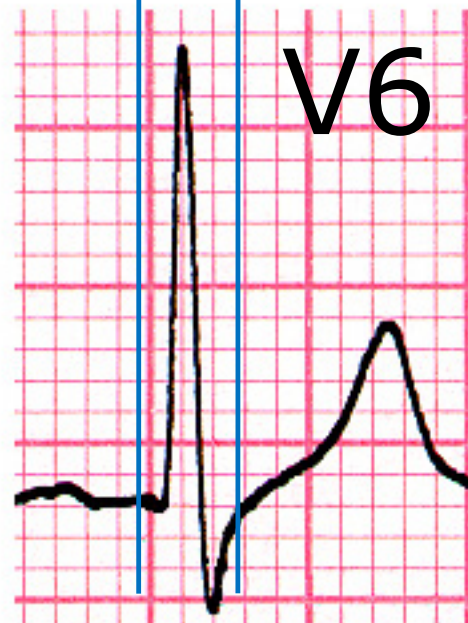
V6



I II III aVR aVL aVF



V1 V2 V3 V4 V5 V6



V6

ANALISI DELL'ECG IN PRESENZA DI ONDA POSITIVA TERMINALE IN V1-V2

Valutare:

- ✓ Le derivazioni V1-V3 al 3° e 2° spazio
- ✓ La morfologia dell'onda positiva terminale
- ✓ La durata dell'onda positiva terminale
- ✓ La durata del QRS in V1-V2 paragonata a quella rilevata in V6
- ✓ Il sottoslivellamento di ST in II, III, aVF

ORIGINAL ARTICLE

ST Segment Depression in the Inferior Leads in Brugada Pattern: A New Sign

Pasquale Crea, M.D., Giuseppe Picciolo, M.D., Francesco Lizza, M.D.,
and Giuseppe Oreto, M.D.

From the Department of Clinical and Experimental Medicine, University Hospital of Messina, Messina, Italy

Background: Brugada pattern (BP) is characterized by J wave and elevated ST segment in the right precordial leads. At times the ECG signs are present only with the electrodes displaced 1 or 2 intercostal spaces above.

Methods: We analyzed the electrocardiograms of 87 subjects with type 1 BP looking for ST segment depression (≥ 0.1 mV with duration ≥ 0.08 s) in the inferior leads. In 21 subjects, BP pattern was evident only with V_1 – V_2 electrodes at the 3rd or 2nd space.

Results: ST segment depression was present in 41 cases (47%). In the 21 patients with BP recognizable only at the 2nd or 3rd intercostal space, 10 (48%) presented a significant ST depression in the inferior leads.

Conclusions: ST segment analysis in the inferior leads has never been considered for BP diagnosis. When accurately searched for, however, ST segment depression can be observed in those leads in BP, suggesting the need for further investigation.

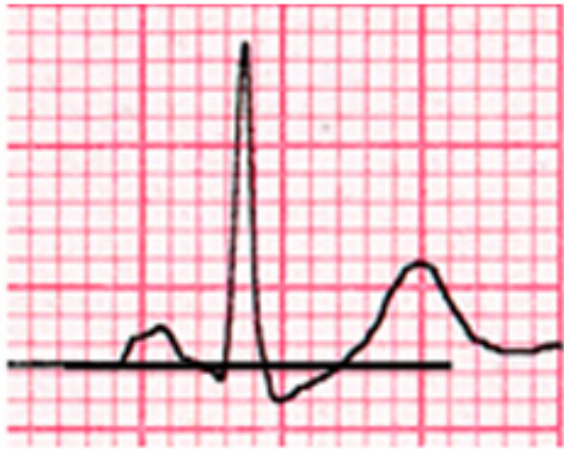
Ann Noninvasive Electrocardiol 2014;00(0):1–5

Brugada pattern; ST segment

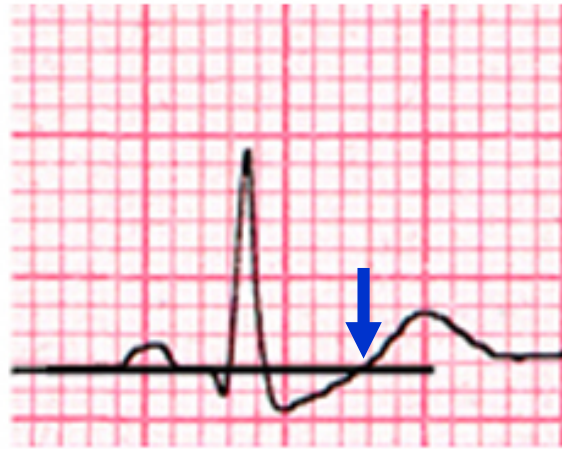
CASISTICA

- **87** pazienti con Pattern di Brugada tipo 1
- In **66** casi la diagnosi era evidente con gli elettrodi di V1-V2 al 4° spazio
- In **21** soggetti il pattern di Brugada era riconoscibile solo con gli elettrodi di V1-V2 al 3° o 2° spazio.

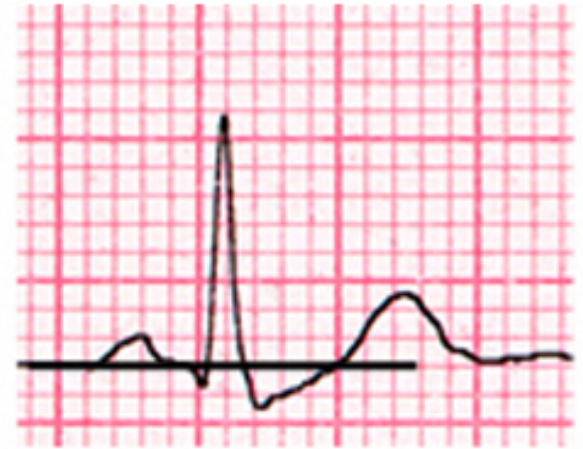
METODICA



II



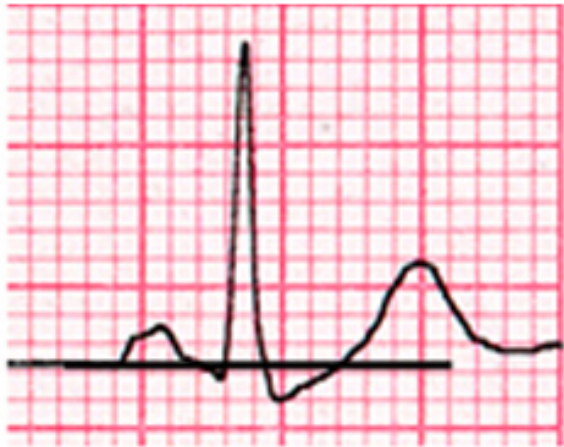III



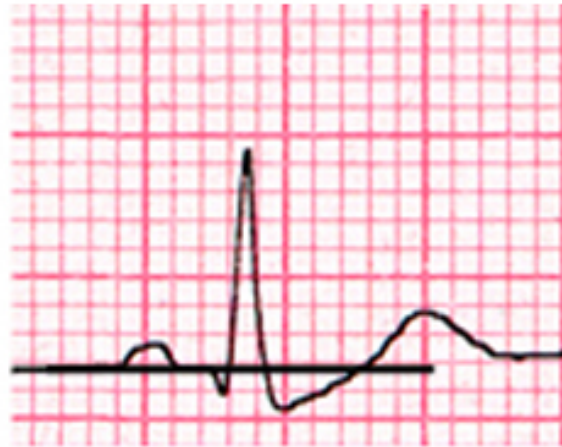aVF

Tracciata una linea orizzontale in corrispondenza dell'ultima parte del tratto T-P, si identificava il momento in cui l'ST raggiungeva la linea isoelettrica. Il punto segnava la fine del tratto ST e l'inizio dell'onda T.

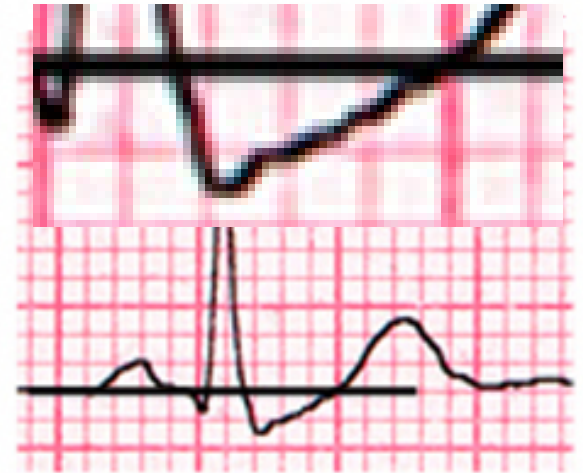METODICA



II



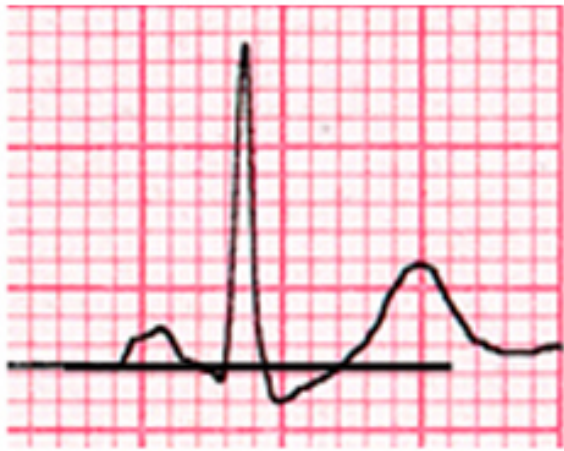
III



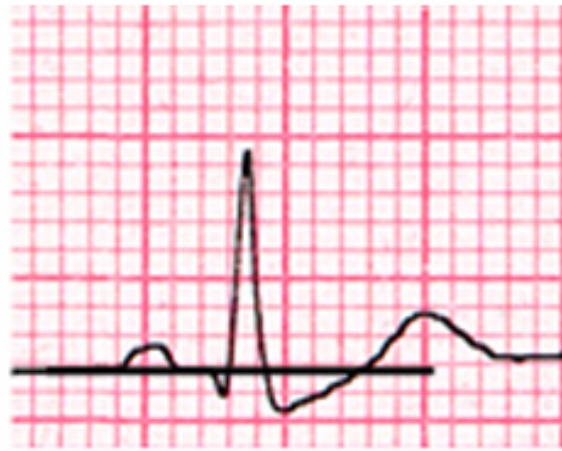
aVF

Se era presente un sottoslivellamento di ST ≥ 0.1 mV (1 mm), si misurava la durata del sottoslivellamento. Un ECG era classificato come positivo (suggestivo di Pattern di Brugada) se almeno 2 derivazioni inferiori mostravano un sottoslivellamento di ST ≥ 0.1 mV con durata ≥ 0.08 sec.

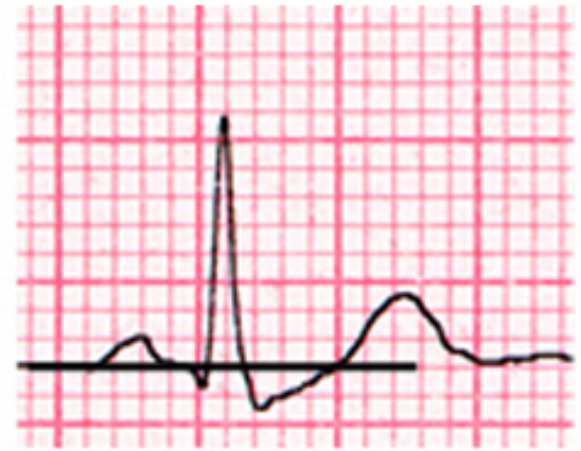
RISULTATI



II

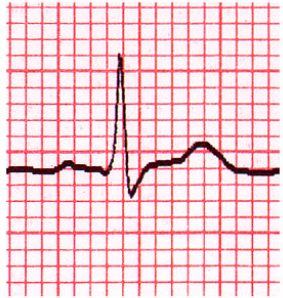


III

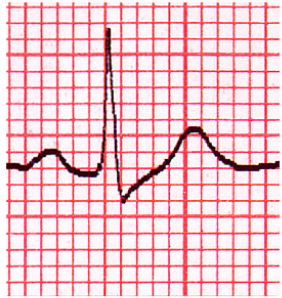


aVF

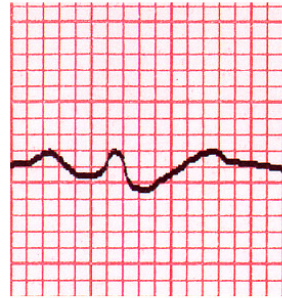Sottoslivellamento di ST (≥ 0.1 mV, ≥ 0.08 sec) era presente in **41** casi (47%). Si osservava in 31 pz (36%) in II, in 29 pz (33%) in III in 41 pz (47%) in aVF. **10 dei 21 pz (48%) con diagnosi possibile solo al 2° o 3° spazio intercostale presentavano un significativo sottoslivellamento di ST nelle derivazioni inferiori.**



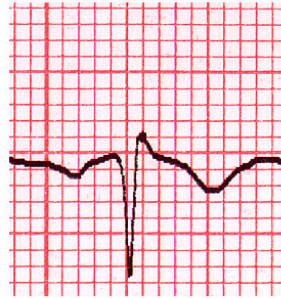
I



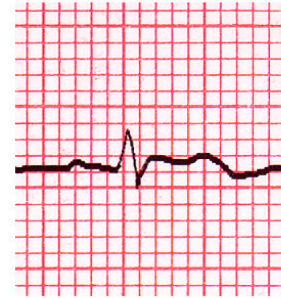II



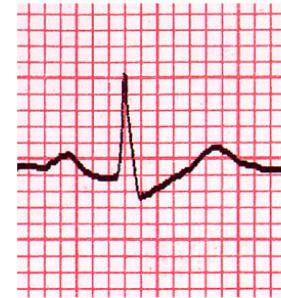III



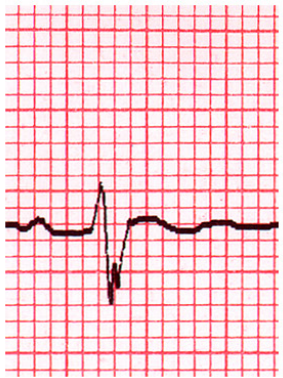
aVR



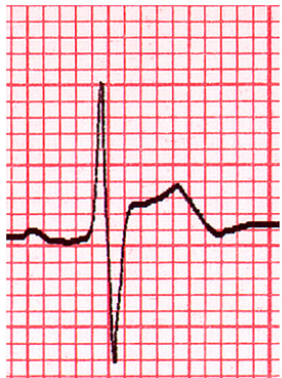
aVL



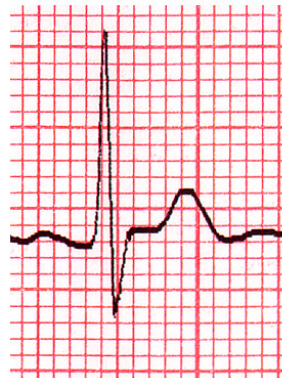
aVF



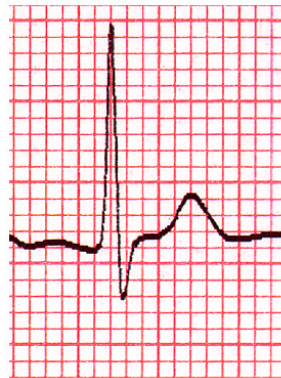V1



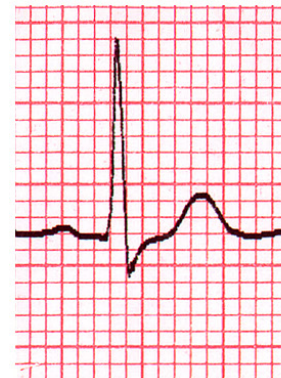V2



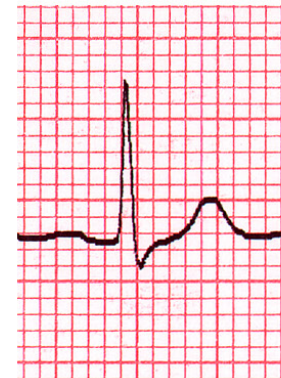
V3



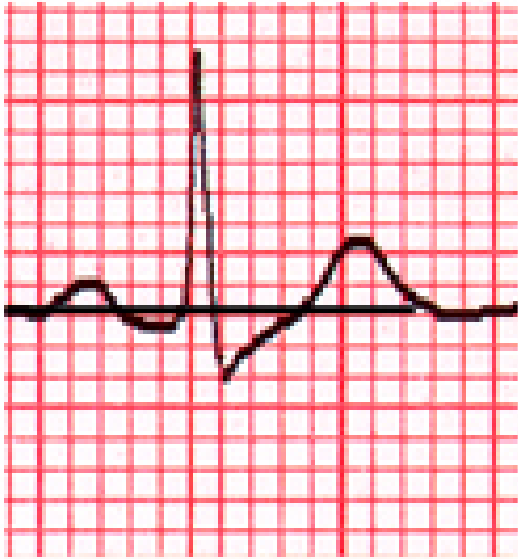
V4



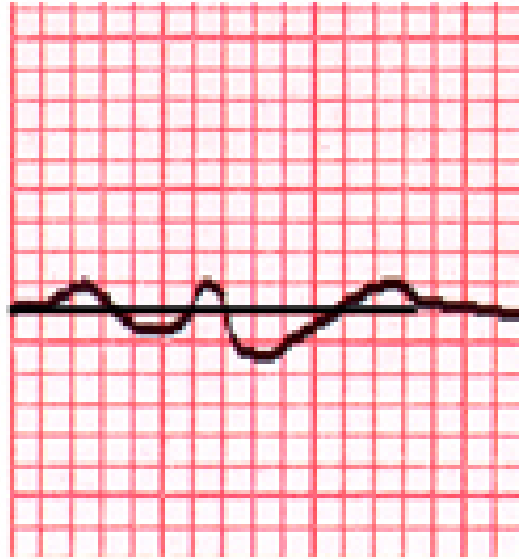
V5



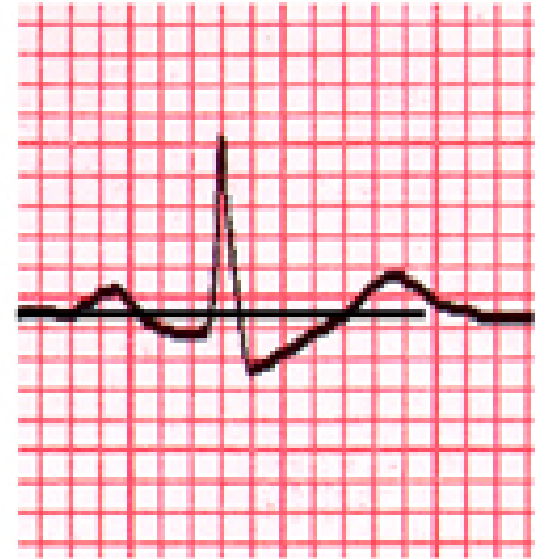
V6



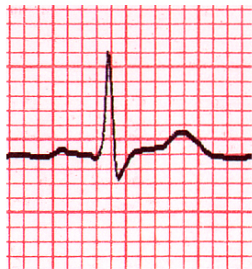II



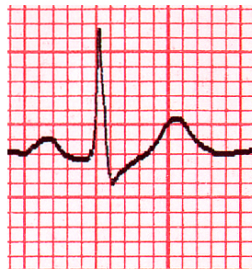
III



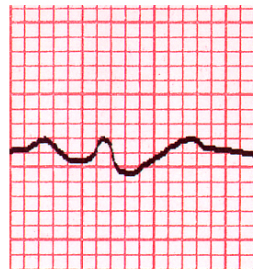
aVF



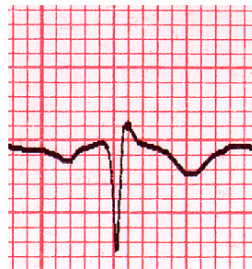
I



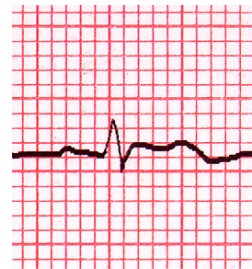II



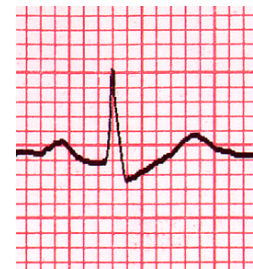
III



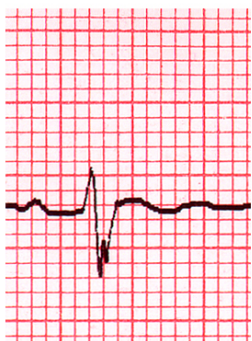aVR



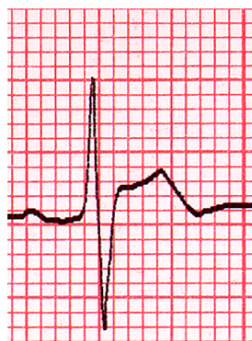aVL



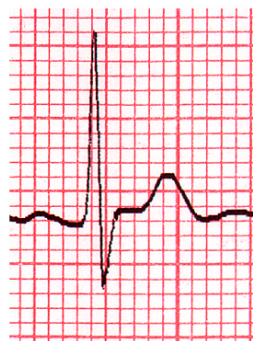
aVF



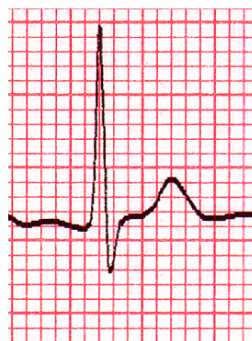V1



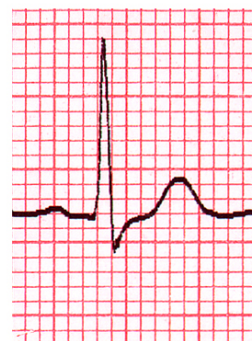V2



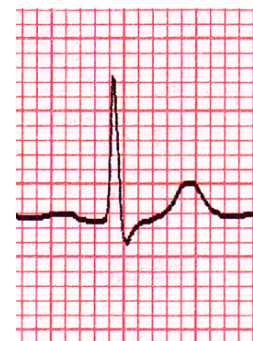
V3



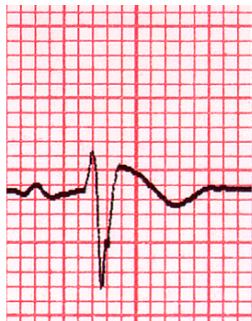V4



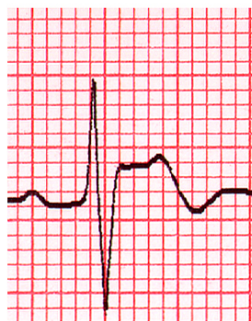V5



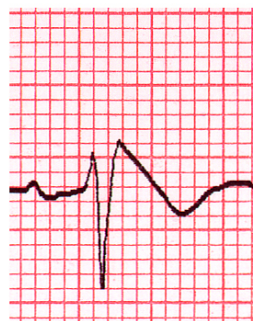V6



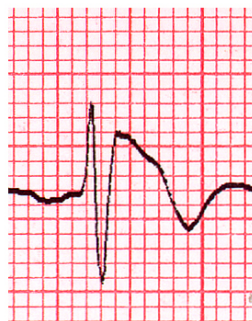V1 3rd is



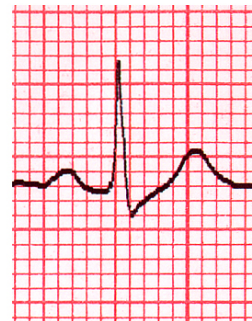V2 3rd is



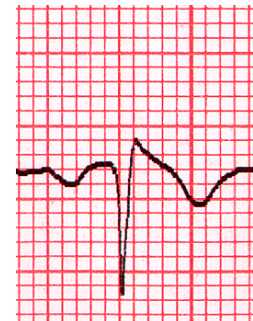V1 2nd is



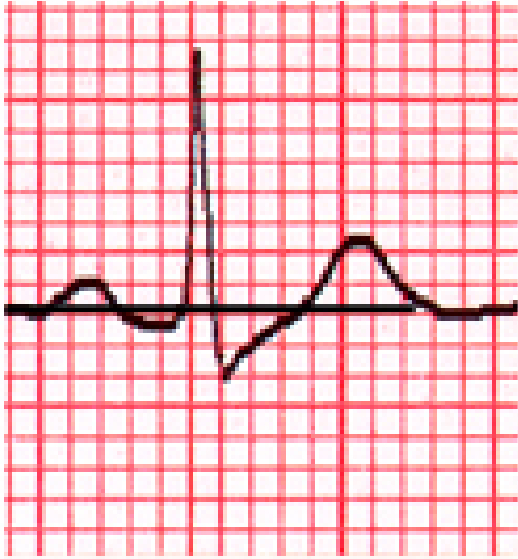
V2 2nd is



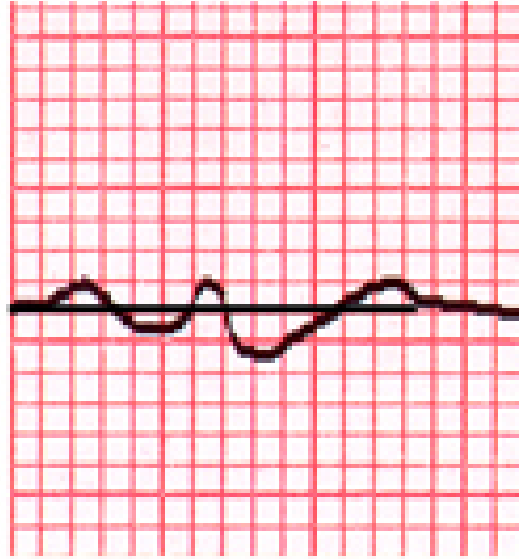
II



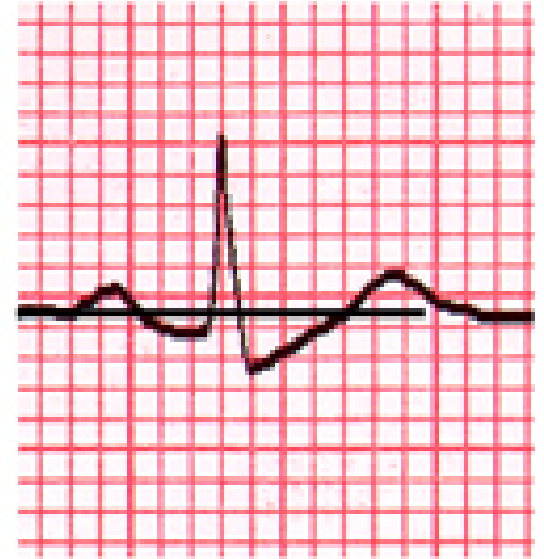
II inverted mirror image



II



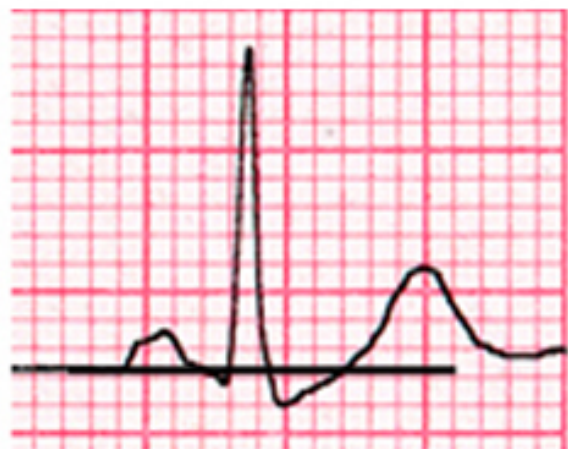III



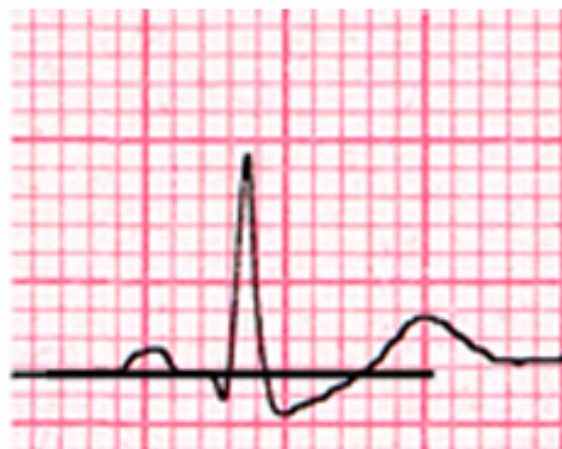aVF

Come riconoscere rapidamente il sottoslivellamento del tratto ST nelle derivazioni Inferiori nei soggetti con pattern di Brugada?

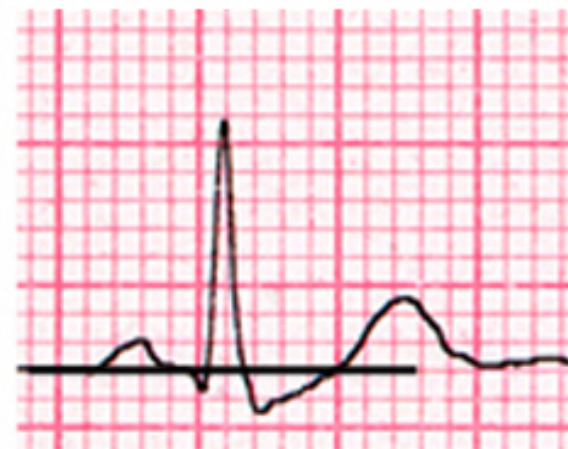?



II

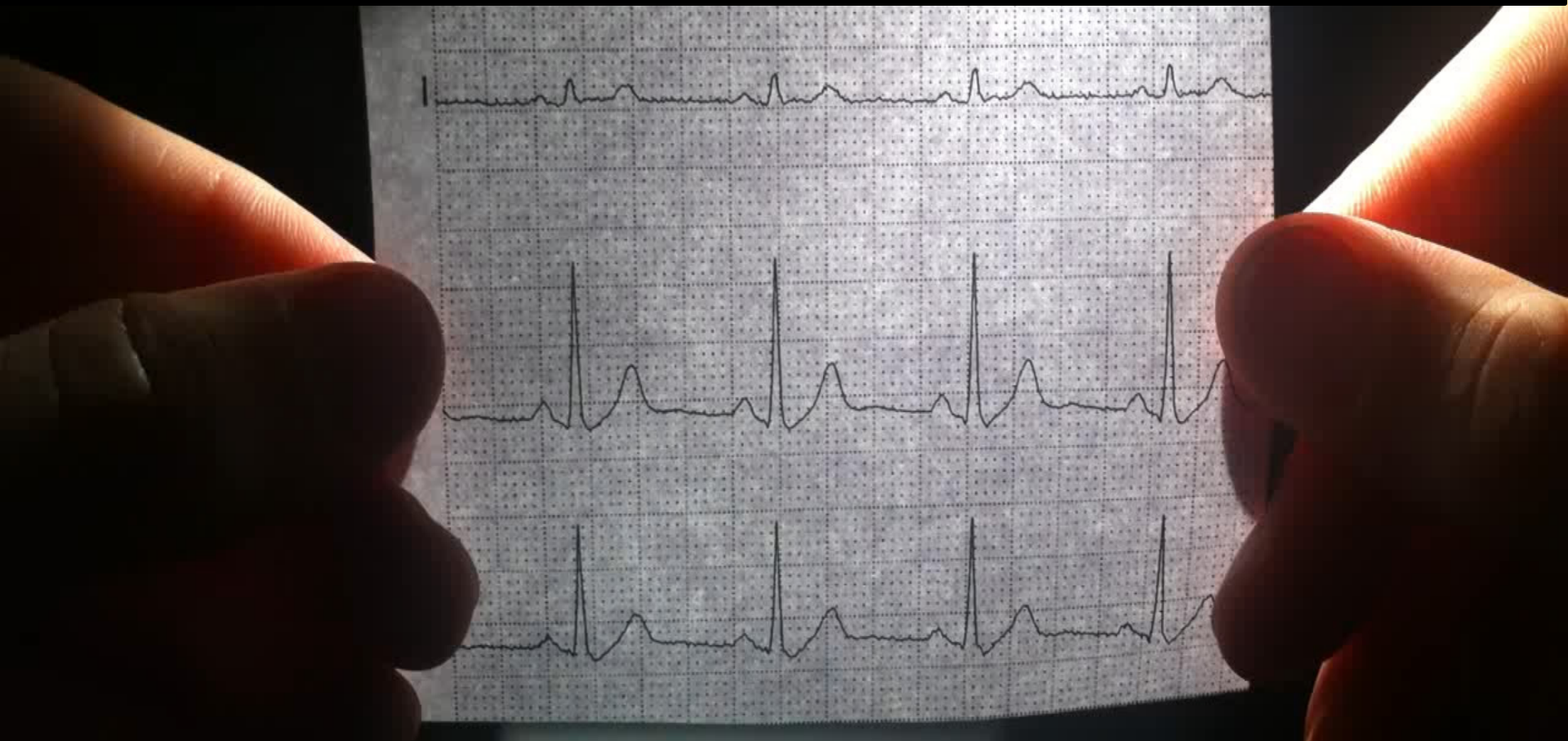


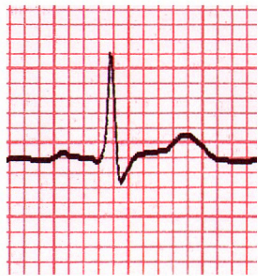III



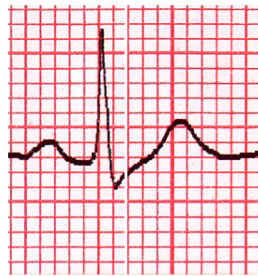aVF

Analizzando le immagini **speculari invertite** delle derivazioni inferiori!

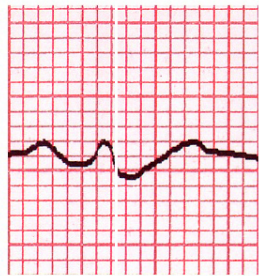




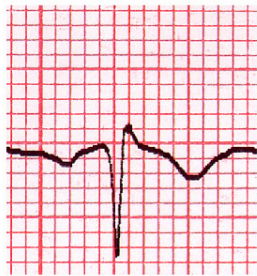I



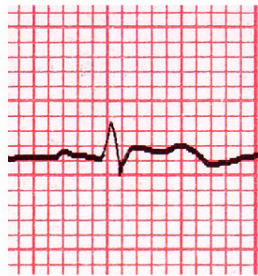II



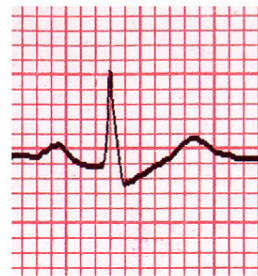III



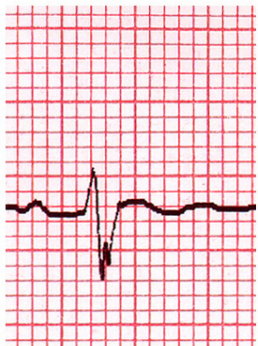aVR



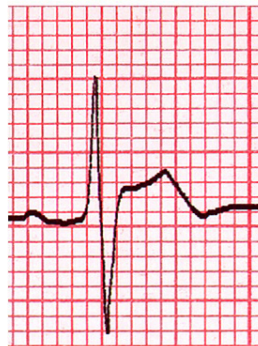aVL



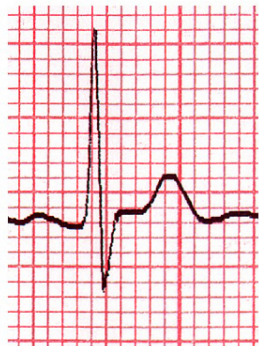
aVF



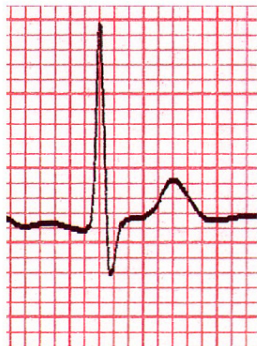V1



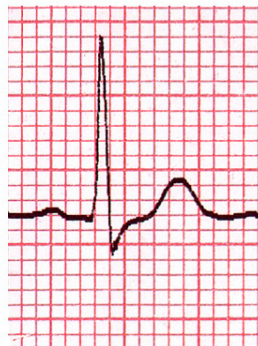V2



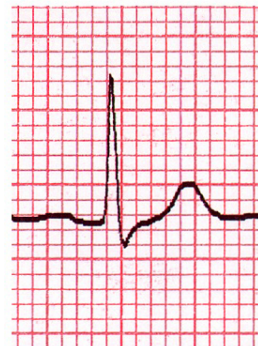V3



V4

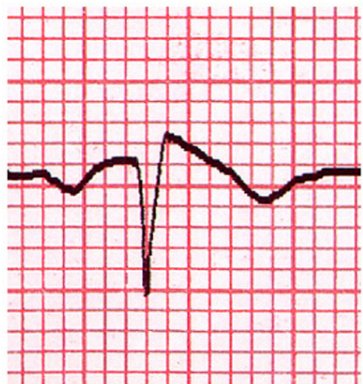


V5

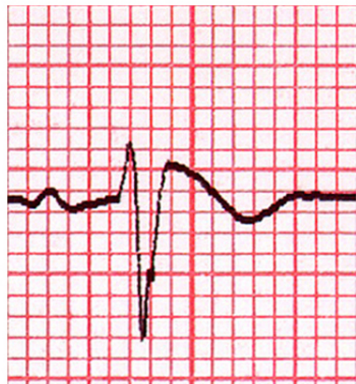


V6

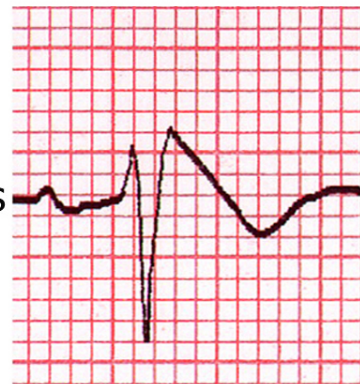aVF



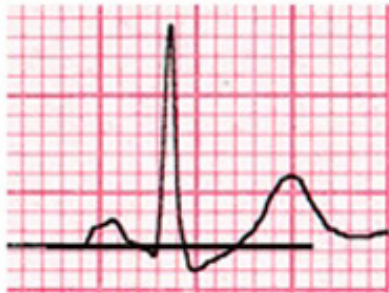V1
3rd is



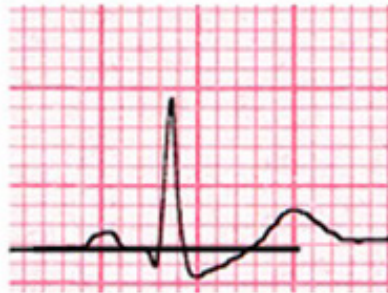
V1
2nd is



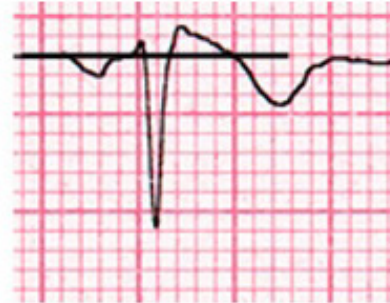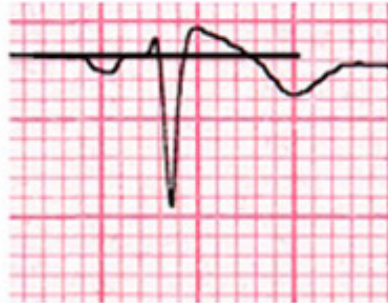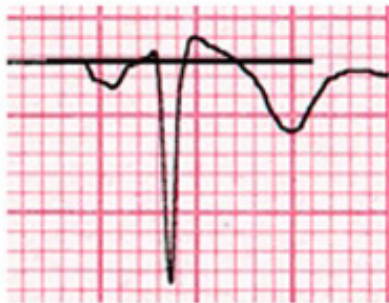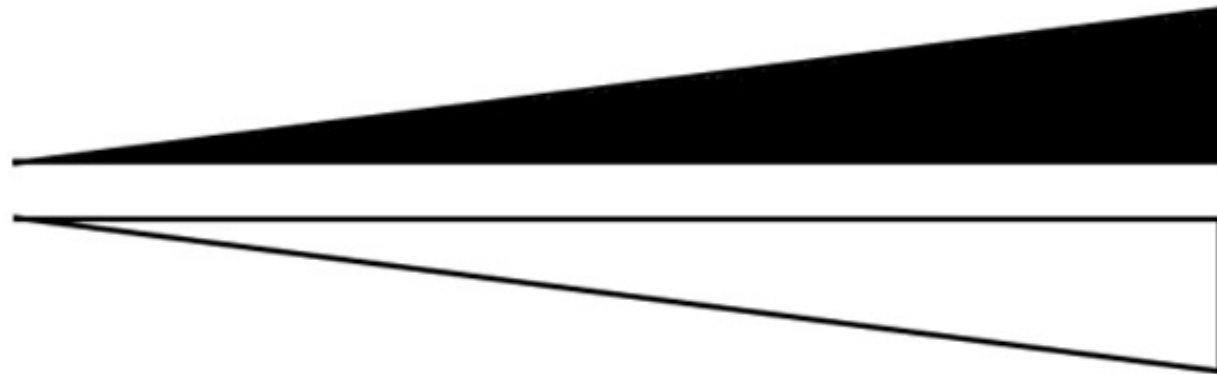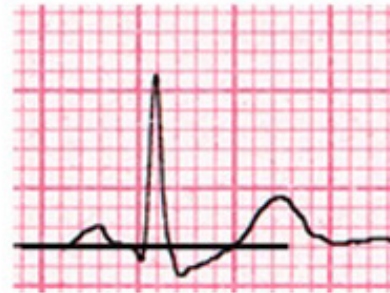II

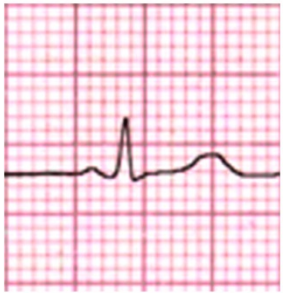

III

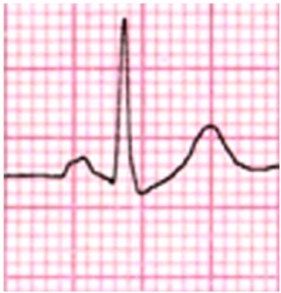

aVF

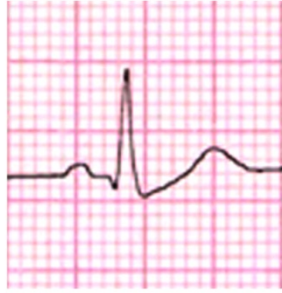



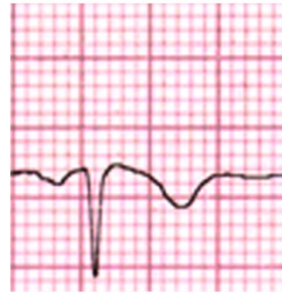
I



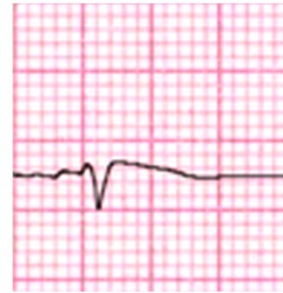
II



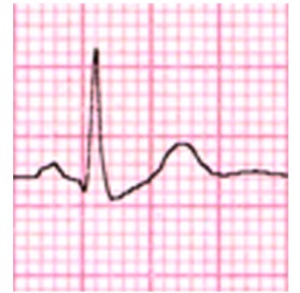III



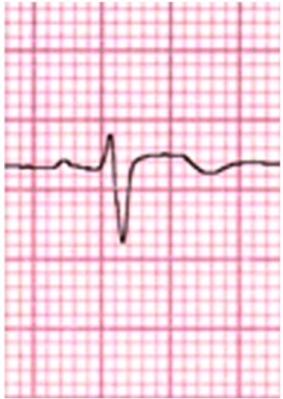
aVR



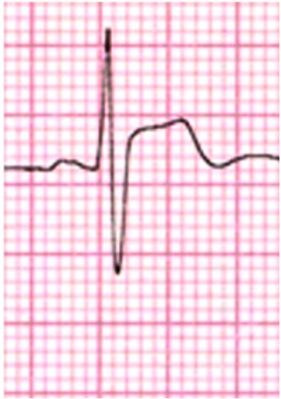aVL



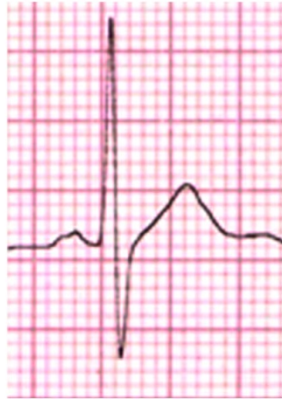aVF



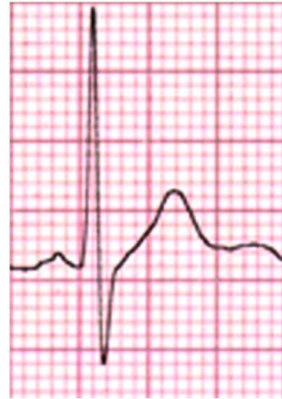V1



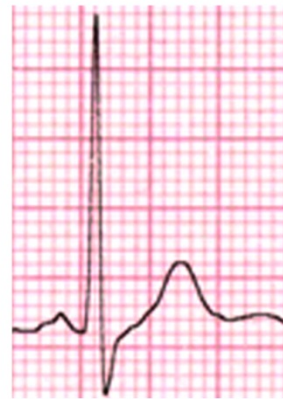V2



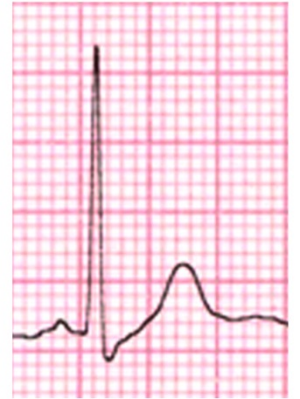V3



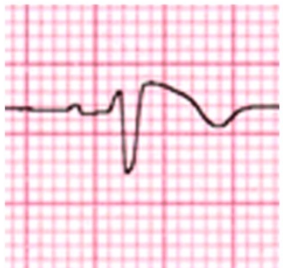
V4



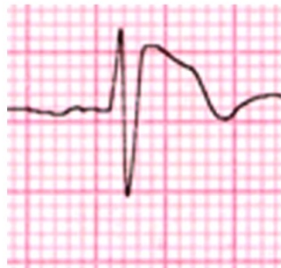V5



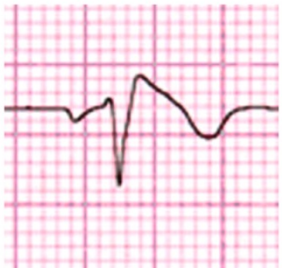V6



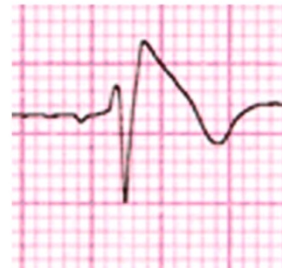V1 3rd i.s.



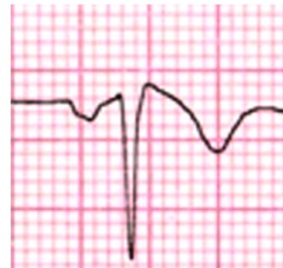V1 3rd i.s.



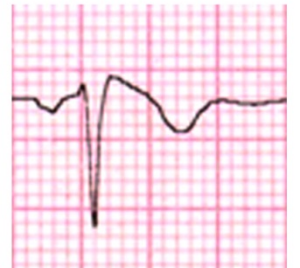V1 2nd i.s.



V2 2nd i.s.



II inverted
mirror image



aVF inverted
mirror image

Mirror
image

II

III

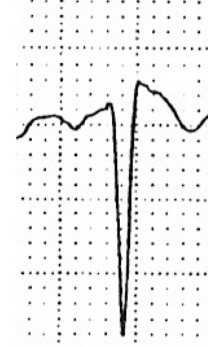
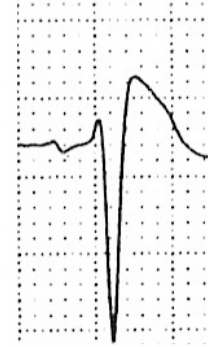
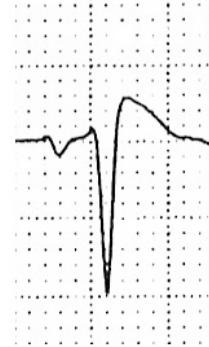
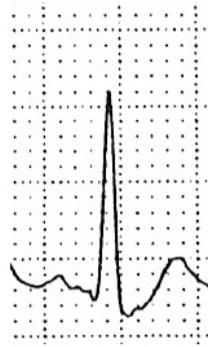
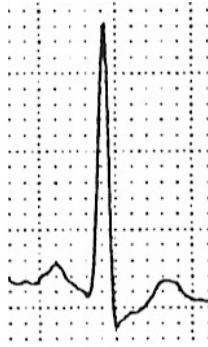
aVF

V1

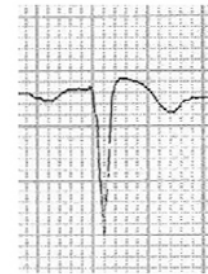
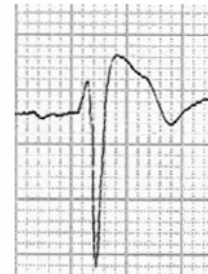
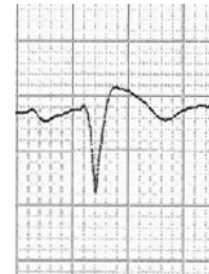
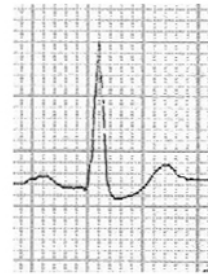
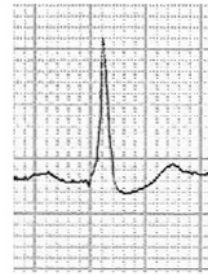
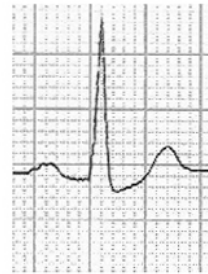V2

aVF

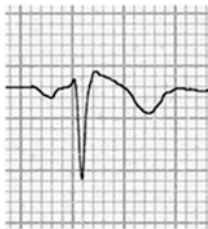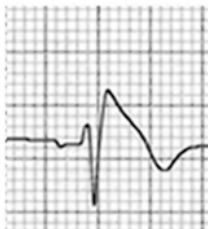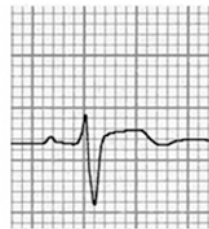
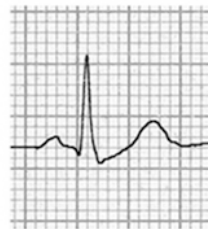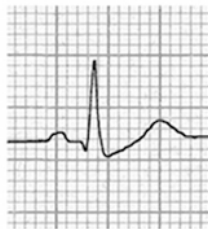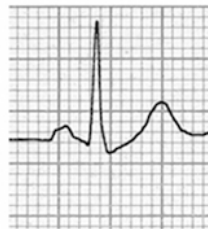A



B



C



V1

2nd I.S.

A New Electrocardiographic Marker of Sudden Death in Brugada Syndrome



The S-Wave in Lead I

Leonardo Calò, MD,^a Carla Giustetto, MD,^b Annamaria Martino, MD,^a Luigi Sciarra, MD,^a Natascia Cerrato, MD,^b Marta Marziali, MD,^a Jessica Rauzino, MD,^c Giulia Carlino, MD,^d Ermenegildo de Ruvo, MD,^a Federico Guerra, MD,^e Marco Rebecchi, MD,^a Chiara Lanzillo, MD, PhD,^a Matteo Anselmino, MD,^b Antonio Castro, MD,^f Federico Turreni, MD,^f Maria Penco, MD,^d Massimo Volpe, MD,^c Alessandro Capucci, MD,^e Fiorenzo Gaita, MD^b

ABSTRACT

BACKGROUND Risk stratification in asymptomatic patients remains by far the most important yet unresolved clinical problem in the Brugada syndrome (BrS).

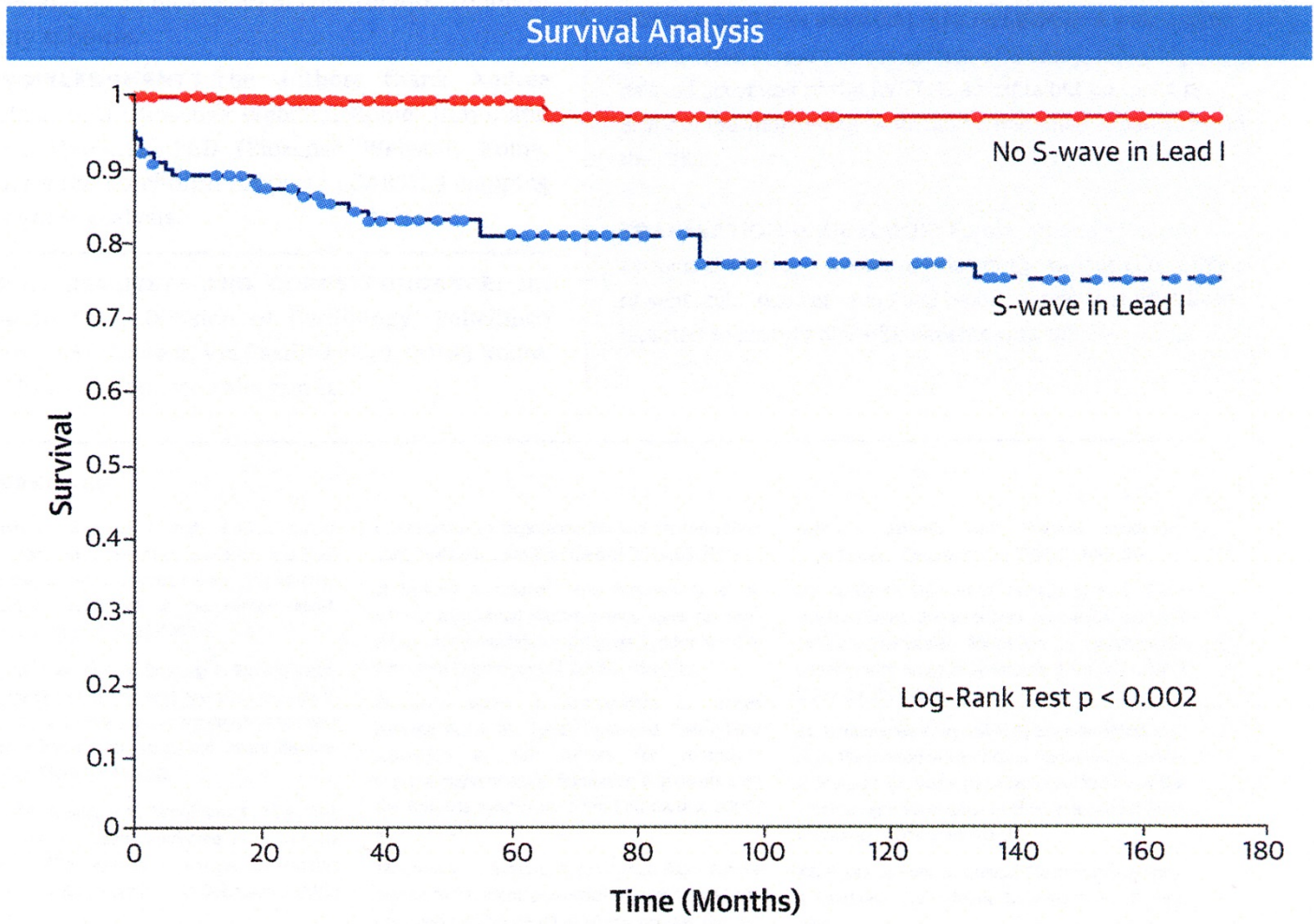
OBJECTIVES This study sought to analyze the usefulness of electrocardiographic parameters as markers of sudden cardiac death (SCD) in BrS.

METHODS This study analyzed data from 347 consecutive patients (78.4% male; mean age 45 ± 13.1 years) with spontaneous type 1 BrS by ECG parameters but with no history of cardiac arrest (including 91.1% asymptomatic at presentation, 5.2% with a history of atrial fibrillation [AF], and 4% with a history of arrhythmic syncope). Electrocardiographic characteristics at the first clinic visit were analyzed to predict ventricular fibrillation (VF)/SCD during follow-up.

RESULTS During the follow-up (48 ± 38 months), 276 (79.5%) patients remained asymptomatic, 39 (11.2%) developed syncope, and 32 (9.2%) developed VF/SCD. Patients who developed VF/SCD had a lower prevalence of *SCN5A* gene mutations ($p = 0.009$) and a higher prevalence of positive electrophysiological study results ($p < 0.0001$), a family history of SCD ($p = 0.03$), and AF ($p < 0.0001$). The most powerful marker for VF/SCD was a significant S-wave (≥ 0.1 mV and/or ≥ 40 ms) in lead I. In the multivariate analysis, the duration of S-wave in lead I ≥ 40 ms (hazard ratio: 39.1) and AF (hazard ratio: 3.7) were independent predictors of VF/SCD during follow-up. Electroanatomic mapping in 12 patients showed an endocardial activation time significantly longer in patients with an S-wave in lead I, mostly because of a significant delay in the anterolateral right ventricular outflow tract.

CONCLUSIONS The presence of a wide and/or large S-wave in lead I was a powerful predictor of life-threatening ventricular arrhythmias in patients with BrS and no history of cardiac arrest at presentation. However, the prognostic value of a significant S-wave in lead I should be confirmed by larger studies and by an independent confirmation cohort of healthy subjects. (J Am Coll Cardiol 2016;67:1427-40) © 2016 by the American College of Cardiology Foundation. healthy subjects. (J Am Coll Cardiol 2016;67:1427-40) © 2016 by the American College of Cardiology Foundation.

CENTRAL ILLUSTRATION Brugada Syndrome: A New Marker of Sudden Death



Calò, L. et al. J Am Coll Cardiol. 2016; 67(12):1427-40.

Kaplan-Meier analysis of freedom from ventricular fibrillation/sudden cardiac death events during follow-up in patients with S waves in lead I versus those without S waves in lead I.

ADVANCES IN CARDIAC
ARRHYTHMIAS
and
GREAT INNOVATIONS
IN CARDIOLOGY


GRAZIE!

Scientific Committee

Malcolm R. Bell, Usa
Martin Borggrefe, Germany
Leonardo Calò, Italy
Jean François Leclercq, France
Amir Lerman, Usa
Dipen Shah, Switzerland

Organization Committee

Matteo Anselmino, Italy
Carlo Budano, Italy
Davide Castagno, Italy



The BRUGADA ECG PATTERN
Giuseppe Oreto