

**JMC - 5° JOINT MEETING WITH MAYO  
CLINIC: GREAT INNOVATIONS IN  
CARDIOLOGY  
Turin, 15-16/10/09**

**UNSOLVED ISSUES IN ACS**

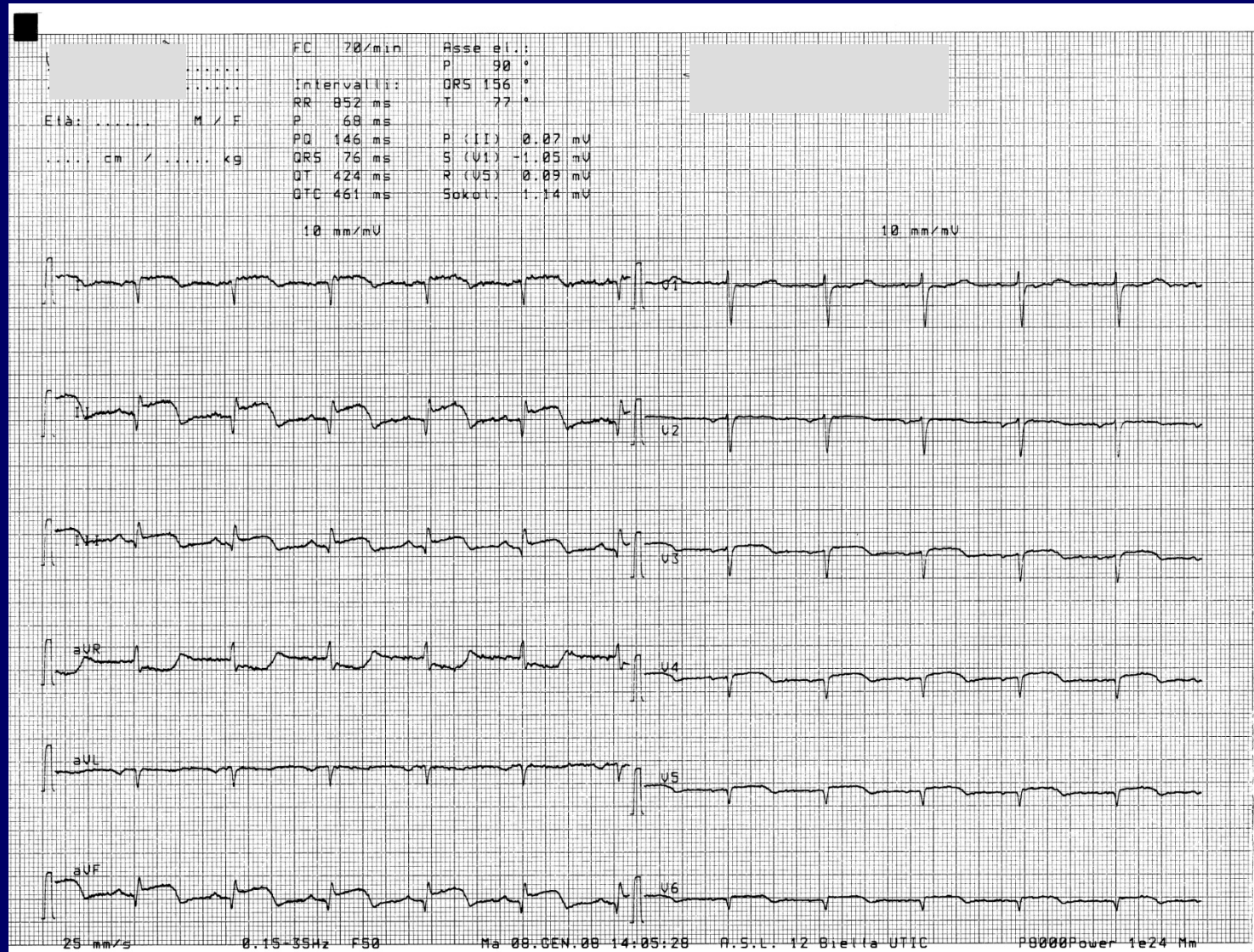


**Dr. A. Truffa Giachet  
S.C. Cardiologia  
ASL BI Biella**

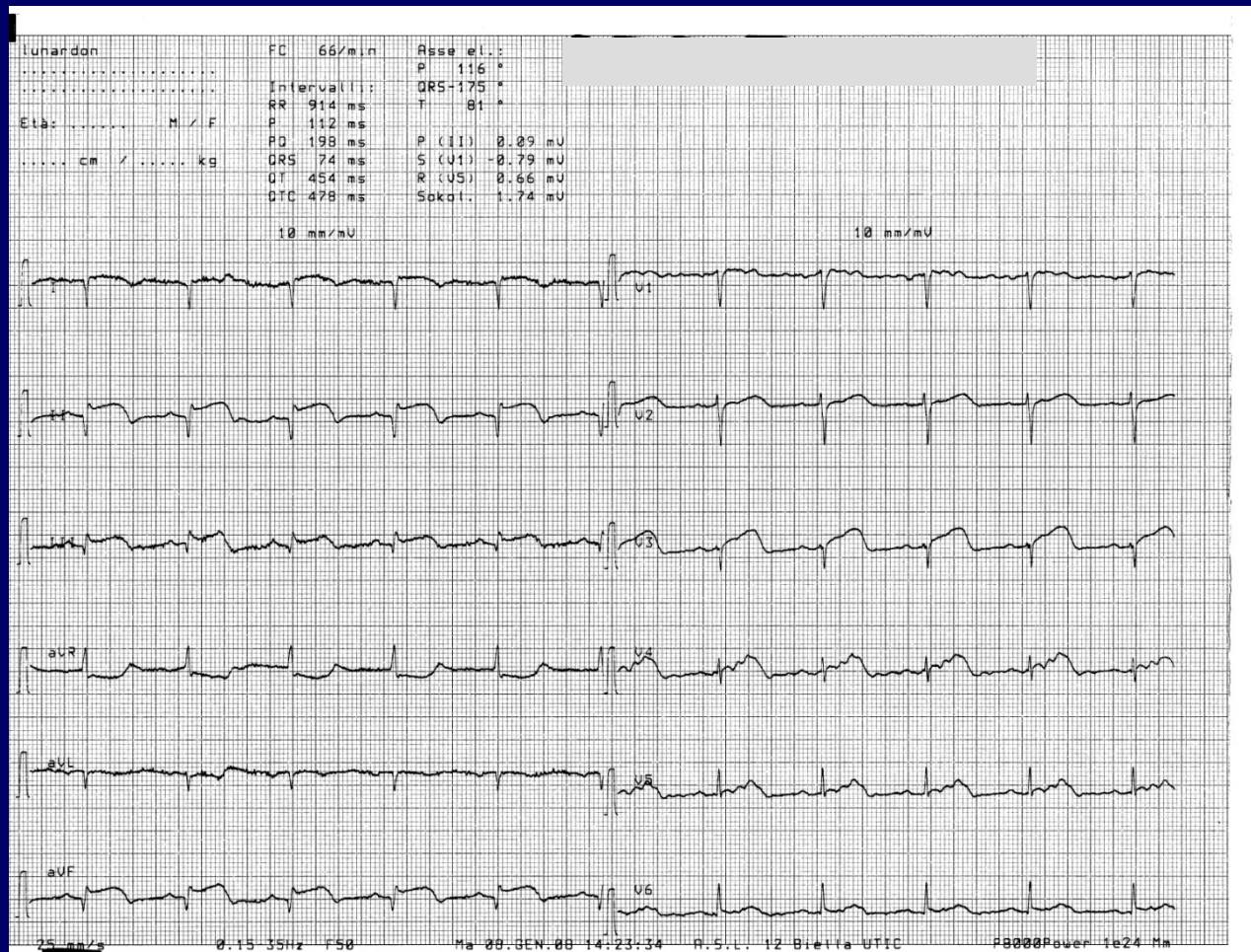
## CLINICAL CASE

- ♥ 52 year old woman, smoker, with history of hypertension, type 2 diabetes mellitus, dyslipidemia, overweight and a family history of ischaemic heart disease
- ♥ She was admitted to the emergency room with chest pain at rest for the last two hours
- ♥ Her surface ekg showed ST elevation in infero-lateral leads, low R wave voltages in the anterolateral leads, a QS complex and negative P wave in D1-aVL when conventional lead placement was used

# EKG ON ADMISSION

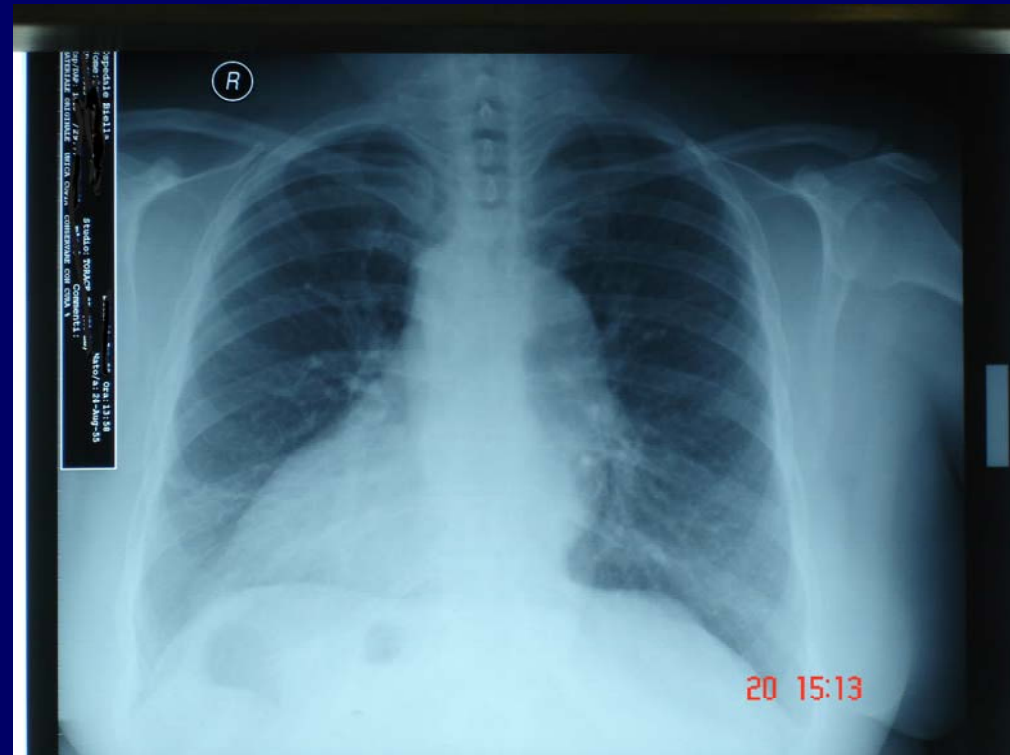


After chest leads were placed on the right side the inferior ST elevation remained but the anterolateral leads showed larger R wave voltages and lateral ST elevation



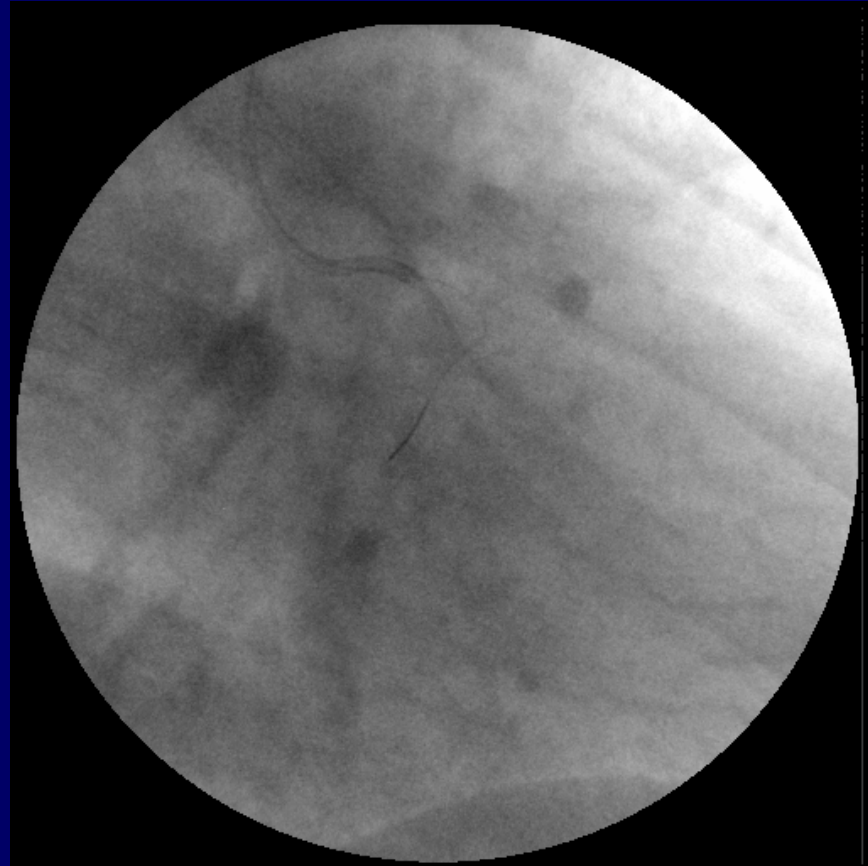
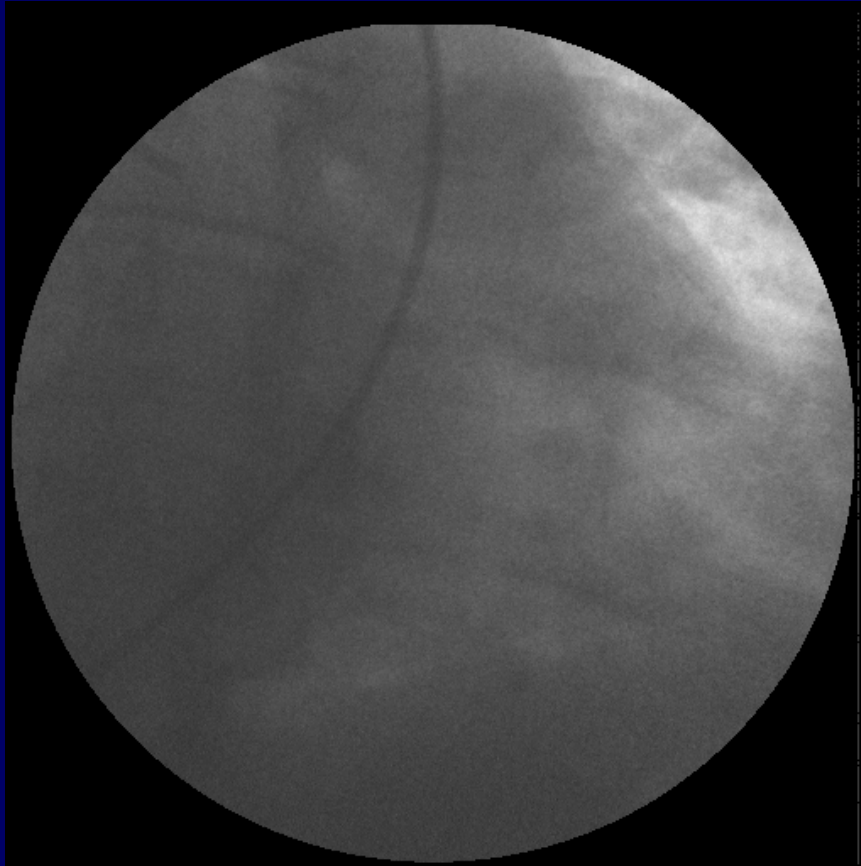
## CHEST X-RAYS

- cardiac apex is right sided
- gastric bubble on the right of the body
- Liver shadow on the left of the body



- ♥ Clinical examination showed a right-sided point of maximal impulse, with the liver edge palpable at the left side of the body
- ♥ The diagnosis was acute myocardial infarction in dextrocardia with situs inversus totalis
- ♥ Initial management with: unfractionated heparin 5000 UI, abiciximab bolus + infusion, clopidogrel 300 mg, aspirin 300 mg
- ♥ Cardiac catheterization was performed via the left common femoral artery using 6 Fr left Judkins (for the left coronary artery) and left Amplatz catheter (for the right coronary artery)

# CORONAROGRAPHY

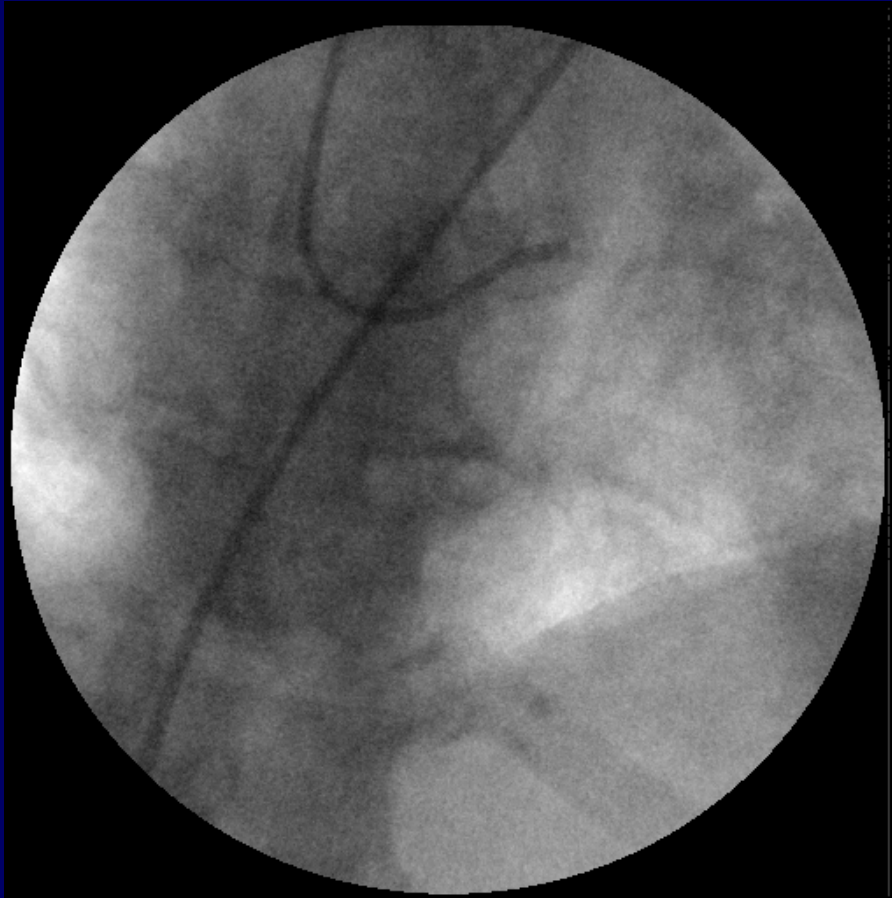


# CARDIAC CATHETERISATION

- ♥ The anatomical left and right coronary arteries originated from the same sinus of Valsalva (right sinus of Valsalva)
- ♥ The left coronary artery was normal
- ♥ The dominant right coronary artery was occluded in the middle portion
- ♥ PTCA for this lesion was performed with thrombus aspiration and deployment of a bare metal stent 3.0-24 at 16 atm

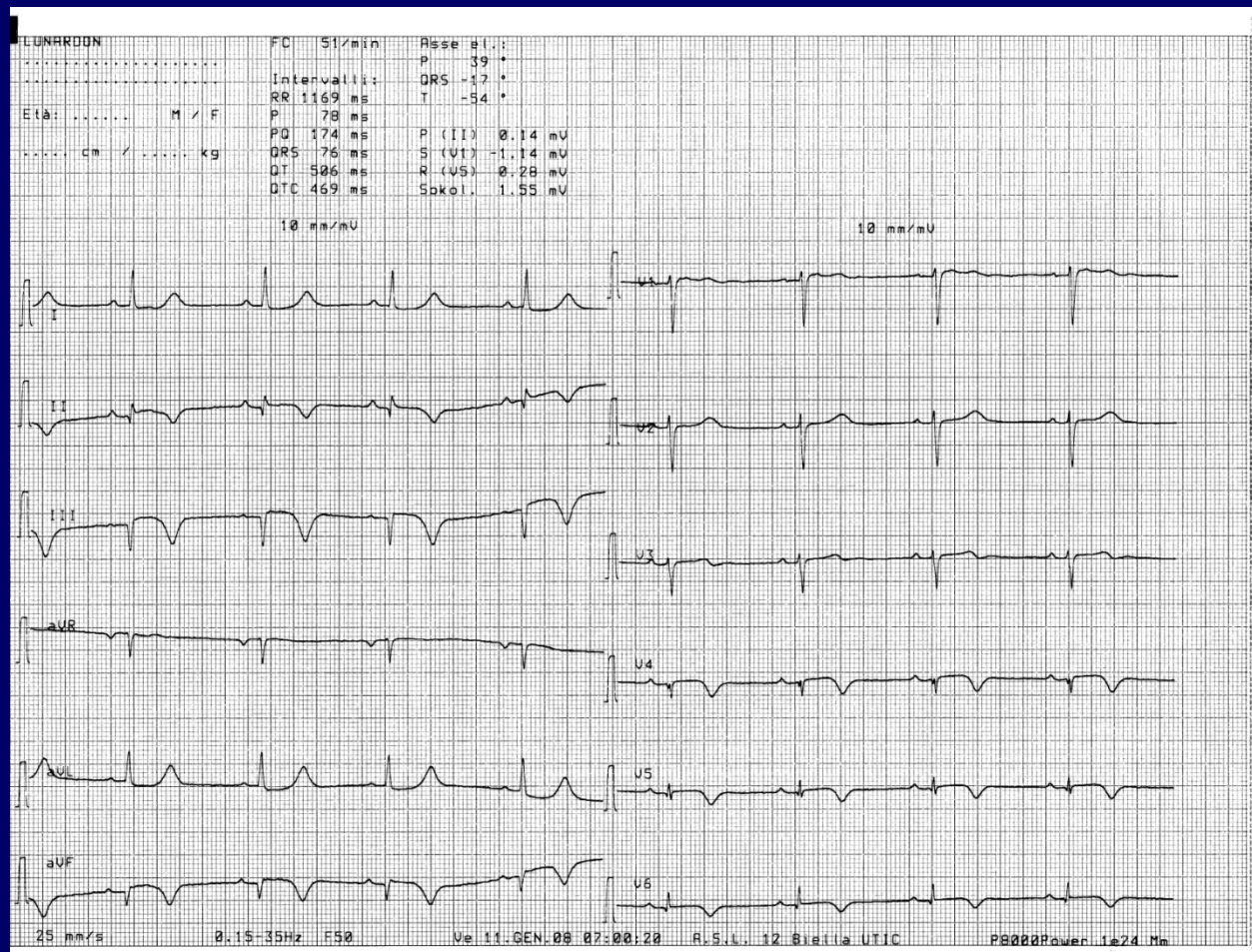


## POST-PCI OF RCA



The position of the X-ray image intensifier relative to the patient was inverted to obtain a "normal image" (no "mirror image") with a left-sided apex.

The patient had an uncomplicated clinical course with complete resolution of ST-segment elevation and she left the hospital on clopidogrel 75 mg, aspirin 100 mg, ACE inhibitor, beta blockers, statin, proton pump inhibitors

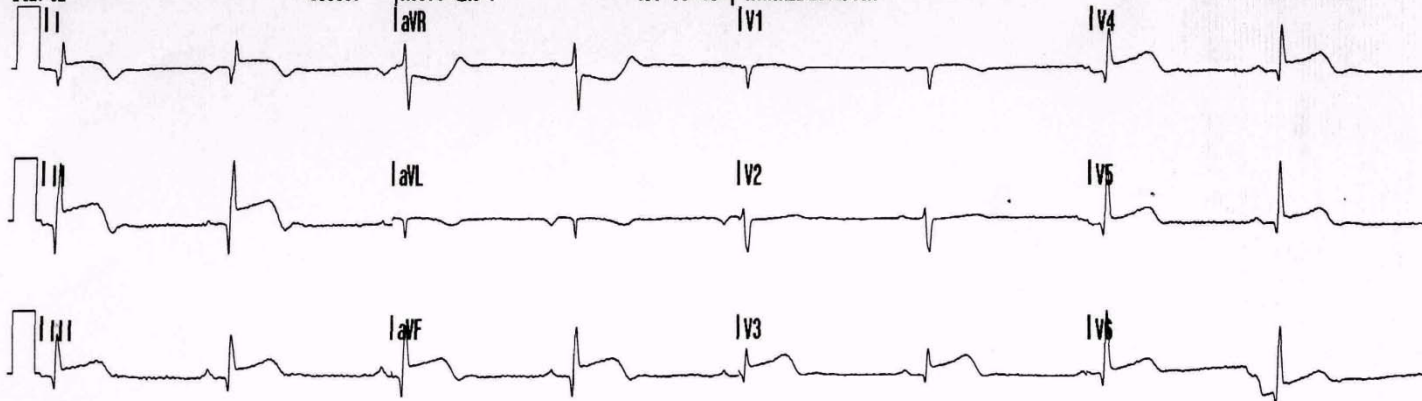


## .....AFTER ONE WEEK

- ♥ 7 days after the acute myocardial infarction, the patient suffered new prolonged chest pain
- ♥ EKG showed new ST segment elevation in infero-lateral leads where Q-waves were already present

# EKG ON ADMISSION

Nome: [REDACTED] | 12 derivazioni 1 | FC 47 bpm | \*\*\*\*\* INFARTO ACUTO \*\*\*\*\* | INFARTO LATERALE, POSSIBILMENTE ACUTO  
10:29:00 | ECG ANORMALE \*\*Non | INFARTO INFERIORE, POSSIBILMENTE ACUTO  
ID paziente: | PR 0.172s | QRS 0.078s | confermato\*\*  
Incidente: | QT/QTc | 0.408s/0.424s | ASSE PATIPICO, POSSIBILE BRADICARDIA  
Età: 52 | Sesso: | Assi P-QRS-T | 131° 73° 86° | ATRIALE ECTOPICA  
aVR | V1 | V4



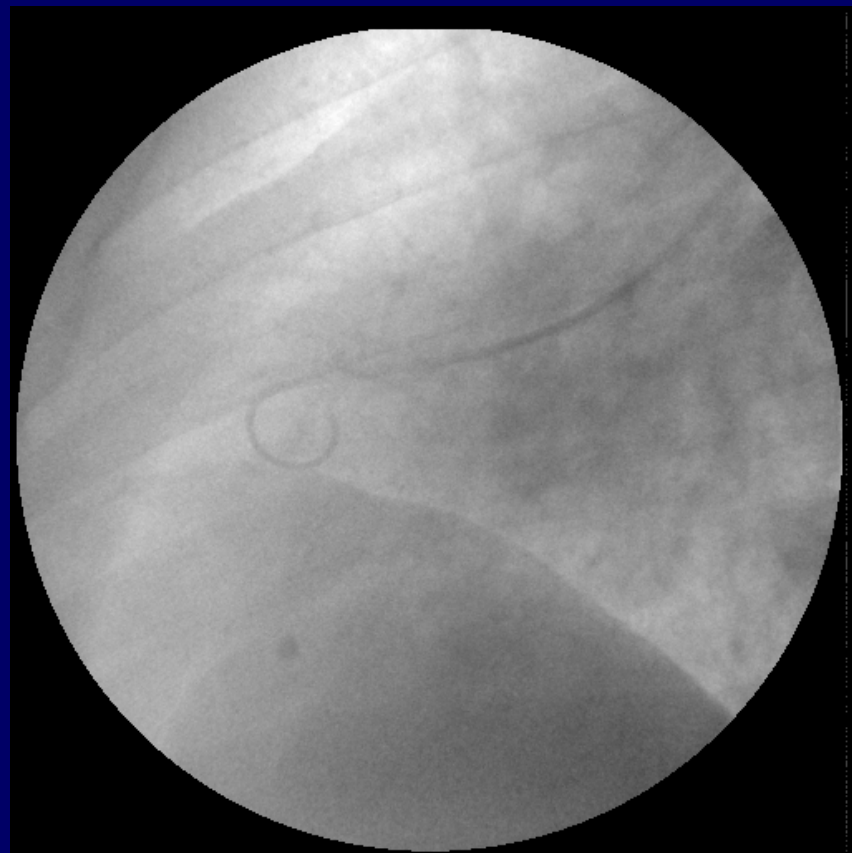
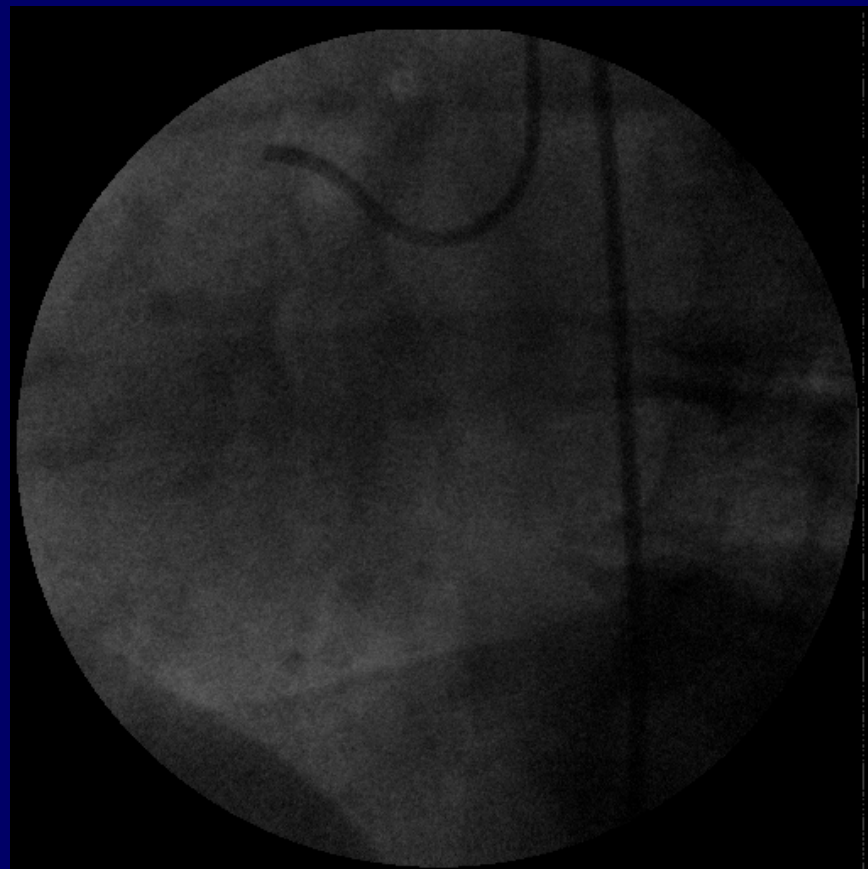x1, 0.05-40Hz 25mm/sec

000 000 3011371-090 0604KROK63C07P LP1212356443

## URGENT CARDIAC CATHETERISATION

- ♥ Subacute in-stent thrombosis of the middle portion of the right coronary artery was confirmed during coronarography
- ♥ The lesion was treated with multiple balloon inflations with semi-compliant and non-compliant balloons (diameter 2.0>3.5 mm)
- ♥ The patient was treated with a 300 mg clopidogrel re-loading dose and tirofiban bolus + infusion
- ♥ Ventriculography showed inferior akinesia, EF 50%

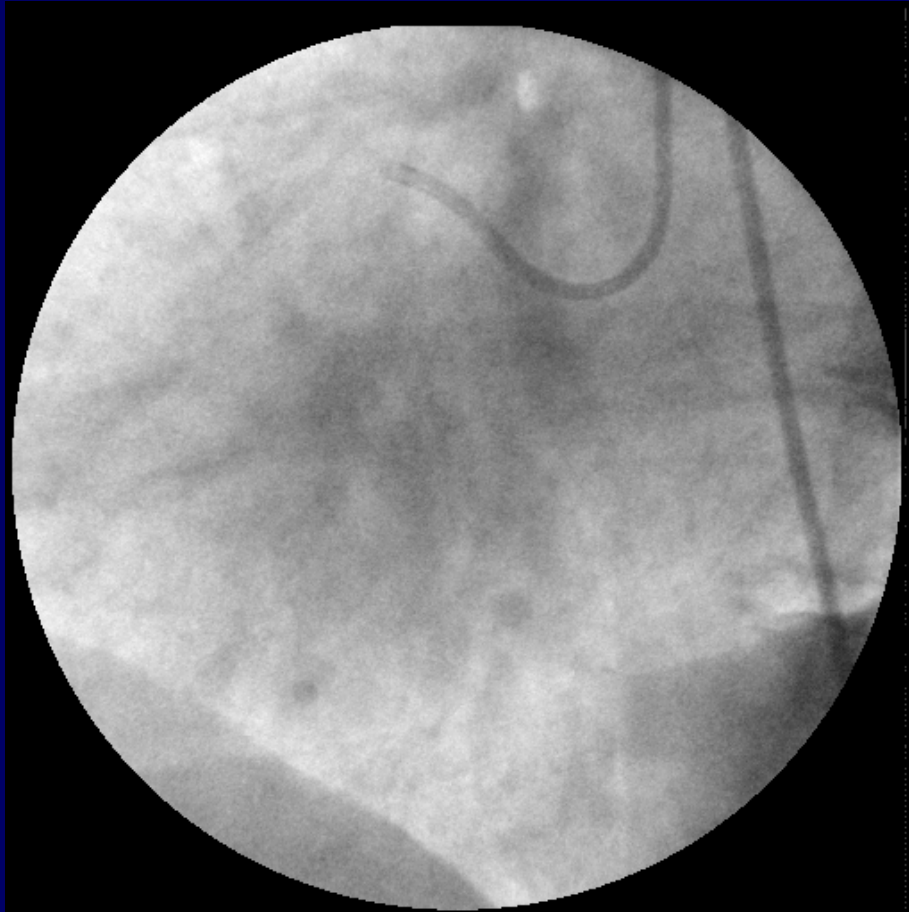
# CORONARO-VENTRICULOGRAPHY



# URGENT CARDIAC CATHETERISATION

- ♥ Subacute in-stent thrombosis of the middle portion of the right coronary artery was confirmed during coronarography
- ♥ The lesion was treated with multiple balloon inflations with semi-compliant and non-compliant balloons (diameter 2.0>3.5 mm)
- ♥ The patient was treated with a 300 mg clopidogrel re-loading dose and tirofiban bolus + infusion
- ♥ Ventriculography showed inferior akinesia, EF 50%

## POST-PCI OF RCA



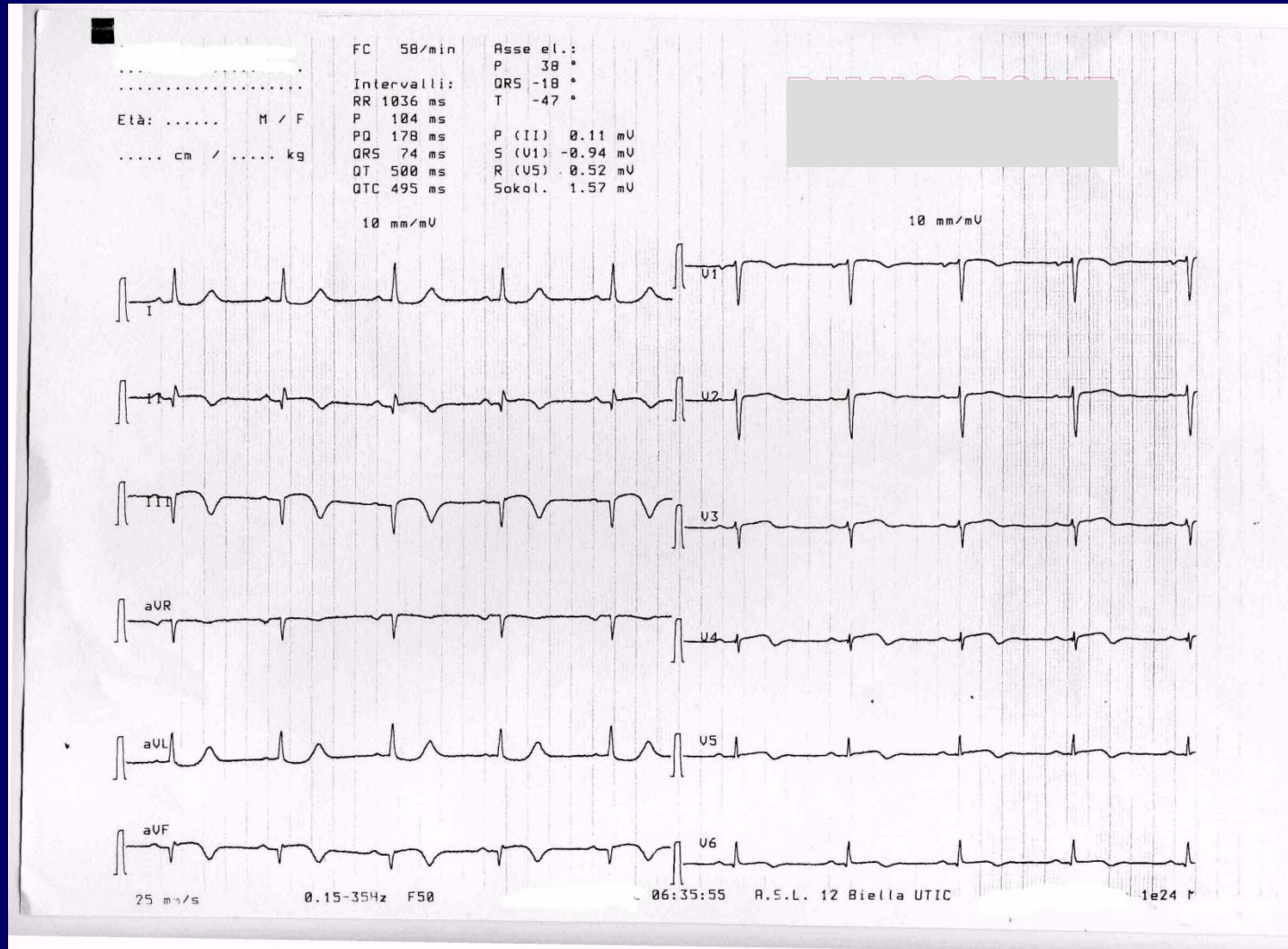
The position of the X-ray intensifier relative to the patient, in this case, was maintained as the mirror image of normal practise. This allowed normal manipulation of catheters.



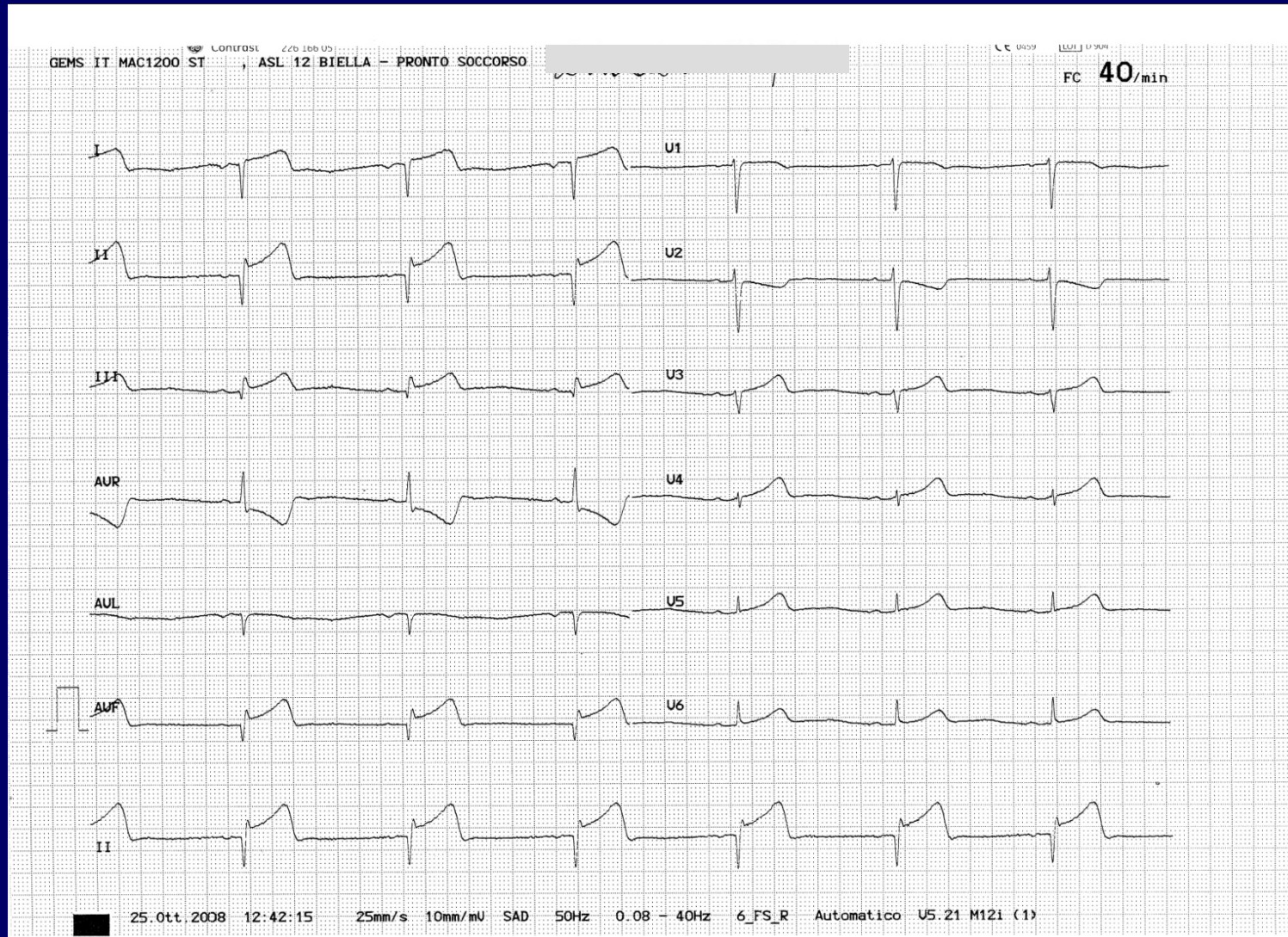
## CLINICAL COURSE

- ♥ Regular clinical course
- ♥ Echocardiography: normal left ventricle with postero-basal akinesia and EF 64%, mild mitral regurgitation
- ♥ After few days she was discharged on clopidogrel 75 mg, aspirin 100 mg, ACE inhibitor, beta blockers, statin and proton pump inhibitors. Total abstinence from smoking was suggested (she didn't stop smoking after the first hospitalization)

# EKG AT DISCHARGE



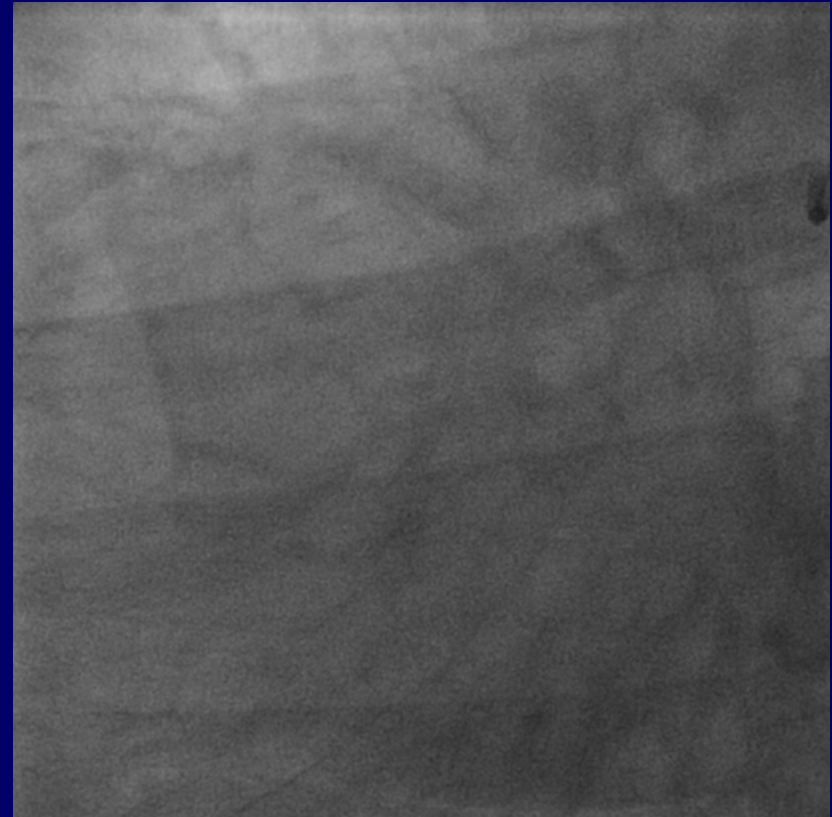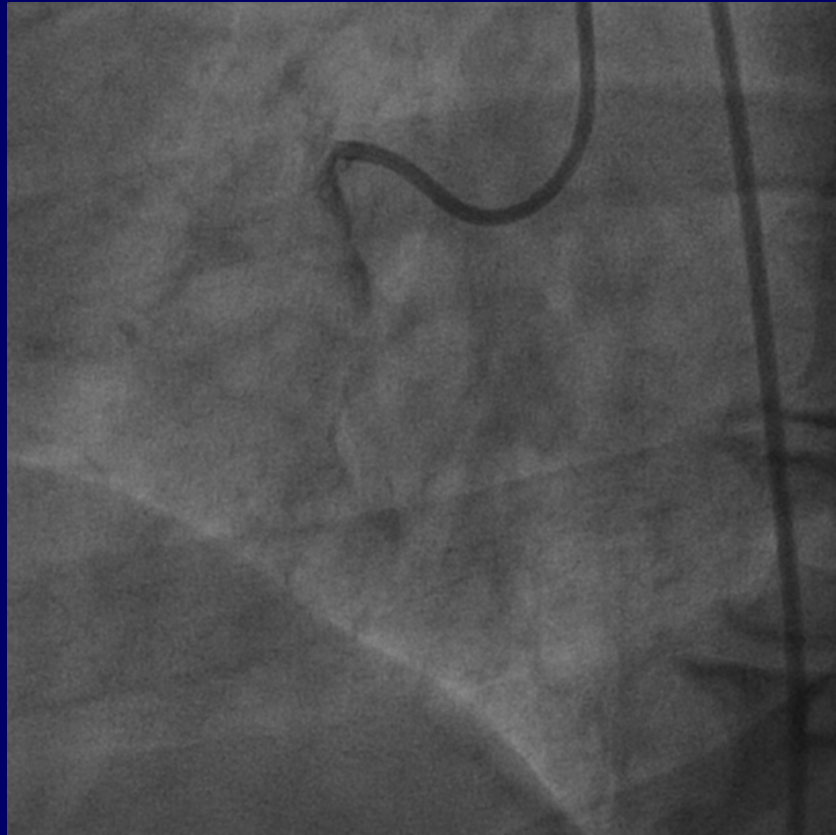
# Nine months after: recurrence of infero-lateral MI



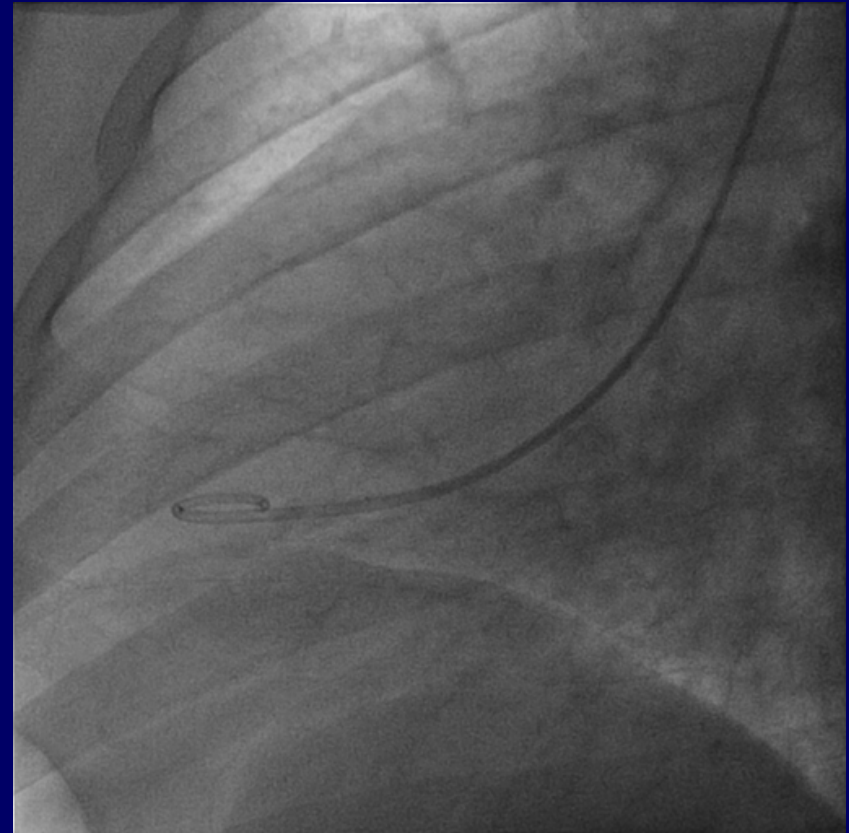
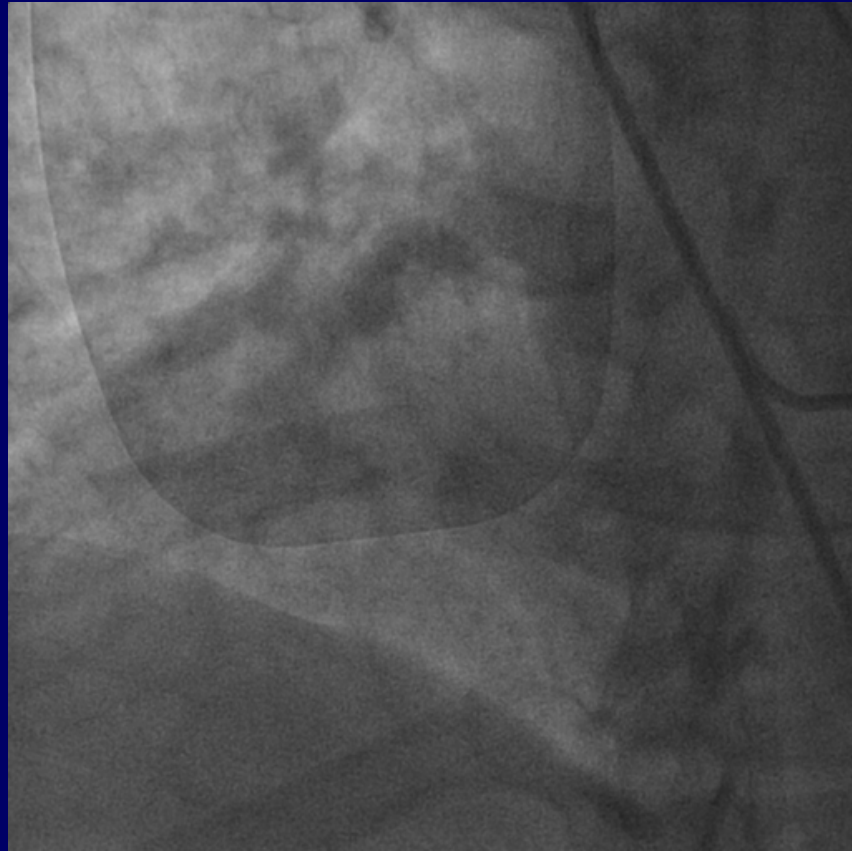
# URGENT CARDIAC CATHETERISATION

- ♥ Coronarography confirmed late stent thrombosis of the right coronary artery treated with POBA (multiple inflations with increasing in diameter balloons without other stent deployment) and final TIMI III flow
- ♥ She was treated with loading dose of clopidogrel 300 mg and abiciximab bolus + infusion

# CORONARO-VENTRICULOGRAPHY



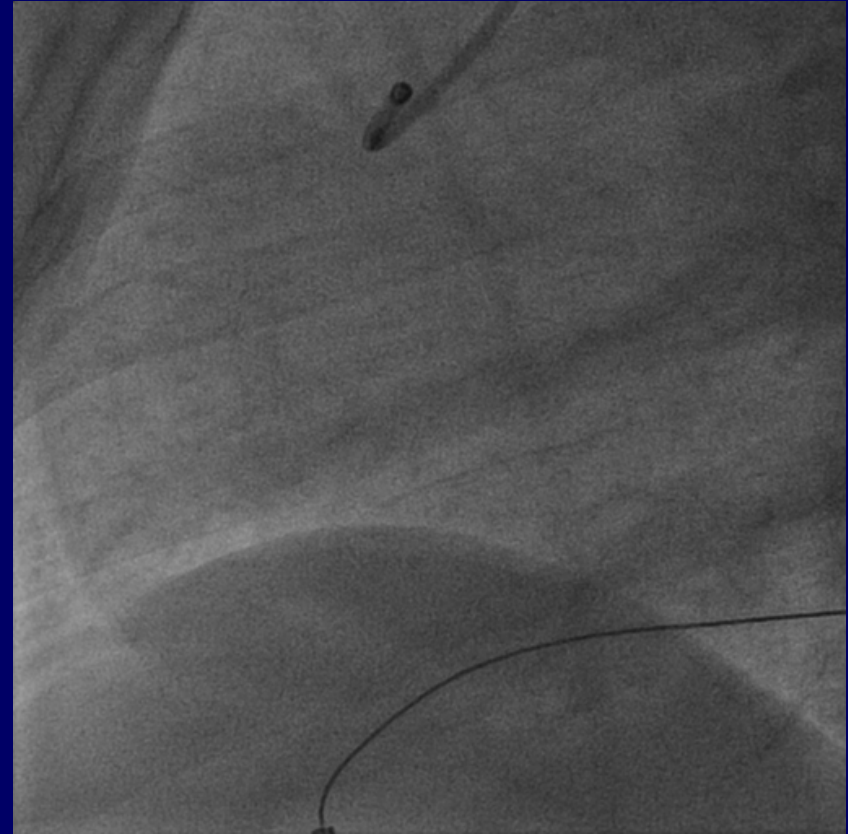
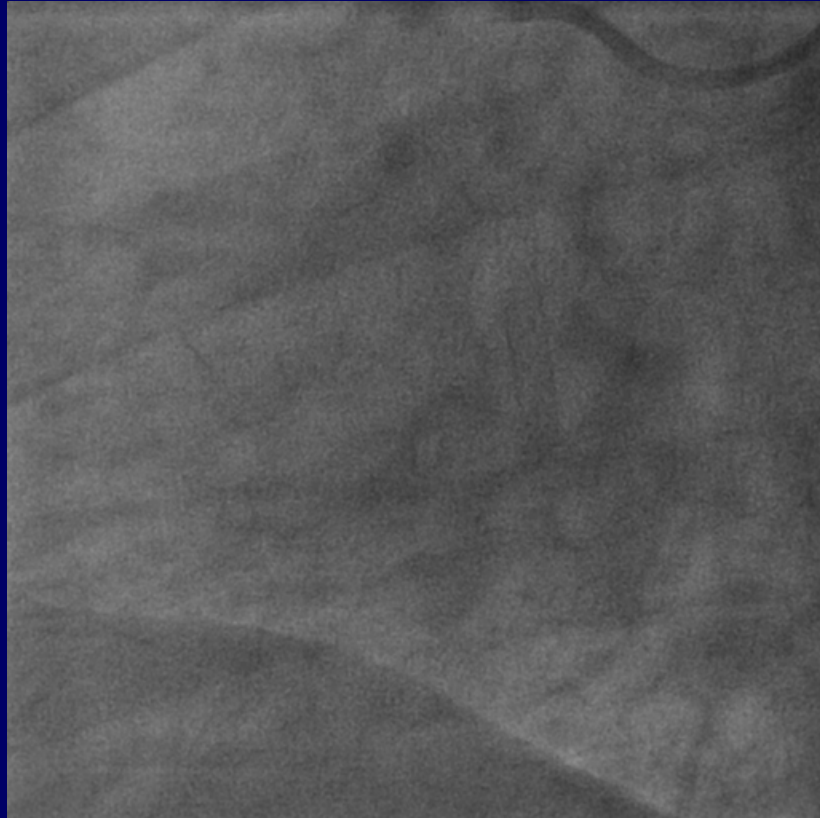
# CORONARO-VENTRICULOGRAPHY



# URGENT CARDIAC CATHETERISATION

- ♥ Coronarography confirmed late stent thrombosis of the right coronary artery treated with POBA (multiple inflations with increasing in diameter balloons without other stent deployment) and final TIMI III flow
- ♥ She was treated with loading dose of clopidogrel 300 mg and abiciximab bolus + infusion

# POST-PCI OF RCA





- ♥ Regular clinical course
- ♥ EF was normal (EF 60%)
- ♥ Coagulation screening showed: increase of coagulation factor VIII to 252% (n.v. 60-150) which is a prothrombotic factor
- ♥ Therapy at discharge: warfarin, aspirin 100 mg, clopidogrel 75 mg for 1 month, ACE inhibitor, beta blockers and statin
- ♥ At almost 12 months of follow up the patient is asymptomatic with a negative stress test

# CONCLUSIONS

1. Which is the probability of future events in this patient?
2. ST is a multifactorial problem related to patient, lesion, procedural factors and response to antiplatelet therapy
3. Early ST has been viewed as a problem related to the procedure itself (residual dissections, incomplete stent apposition)
4. Late ST depends more on the patient's risk profile, discontinuation of DAP therapy, impaired response to antiplatelet therapy

## CONCLUSIONS

1. Which may be the utility of platelet aggregation evaluation (ex. VerifyNow assay system)?
2. In cases of decreased response should we consider increasing to 600 mg the loading dose and to 150 mg the maintenance dose of clopidogrel or waiting for new drugs able to afford greater platelet inhibition like prasugrel and ticagrelor?
3. What do you think about warfarin association in this patient (considering the described coagulation disorder) ?

## Determinants of aspirin and clopidogrel response variability (ranges from 1% to 45% for the 2 drugs)

- ♥ Patient compliance
- ♥ Genetic polymorphisms that reduce the activation of the prodrug clopidogrel to its active state
- ♥ Female sex
- ♥ Older age
- ♥ Lower levels of hemoglobin
- ♥ Diabetes mellitus
- ♥ Elevated body mass index
- ♥ Smoking
- ♥ Concomitant use of PPI or drugs metabolized by cytP450 (?)

## How to overcome a decreased response?

- ♥ Increasing the dosage of aspirin has not shown to enhance patient's response
- ♥ Increasing to 600-mg the loading dose of clopidogrel and to 150 mg the maintenance dose (*Muller I et al. Effect of a high loading dose of clopidogrel on platelet function in patients undergoing coronary stent placement. Heart 2001;85(1):92-3. )*
- ♥ Using p450 enzyme-inducers to increase clopidogrel's active metabolite such as rifampin, a cytochrome p450 P3A4 inducer (*Lau WC et al. Contribution of hepatic cytochrome P450 3A4 metabolic activity to the phenomenon of clopidogrel resistance. Circulation 2004;109(2):166-71*)
- ♥ New drugs able to afford greater platelet inhibition: prasugrel, ticagrelor