



31 GIORNATE CARDIOLOGICHE TORINESI

TURIN
October
24th-26th
2019

Assessment of myocardial ischaemia: Coronary MDCT

Dott. A. Depaoli

***S.C.D.U.- Radiodiagnostica Universitaria, Direttore Prof. P. Fonio
Azienda Ospedaliera Universitaria Città della Salute e della scienza di Torino***



31 GIORNATE CARDIOLOGICHE

TURIN
October
24th-26th
2019

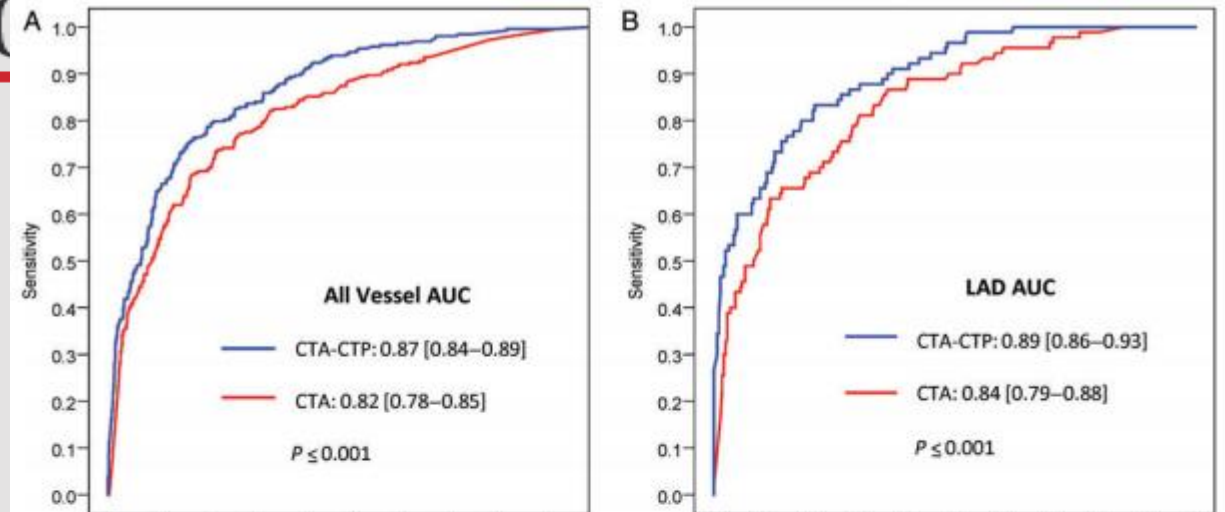
Stress CTP



European Heart Journal (2014) 35, 1120–1130
doi:10.1093/eurheartj/eh488

FASTTRACK CLINICAL RESEARCH

Computed tomography angiography and perfusion to assess coronary artery stenosis causing perfusion defects by single photon emission



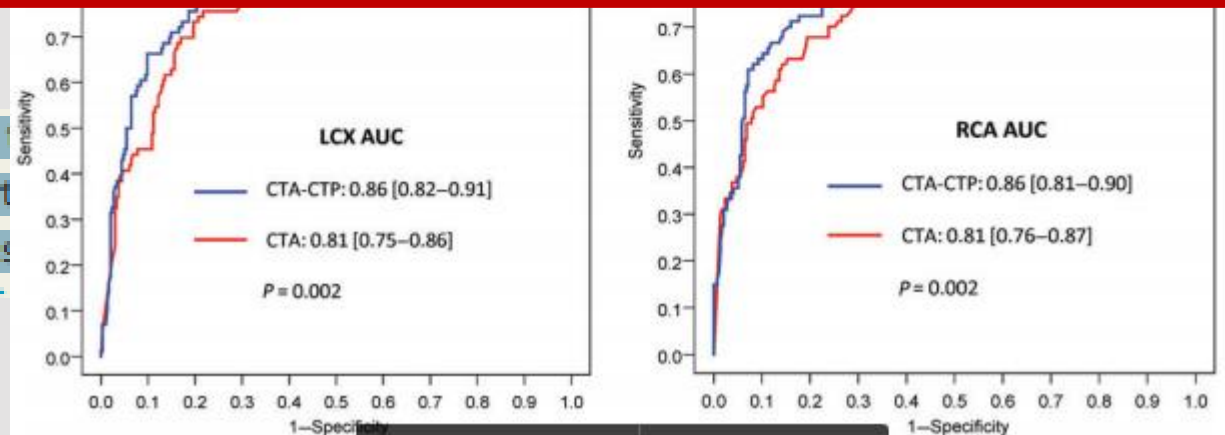
Conclusions

The combination of CTA and perfusion correctly identifies patients with flow limiting CAD defined as ≥ 50 stenosis by ICA causing a perfusion defect by SPECT/MPI.

Masanori Jinzaki^{1*}, Sachio Kuribayashi^{2*}, Albert de Roos^{3*}, Michael Laute^{4*}, Swee Yaw Tan¹⁵, John Hoe¹⁶, Narinder Paul¹⁷, Frank J. Rybicki³, Jeffery A. Brinker¹, Andrew E. Arai⁵, Christopher Cox², Melvin E. Clouse¹⁰, Marcelo F. Di Carli³, and

Aims

To evaluate the diagnostic power of integrating cardiac perfusion (CTP) to identify coronary artery disease (CAD) defined as a flow limiting coronary artery stenosis causing a perfusion defect by single photon emission computed tomography (SPECT).



Aims To evaluate the diagnostic power of integrating the results of computed tomography angiography (CTA) and CT myocardial perfusion (CTP) to identify coronary artery disease (CAD) defined as a flow limiting coronary artery stenosis causing a perfusion defect by single photon emission computed tomography (SPECT).



Stress CTP



European Heart Journal (2014) 35, 1120–1130
doi:10.1093/eurheartj/eh488

FASTTRACK CLINICAL RESEARCH

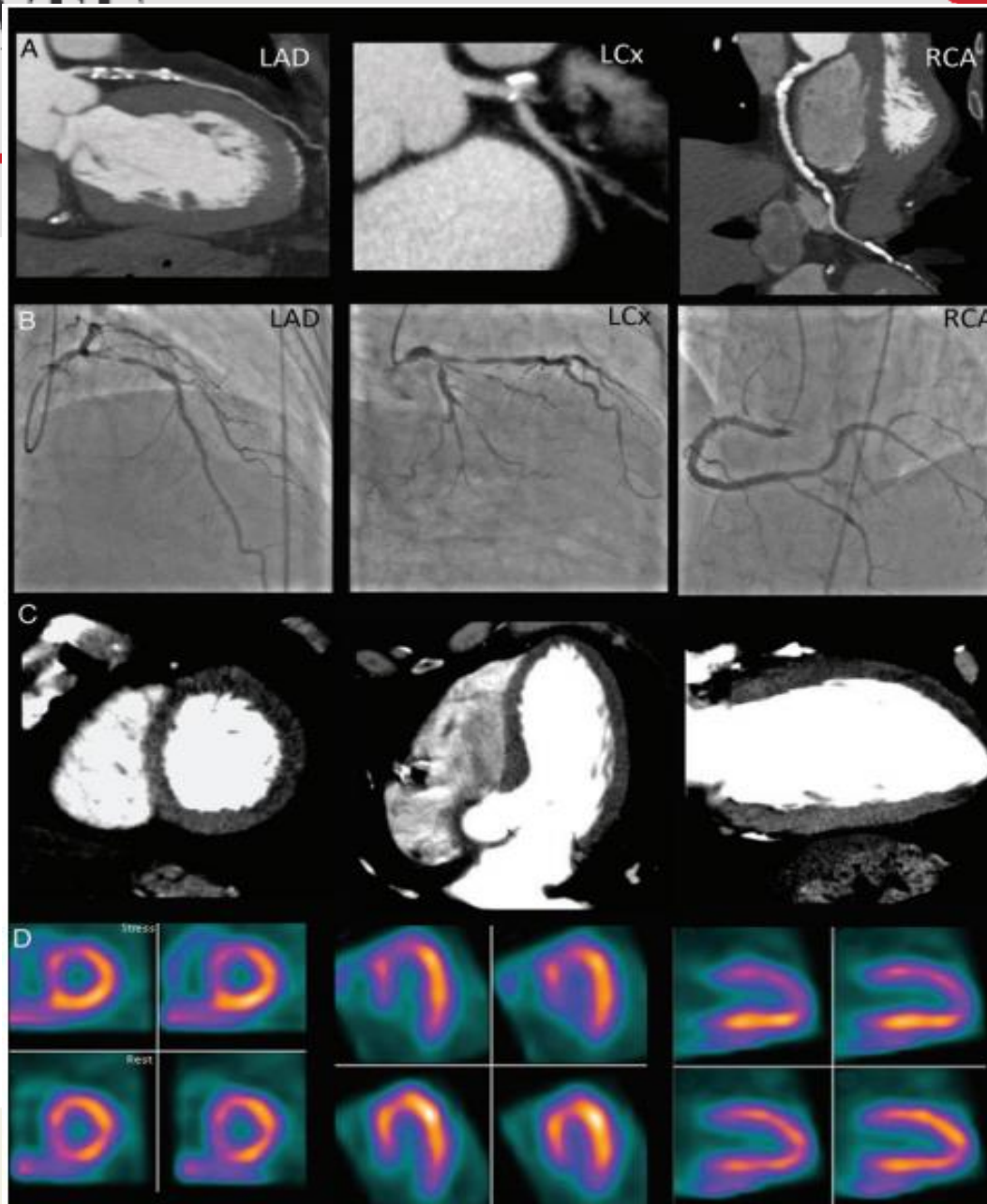
Computed tomography angiography and perfusion to assess coronary artery stenosis causing perfusion defects by single photon emission computed tomography: the CORE320 study

Carlos E. Rochitte^{4†}, Richard T. George^{1†}, Marcus Y. Chen⁵, Armin Arbab-Zadeh¹, Marc Dewey⁶, Julie M. Miller¹, Hiroyuki Niinuma^{7,8}, Kunihiro Yoshioka⁷, Kakuya Kitagawa⁹, Shiro Nakamori⁹, Roger Laham¹⁰, Andrea L. Vavere¹, Rodrigo J. Cerci¹, Vishal C. Mehra¹, Cesar Nomura¹¹, Klaus F. Kofoed¹², Masahiro Jinzaki¹³, Sachio Kuribayashi¹³, Albert de Roos¹⁴, Michael Laule⁶, Swee Yaw Tan¹⁵, John Hoe¹⁶, Narinder Paul¹⁷, Frank J. Rybicki³, Jeffery A. Brinker¹, Andrew E. Arai⁵, Christopher Cox², Melvin E. Clouse¹⁰, Marcelo F. Di Carli³, and Joao A.C. Lima^{1*}

¹Division of Cardiology, Department of Medicine, Johns Hopkins Hospital and School of Medicine, 600 N. Wolfe St., Blalock 524, Baltimore, MD 21287, USA; ²Johns Hopkins Bloomberg School of Public Health, Baltimore, MD, USA; ³Brigham and Women's Hospital, Boston, MA, USA; ⁴Heart Institute, InCor, University of Sao Paulo Medical School, São Paulo, Brazil; ⁵National Heart Lung and Blood Institute, National Institutes of Health, Bethesda, MD, USA; ⁶Charité Medical School, Humboldt, Berlin, Germany; ⁷Iwate Medical University, Morioka, Japan; ⁸St Luke's International Hospital, Tokyo, Japan; ⁹Mie University Hospital, Tsu, Japan; ¹⁰Beth Israel Deaconess Medical Center, Harvard University, Boston, MA, USA; ¹¹Albert Einstein Hospital, São Paulo, Brazil; ¹²University of Copenhagen, Denmark; ¹³Keio University, Tokyo, Japan; ¹⁴Leiden University Medical Center, Leiden, the Netherlands; ¹⁵National Heart Center, Singapore, Singapore; ¹⁶Mount Elizabeth Hospital, Singapore, Singapore; and ¹⁷Toronto General Hospital, Toronto, Canada

Received 5 August 2013; revised 21 October 2013; accepted 1 November 2013; online publish-ahead-of-print 19 November 2013

Aims To evaluate the diagnostic power of integrating the results of computed tomography angiography (CTA) and CT myocardial perfusion (CTP) to identify coronary artery disease (CAD) defined as a flow limiting coronary artery stenosis causing a perfusion defect by single photon emission computed tomography (SPECT).





31 GIORNATE CARDIOLOGICHE TORINESI

TURIN
October
24th-26th
2019

Stress CTP

Radiology

Purpose:

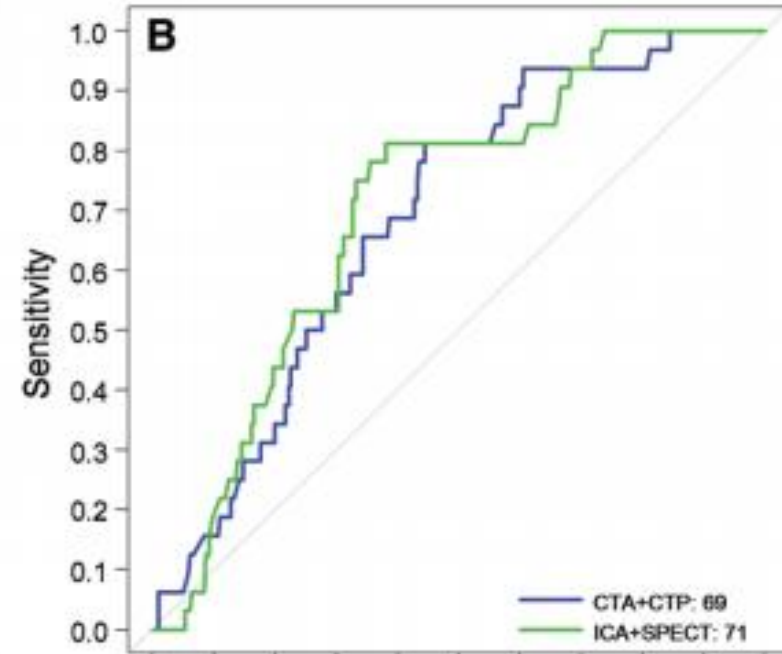
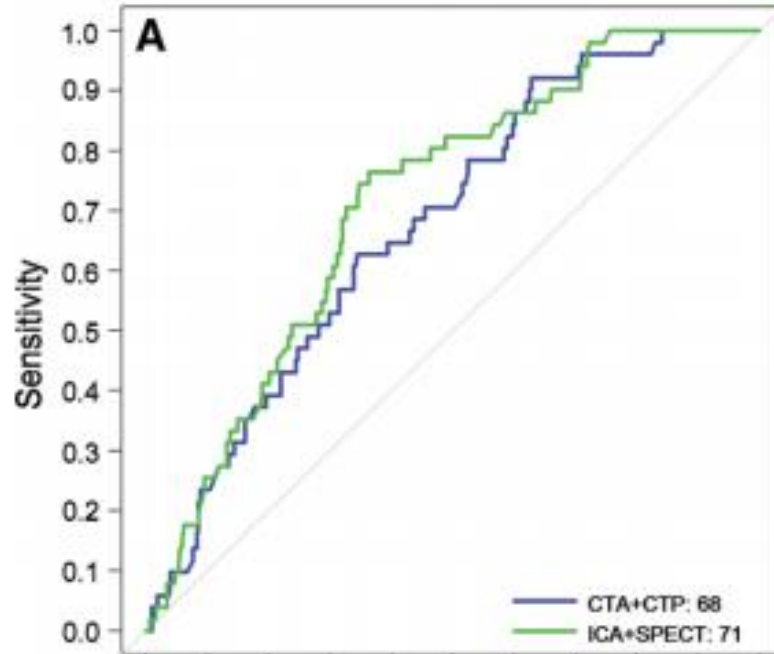
Marcus Y. Chen, MD
Carlos E. Rochitte, MD, PhD
Armin Arbab-Zadeh, MD, MPH, PhD
Marc Dewey, MD, PhD

Richard T.
Julie M. N.
Hiroyuki T.
Kunihiko
Kakuya K.
Hajime S.
Roger La.
Andrea L.
Rodrigo J.
Vishal C.
Cesar No.

For the CORE320 Investigators

Conclusion:

Combined CT angiography and CT perfusion enables similar prediction of 2-year MACE, late MACE, and event-free survival similar to that enabled by ICA and single photon emission CT.



plan-Meier curves and restricted mean survival times bootstrapped with 2000 replicates.



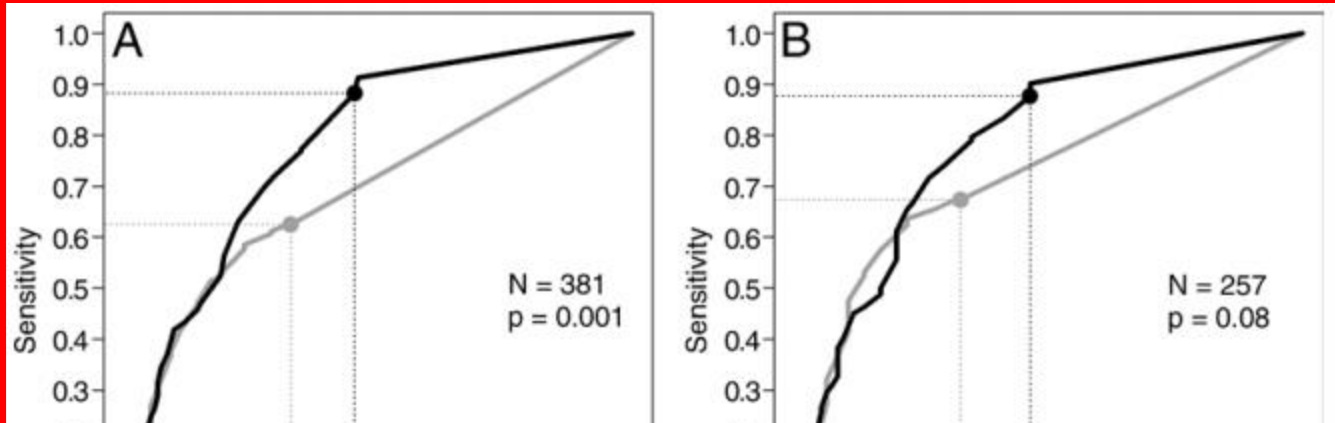
31 GIORNATE CARDIOLOGICHE TORINESI

TURIN
October
24th-26th
2019

Stress CTP

Radiology

Myocardial CT Perfusion



Richard T. George, MD
Vishal C. Mehra, MD, PhD
Marcus Y. Chen, MD
Kakuya Kitagawa, MD, PhD
Armin Arbab-Zadeh, MD, PhD
Julie M. Miller, MD
Matthew P. Matheson, MD

Conclusion:

The overall performance of myocardial CT perfusion imaging in the diagnosis of anatomic CAD (stenosis $\geq 50\%$), as demonstrated with the A_z , was higher than that of SPECT and was driven in part by the higher sensitivity for left main and multivessel disease.



31 GIORNATE CARDIOLOGICHE TORINESI

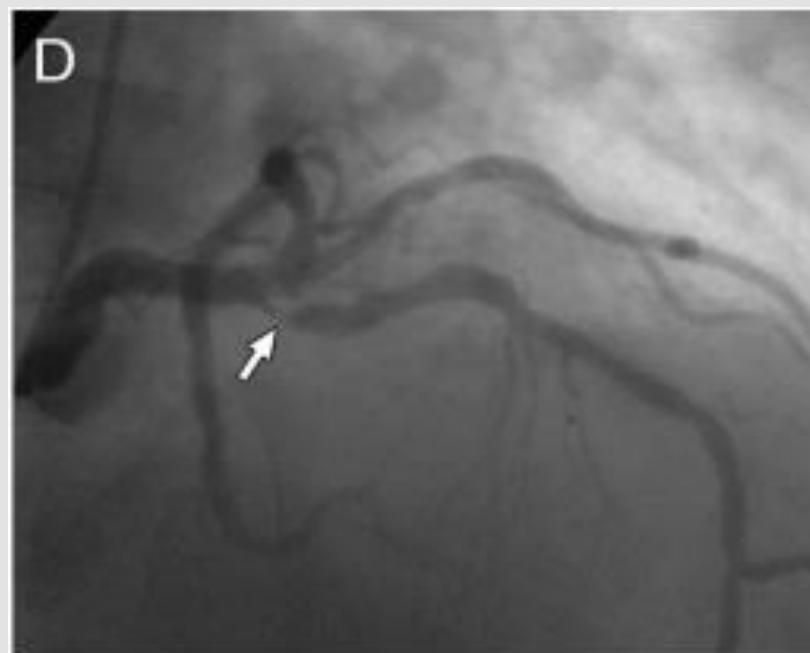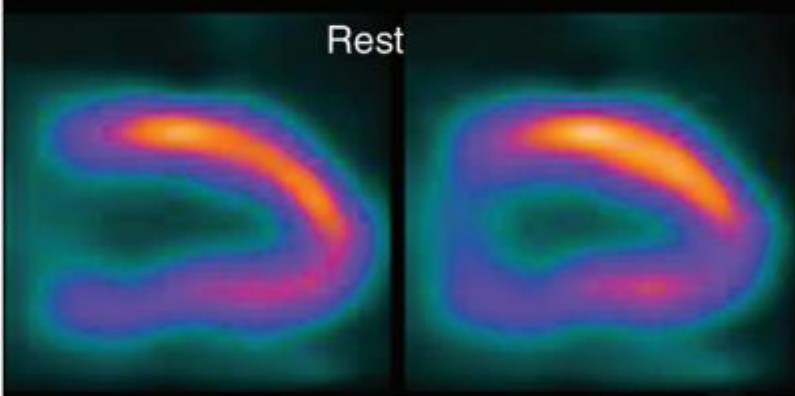
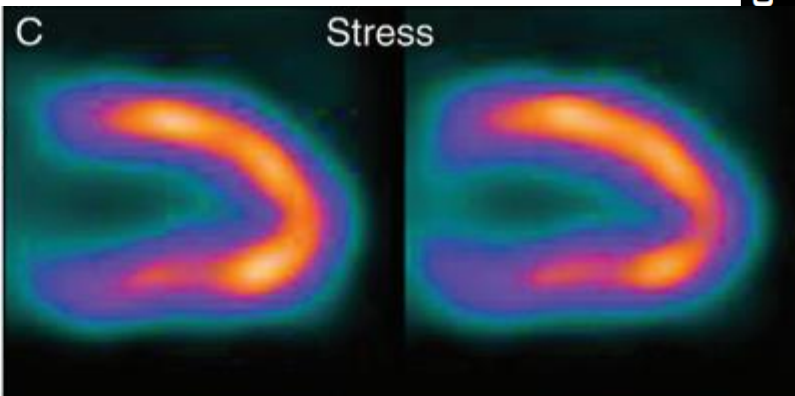
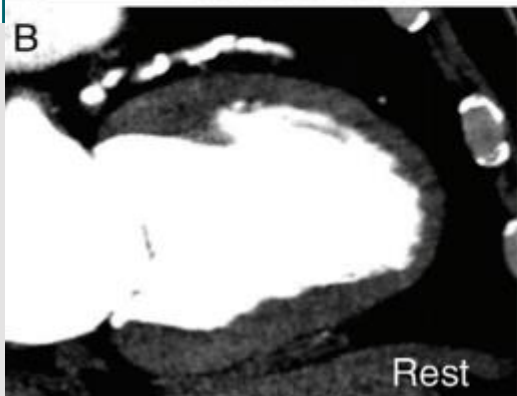
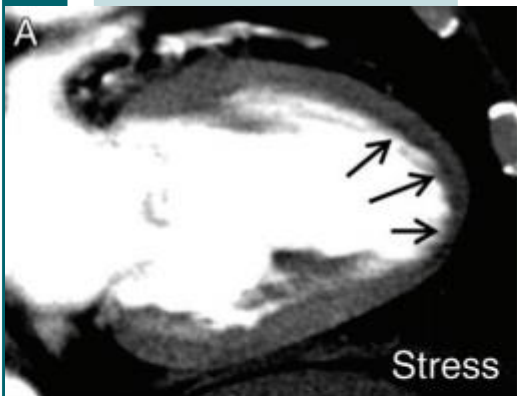
TURIN
October
24th-26th
2019

Stress CTP

Radiology

Myocardial CT Perfusion Imaging and SPECT for the Diagnosis of Coronary Artery Disease: A

ORIGINAL RESEARCH ■ CARD





31 GIORNATE CARDIOLOGICHE TORINESI

TURIN
October
24th-26th
2019



NEW GENERATION SCANNER

- ***HIGH SPATIAL AND TEMPORAL RESOLUTION***
- ***WHOLE HEART IN ONE BEAT***
- ***LOW DOSE***

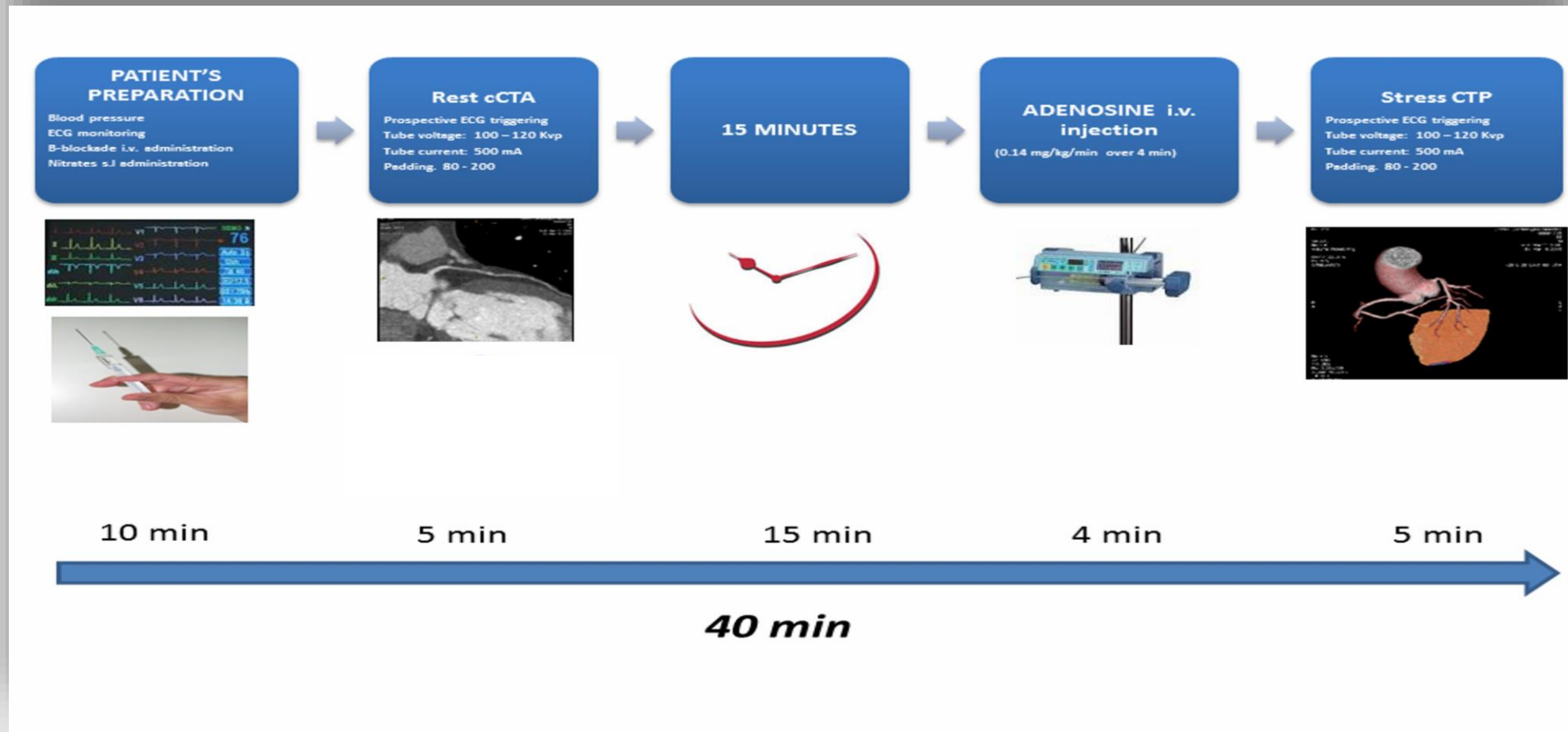


31 GIORNATE CARDIOLOGICHE TORINESI

TURIN
October
24th-26th
2019

Stress-CTP

«One-stop-shop»



References: Department of Cardiovascular Imaging, Centro Cardiologico Monzino - Milan/IT

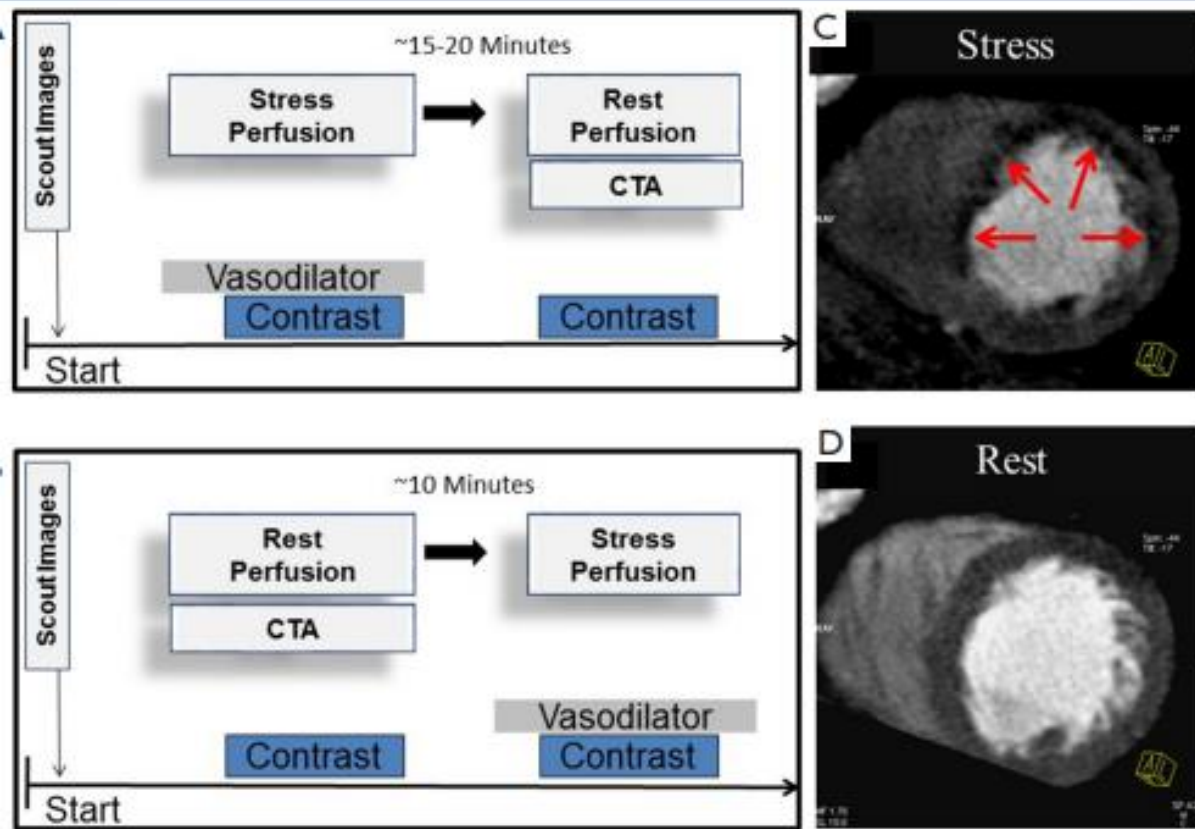


31 GIORNATE CARDIOLOGICHE TORINESI

TURIN
October
24th-26th
2019

Stress-CTP

Cardiac CT Myocardial Perfusion



Parameter	Favor Stress First	Favor Rest First
Low to intermediate pre-test probability of CAD		X
Severe amount of coronary artery calcifications	X	
Known prior CAD / PCI	X	
Prior MI	X	

Review Article

Myocardial computed tomography perfusion

Kelley R. Branch¹, Ryan D. Haley², Marcio Sommer Bittencourt^{3,4}, Amit R. Patel⁵, Edward Hulten², Ron Blankstein⁶



31 GIORNATE CARDIOLOGICHE TORINESI

TURIN
October
24th-26th
2019

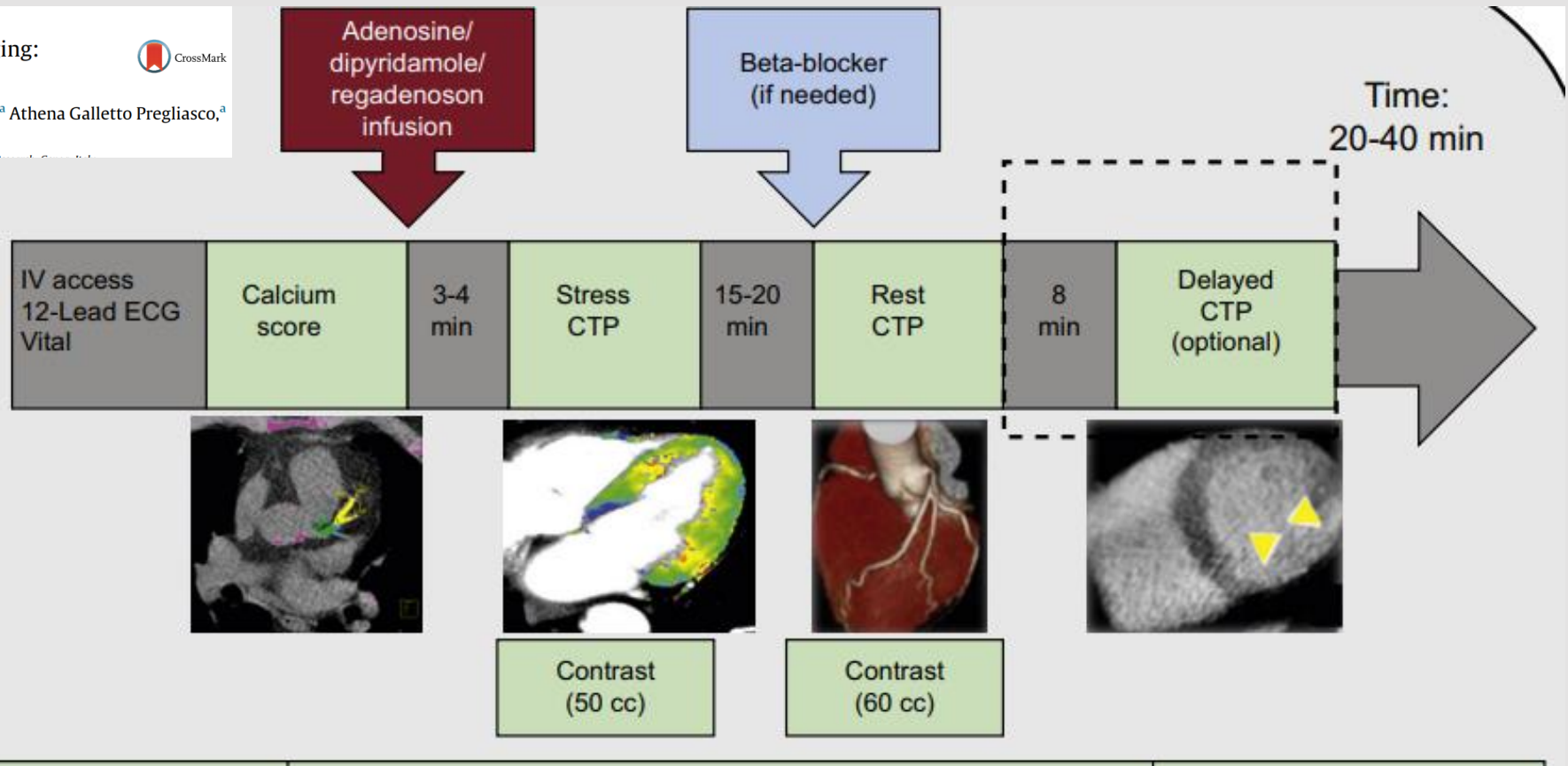
Stress-CTP

Review article

Stress Computed Tomography Myocardial Perfusion Imaging:
A New Topic in Cardiology



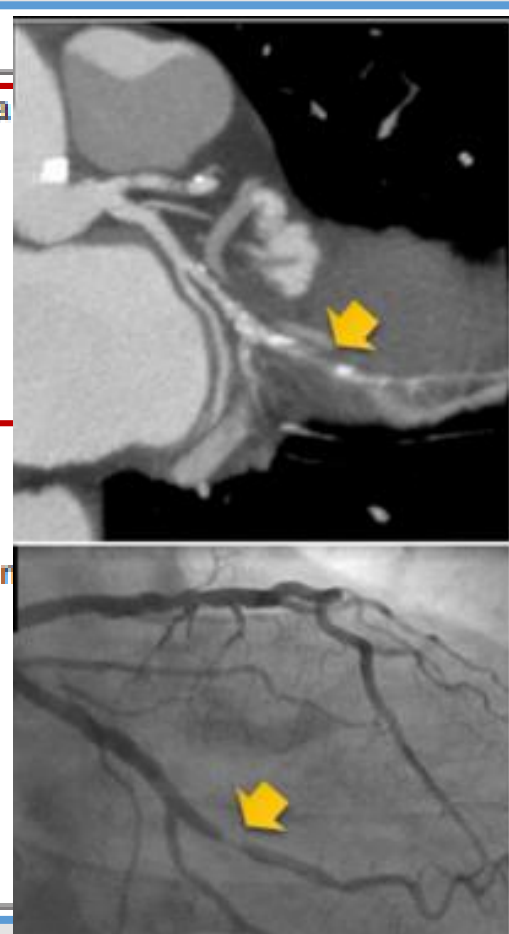
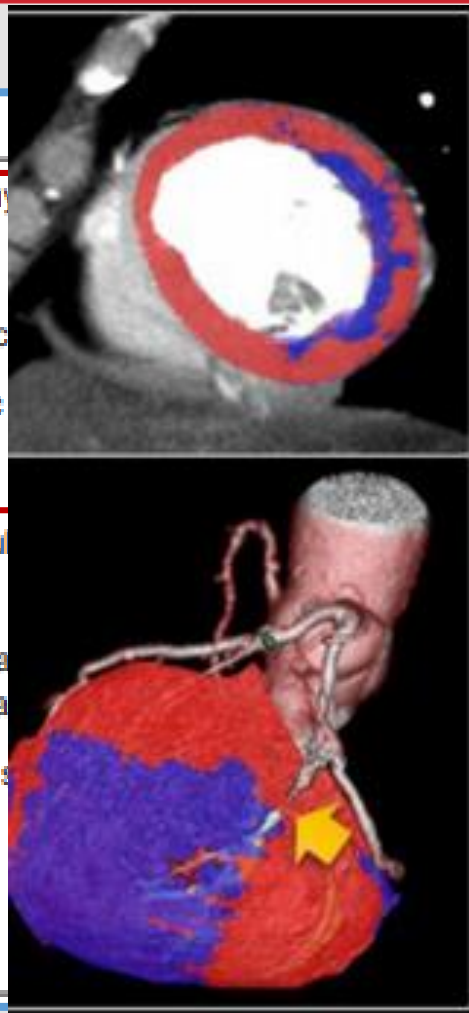
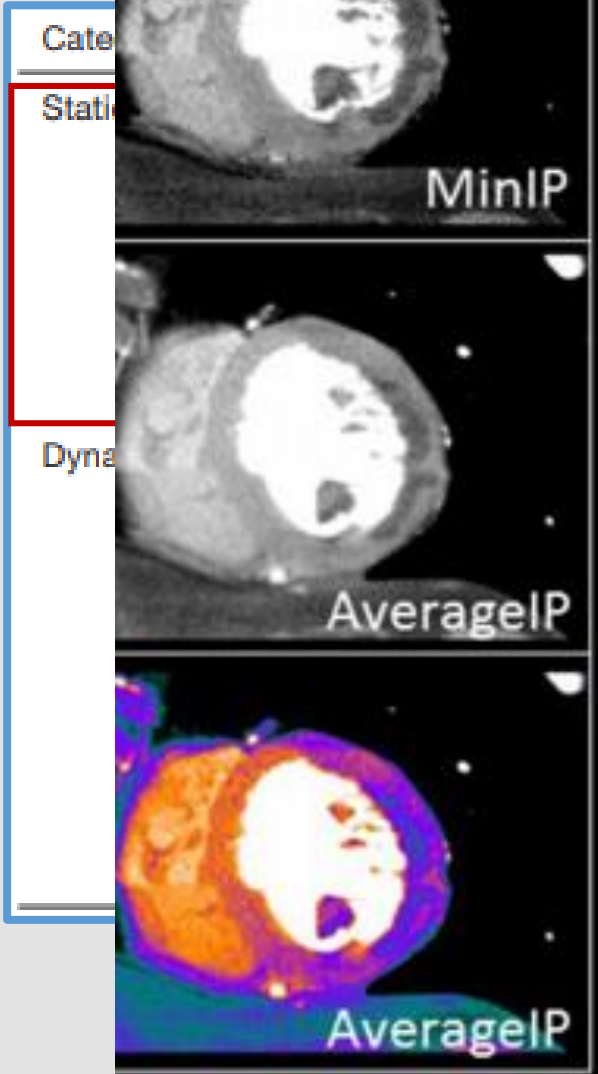
Sara Seitun,^{a,*} Margherita Castiglione Morelli,^a Irilda Budaj,^a Sara Boccacini,^a Athena Galletto Pregliasco,^a
Alberto Valbusa,^b Filippo Cademartiri,^c and Carlo Ferro^a





31 GIORNATE CARDIOLOGICHE TORINESI

TORIN
October
24th-26th
2019



data
titative CTP analyses only
tial
and cardiac motion artifacts
to multiple data sets being
analysis

Review Article

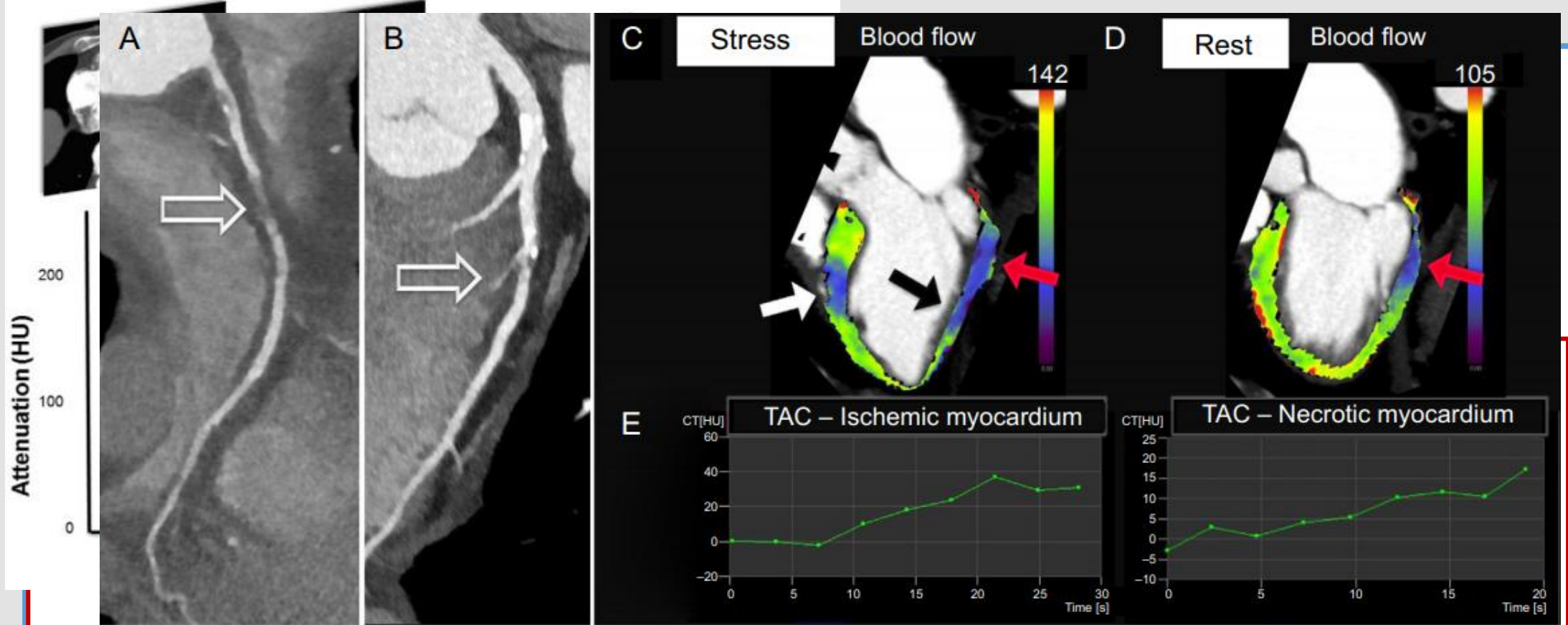
Myocardial computed tomography perfusion

Kelley R. Branch¹, Ryan D. Haley², Marcio Sommer Bittencourt^{3,4}, Amit R. Patel⁵, Edward Hulten², Ron Blankstein⁶



31 GIORNATE CARDIOLOGICHE TORINESI

TORIN
October
24th-26th
2019



Review article

Stress Computed Tomography Myocardial Perfusion Imaging:
A New Topic in Cardiology



and more complex analysis

Sara Seitun,^{a,*} Margherita Castiglione Morelli,^a Irida Budaj,^a Sara Boccalini,^a Athena Galletto Pregliasco,^a Alberto Valbusa,^b Filippo Cademartiri,^c and Carlo Ferro^a

Review Article

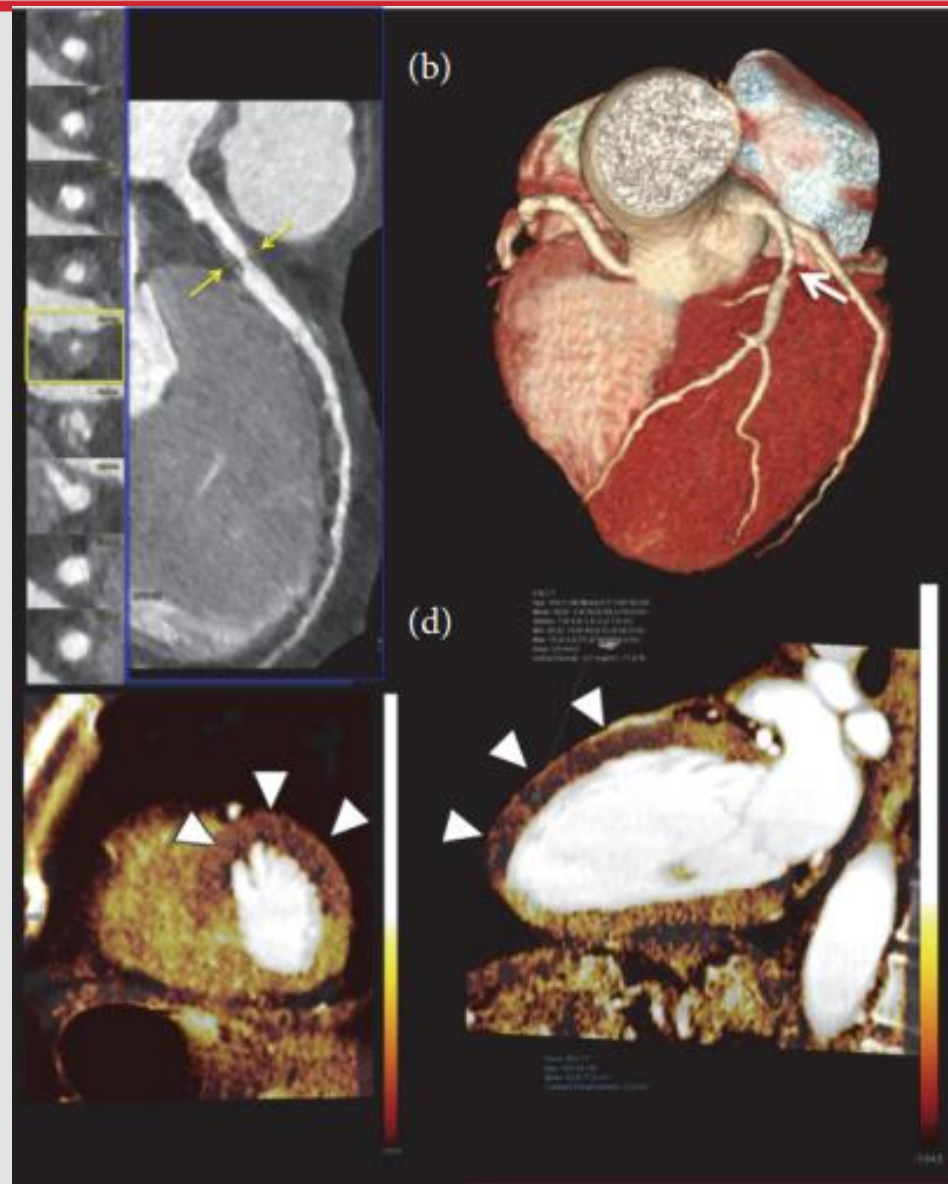
Myocardial computed tomography perfusion

Kelley R. Branch¹, Ryan D. Haley², Marcio Sommer Bittencourt^{3,4}, Amit R. Patel⁵, Edward Hulten², Ron Blankstein⁶



31 GIORNATE CARDIOLOGICHE TORINESI

TORIN
October
24th-26th
2019



Review article

Stress Computed Tomography Myocardial Perfusion Imaging: A New Topic in Cardiology



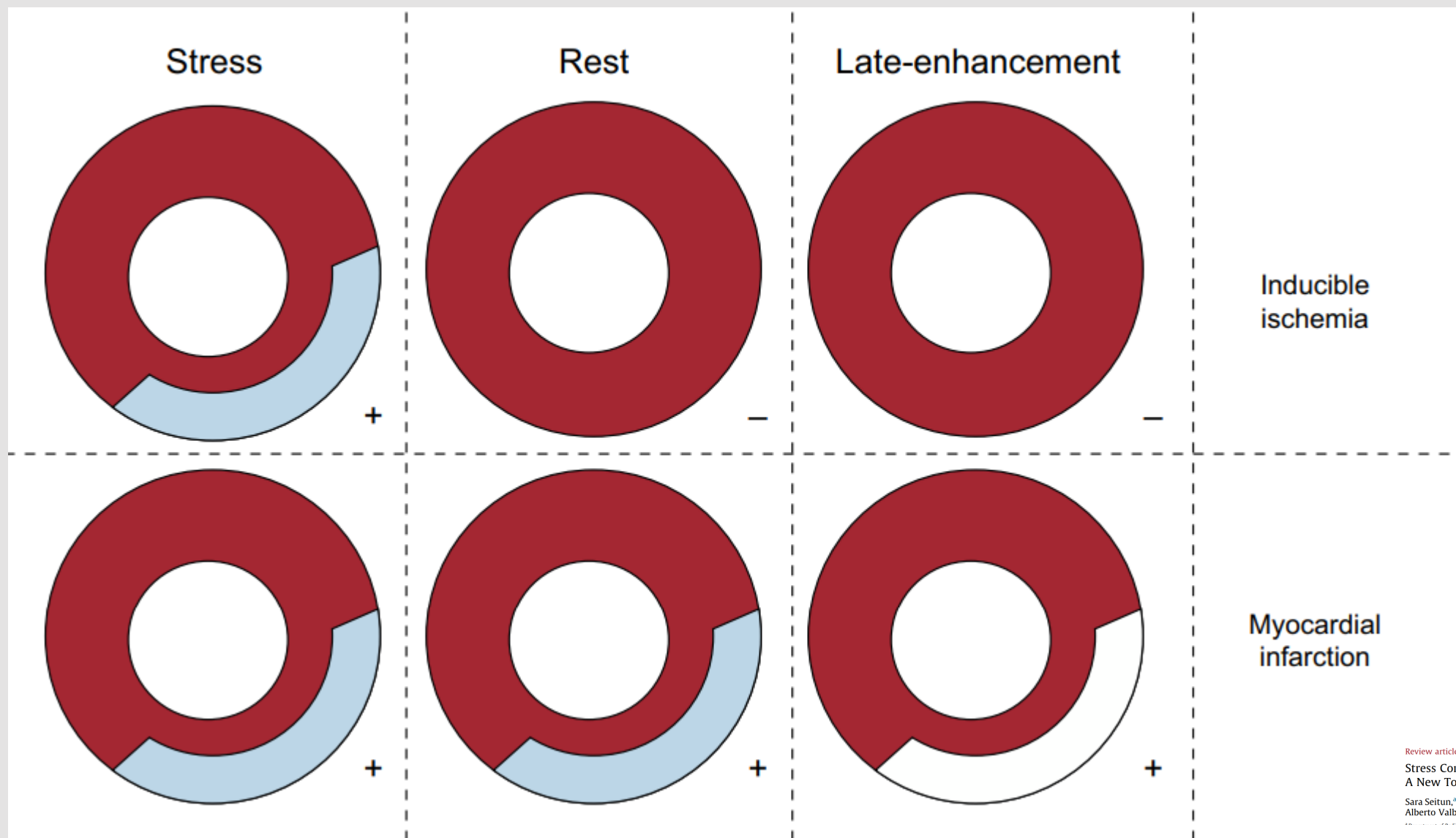
Sara Seitun,^{a,*} Margherita Castiglione Morelli,^a Irida Budaj,^a Sara Boccalini,^a Athena Galletto Pregliasco,^a Alberto Valbusa,^b Filippo Cademartiri,^c and Carlo Ferro^a

^aUniversità del Piemonte Orientale, ^bIRCCS Ospedale Maggiore Polyclinic, ^cIRCCS Istituto G. Pini, ^dIRCCS Ospedale Sacca S. Andrea, ^eIRCCS Ospedale Poma, ^fIRCCS Ospedale Carlo Poma, ^gIRCCS Ospedale Maggiore Polyclinic, ^hIRCCS Ospedale Sacca S. Andrea, ⁱIRCCS Ospedale Poma, ^jIRCCS Ospedale Carlo Poma, ^kIRCCS Ospedale Maggiore Polyclinic, ^lIRCCS Ospedale Sacca S. Andrea, ^mIRCCS Ospedale Poma, ⁿIRCCS Ospedale Carlo Poma



31 GIORNATE CARDIOLOGICHE TORINESI

TORIN
October
24th-26th
2019



Review article

Stress Computed Tomography Myocardial Perfusion Imaging:
A New Topic in Cardiology



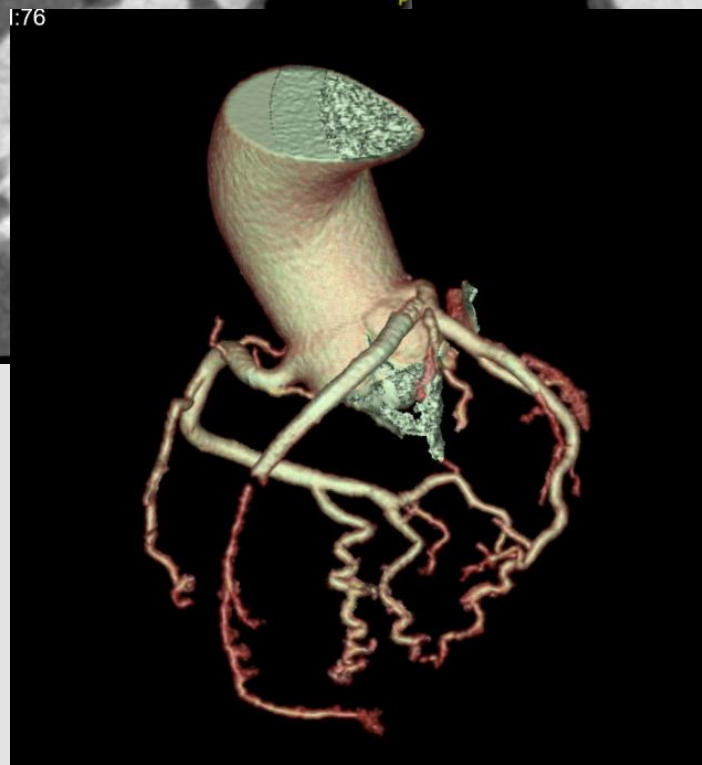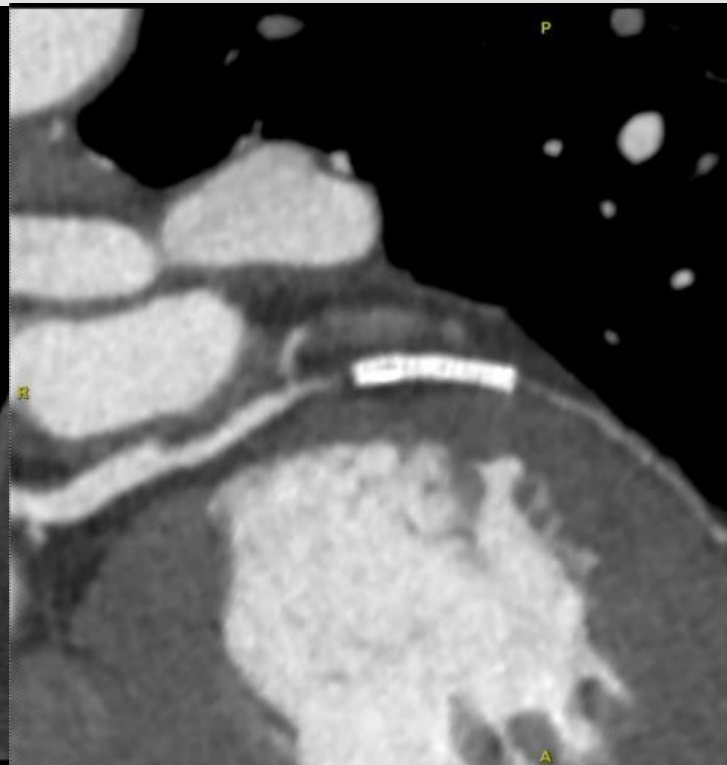
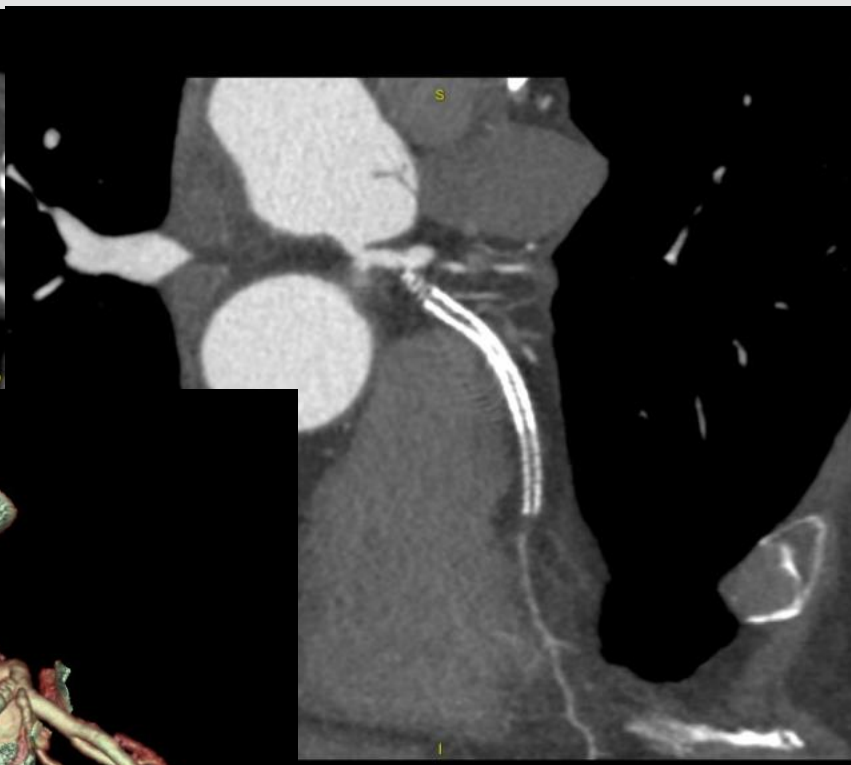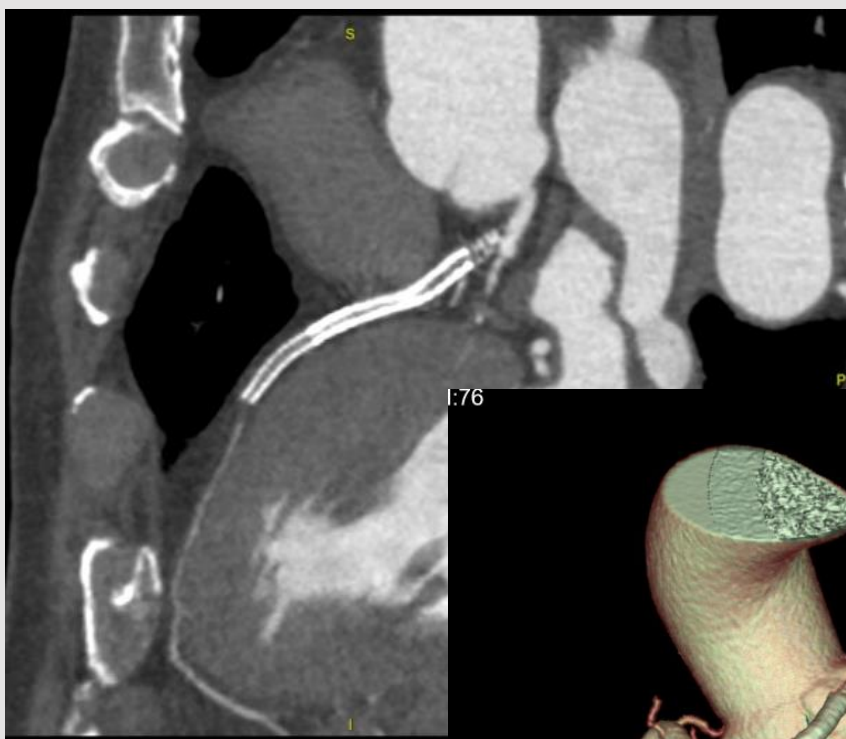
Sara Seitun,^{a,b} Margherita Castiglione Morelli,^a Irilda Budaj,^a Sara Boccalini,^a Athena Galletto Pregliasco,^b
Alberto Valbusa,^b Filippo Cademartiri,^c and Carlo Ferro^a

a) Dipartimento di Diagnostica e Cura Integrata, Università del Piemonte Orientale, Alessandria, Italy; b) Dipartimento di Diagnostica e Cura Integrata, Università del Piemonte Orientale, Novara, Italy; c) Dipartimento di Diagnostica e Cura Integrata, Università del Piemonte Orientale, Verbania, Italy



31 GIORNATE CARDIOLOGICHE TORINESI

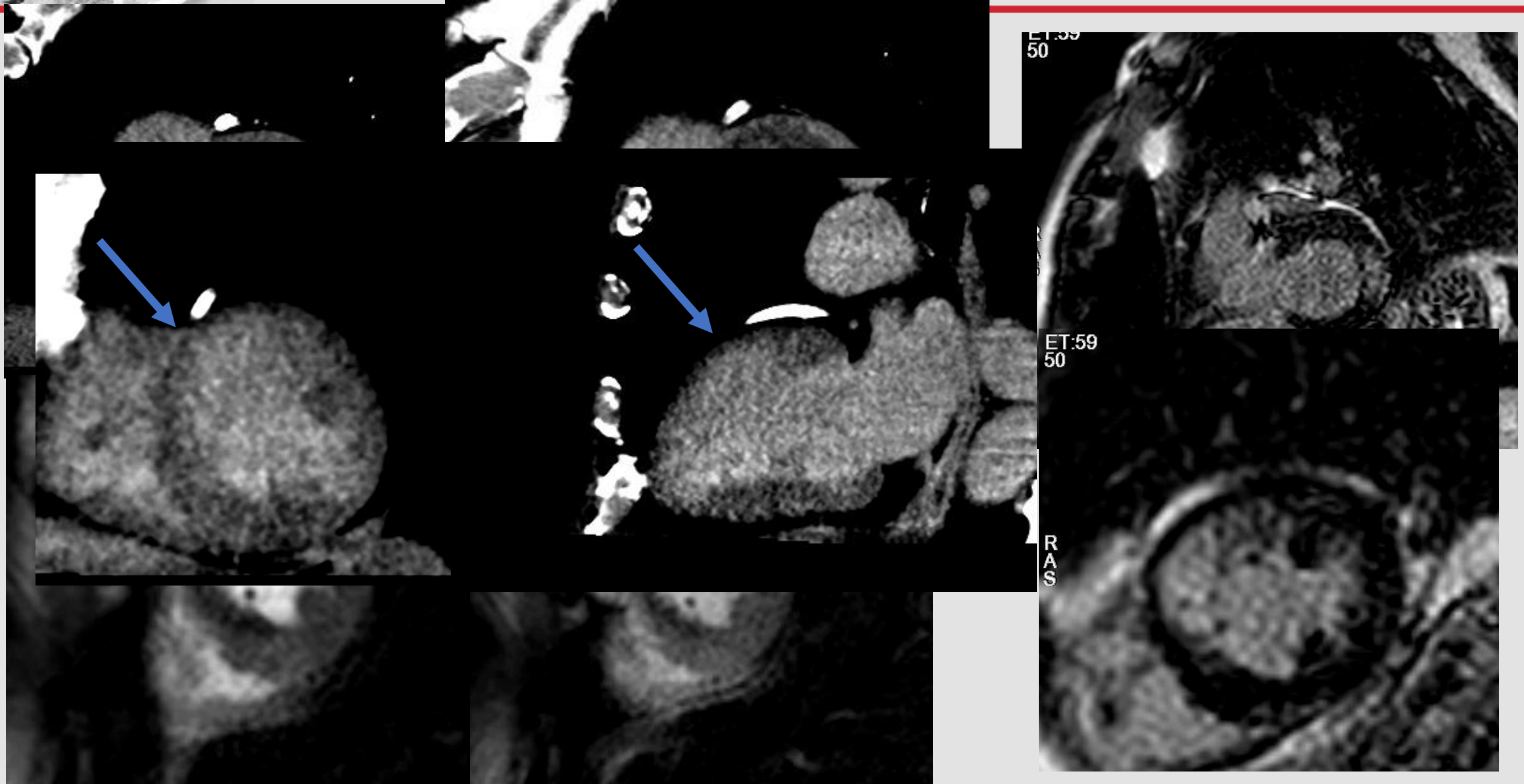
TORINO
October
24th-26th
2019





31 GIORNATE CARDIOLOGICHE TORINESI

TURIN
October
24th-26th
2019

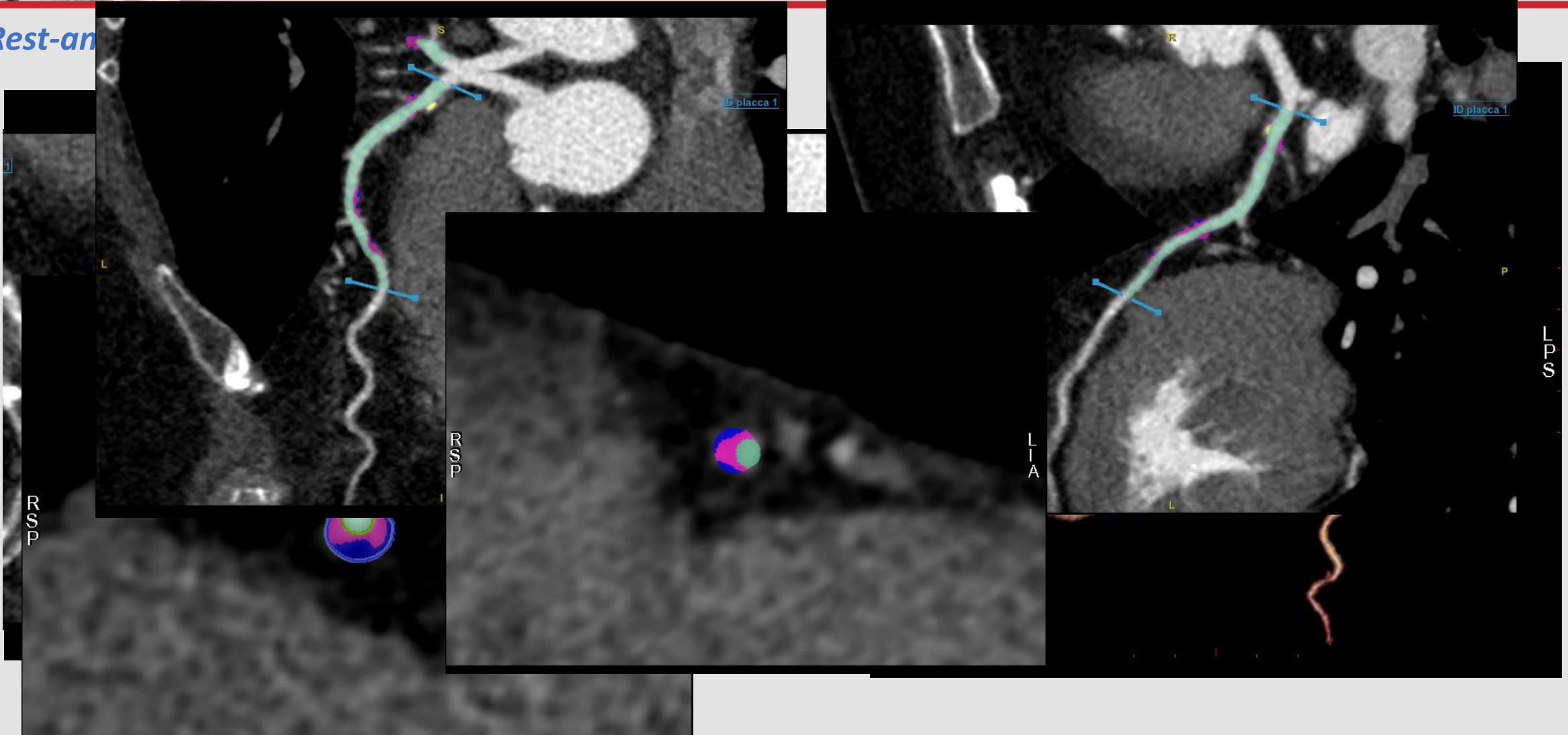




31 GIORNATE CARDIOLOGICHE TORINESI

TURIN
October
24th-26th
2019

Rest-an

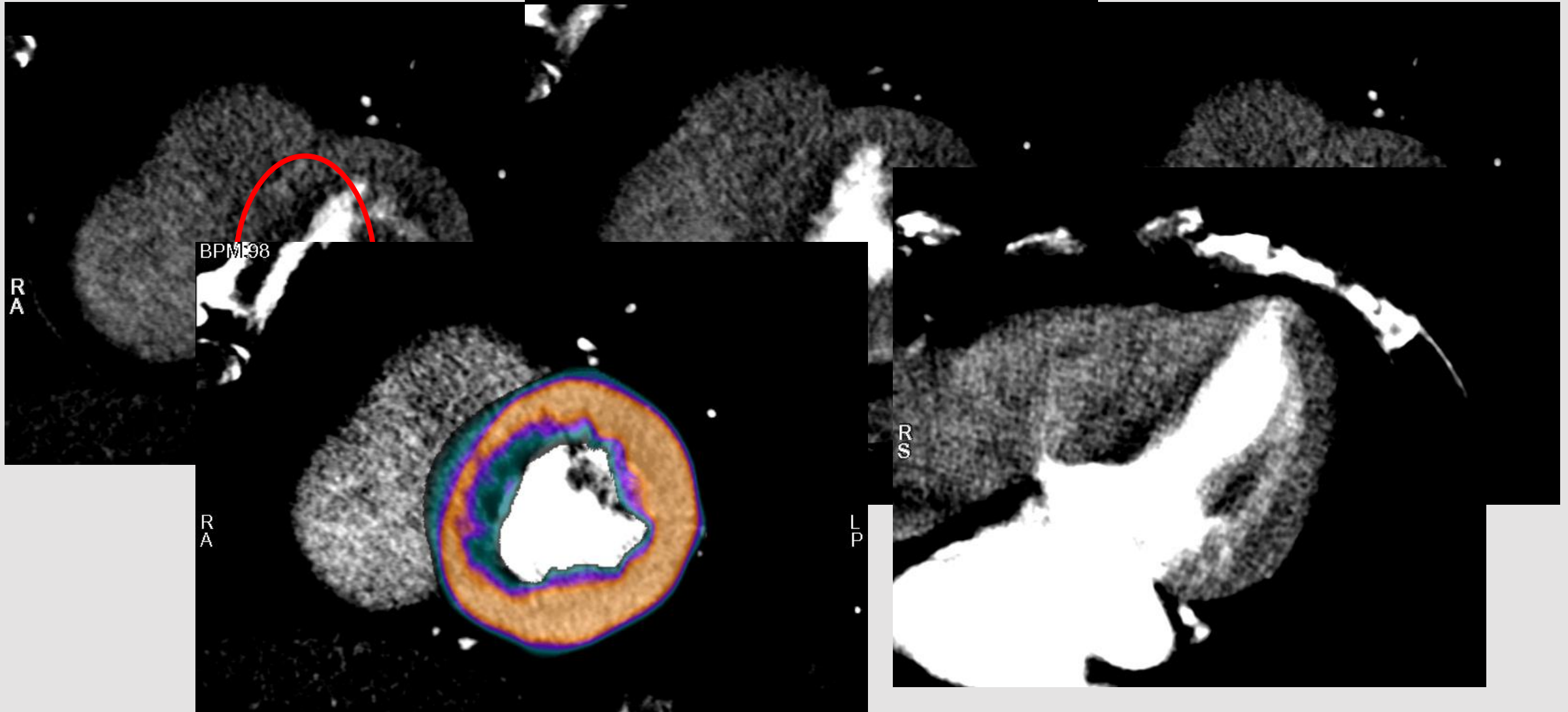




31 GIORNATE CARDIOLOGICHE TORINESI

TURIN
October
24th-26th
2019

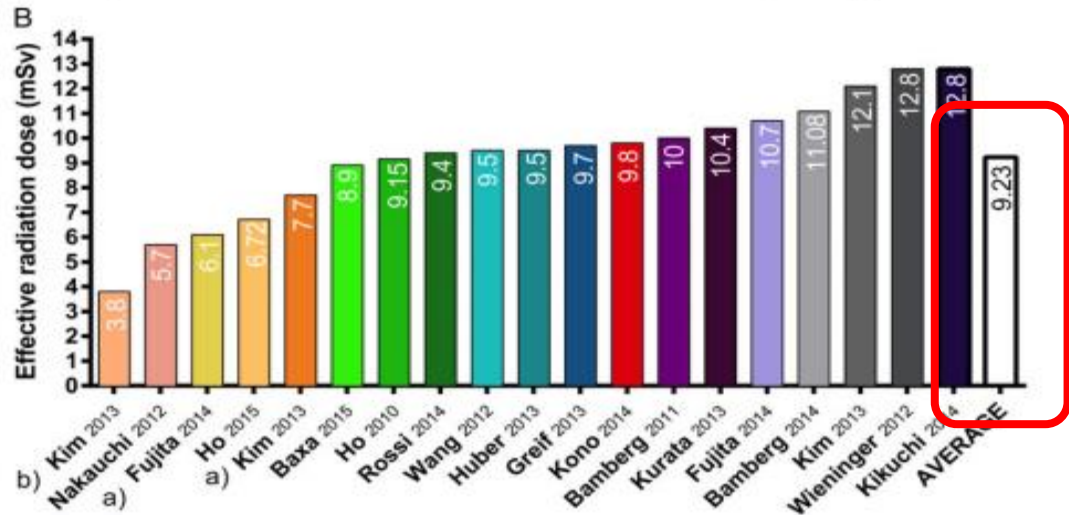
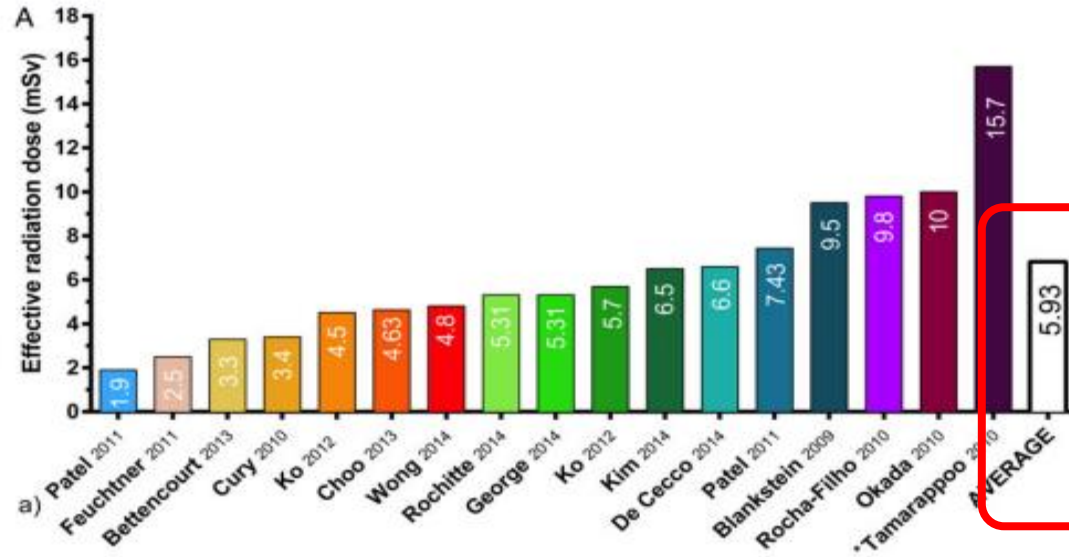
Stress CTP





31 GIORNATE CARDIOLOGICHE TORINESI

TURIN
October
24th-26th
2019



Radiation dose aspects



European Heart Journal – Cardiovascular Imaging (2016) 17, 836–844
doi:10.1093/ehjci/jew044

REVIEW

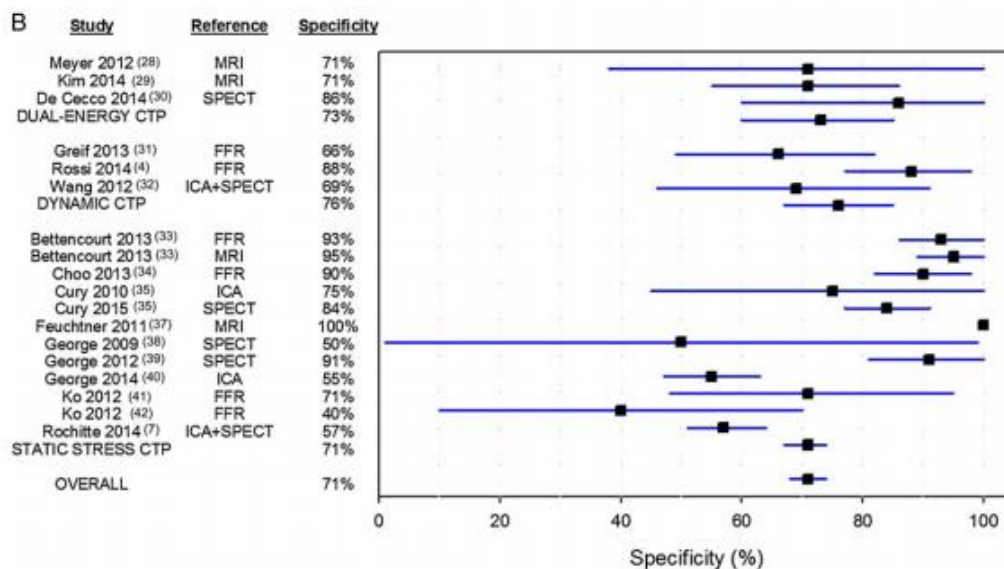
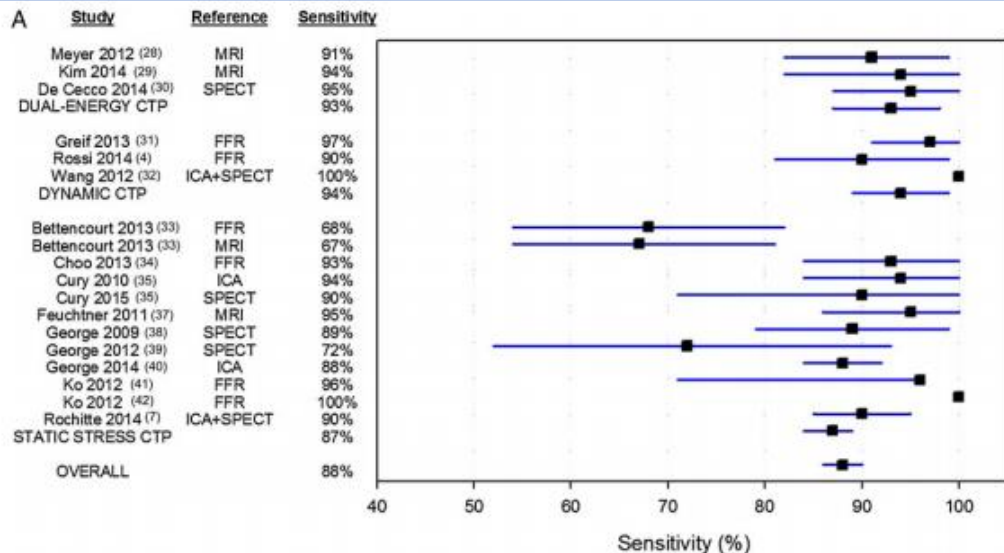
Static and dynamic assessment of myocardial perfusion by computed tomography

Ibrahim Danad^{1,2}, Jackie Szymonifka^{1,2}, Joshua Schulman-Marcus, and James K. Min^{1,2*}



31 GIORNATE CARDIOLOGICHE TORINESI

TURIN
October
24th-26th
2019



European Heart Journal – Cardiovascular Imaging (2016) 17, 836–844
doi:10.1093/ehjci/jew044

REVIEW

Static and dynamic assessment of myocardial perfusion by computed tomography

Ibrahim Danad^{1,2}, Jackie Szymonifka^{1,2}, Joshua Schulman-Marcus, and James K. Min^{1,2*}



31 GIORNATE CARDIOLOGICHE TORINESI

TURIN
October
24th-26th
2019

RESULTS The prevalence of obstructive CAD and functionally significant CAD was 77% and 57%, respectively. The sensitivity and specificity of cCTA alone, cCTA+FFR_{CT}, and cCTA+CTP were 83% and 66%, 86% and 75%, and 73% and 86%, respectively. Both the addition of FFR_{CT} and CTP improves the area under the curve (AUC: 0.876 and 0.878, respectively) as compared with cCTA alone (0.826; $p < 0.05$). The sequential strategy of cCTA+FFR_{CT}+CTP showed the highest AUC (0.919; $p < 0.05$) as compared with all other strategies. The mean effective radiation dose (ED) for cCTA and stress CTP was 2.8 ± 1.2 mSv and 5.3 ± 0.7 mSv, respectively.

CONCLUSIONS The addition of dynamic stress CTP on top of cCTA and FFR_{CT} provides additional diagnostic accuracy with acceptable radiation exposure. (J Am Coll Cardiol Img 2019; ■:■-■) © 2019 by the American College of Cardiology Foundation.

Computed Tomography and Fractional Flow Tomography Derivatives

Gianluca Pontone, MD, PhD,^a Andrea Bagge,^a Marco Guglielmo, MD,^a Giuseppe Muscogiu,^a Alberico Del Torto, MD,^b Saima Mushtaq, MD,^a Stefano De Martini, MD,^a Cristina Ferrari, MD,^a Paolo Ravagnani, MD,^a Giovanni Teruzzi, MD,^a Piero Montorsi, MD,^{a,b} Mark G. Rabbat, MD,^a

... predictive values and accuracy rates of 86%, 91%, 93%, 87%, 92%, and 98%, 83%, 92%, 87%, 87%, respectively. ... cCTA+stress-CTP showed vessel-based and patient-based sensitivity, specificity, and negative predictive values, and positive predictive values and accuracy rates of 92%, 95%, 97%, 87%, 94% and 98%, 87%, 99%, 86%, 92%, respectively. Both FFR_{CT} and stress-CTP significantly improved specificity and positive predictive values compared to those of cCTA alone. The area under the curve to detect flow-limiting stenoses of cCTA, cCTA+FFR_{CT}, and cCTA+CTP were 0.89, 0.93, 0.92, and 0.90, 0.94, and 0.93 in a vessel-based and patient-based model, respectively, with significant additional values for both cCTA+FFR_{CT} and cCTA+CTP versus cCTA alone ($p < 0.001$) but no differences between cCTA+FFR_{CT} versus cCTA+CTP.

CONCLUSIONS FFR_{CT} and stress-CTP in addition to cCTA are valid and comparable tools to evaluate the functional relevance of CAD. (J Am Coll Cardiol Img 2018; ■:■-■) © 2018 by the American College of Cardiology Foundation.

Luca Grancini, MD,^a Paolo Ravagnani, MD,^a Giovanni Teruzzi, MD,^a Daniela Trabattoni, MD,^a Franco Fabbiochi, MD,^a Alessandro Lualdi, MD,^{a,b} Piero Montorsi, MD,^{a,b} Mark G. Rabbat, MD,^{f,g} Antonio L. Bartorelli, MD,^{a,h} Mauro Pepi, MD^a



31 GIORNATE CARDIOLOGICHE TORINESI

TURIN
October
24th-26th
2019

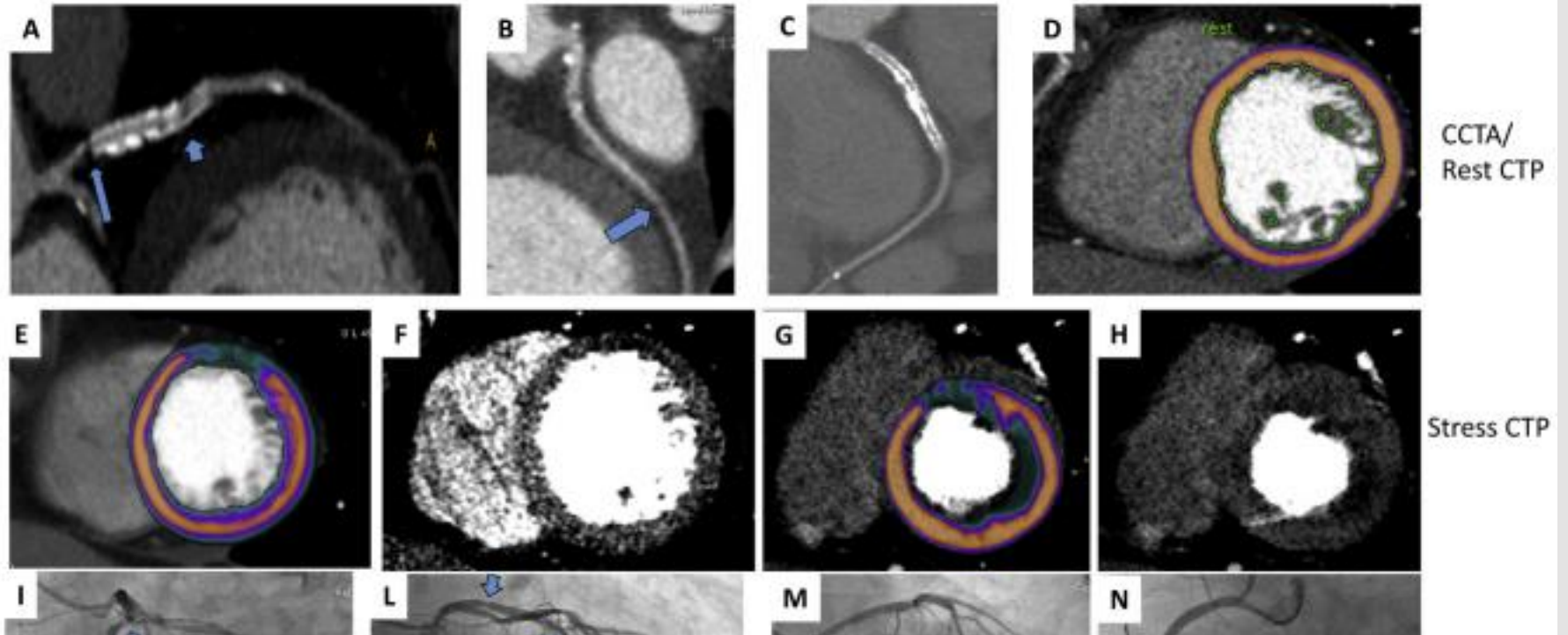
JACC: CARDIOVASCULAR IMAGING

© 2019 BY THE AMERICAN COLLEGE OF CARDIOLOGY FOUNDATION
PUBLISHED BY ELSEVIER

ORIGINAL RESEARCH

CT Perfusion Versus Coronary Angiography in Patients With In-Stent Restenosis of the Left Anterior Descending Artery

Daniele Andreini, MD, PhD,^{a,b} Saima Mushtaq, MD,^a G. Carlos Collet, MD,^c Jeroen Sonck, MD,^c Andrea D'Erric, MD,^a Andrea Baggiano, MD,^a Daniela Trabattoni, MD,^a Paolo Olivares, MD,^a Franco Fabbiocchi, MD,^a Stefano Andrea Annoni, MD,^a Maria Elisabetta Mancini, MD,^a Elisa Consiglio, MS,^a Giuseppe Muscogiuri, MD,^a Federico Antonio L. Bartorelli, MD,^{a,f} Mauro Pepi, MD^a



CONCLUSIONS In patients with coronary stents, CTP significantly improved the diagnostic rate and accuracy of coronary CTA alone compared with both ICA and invasive FFR as gold standard. (J Am Coll Cardiol Img 2019; ■:■-■)

© 2019 by the American College of Cardiology Foundation





31 GIORNATE CARDIOLOGICHE TORINESI






TURIN
October
24th-26th
2019

Home > Radiology > VOL. 291, NO. 2

Original Research



Patient Preferences for Coronary CT Angiography with Stress Perfusion, SPECT, or Invasive Coronary Angiography

Anum Minhas*,  Marc Dewey* , Andrea L. Vavere,  Yutaka Tanami, Mohammad R. Ostovaneh, Michael Laule, Carlos E. Rochitte, Hiroyuki Niinuma,  Klaus F. Kofoed, Jacob Geleijns, ... **Show all Authors** 

* A.M. and M.D. contributed equally to this work.

Conclusion

For cardiac imaging, patients generally favored CT angiography with stress perfusion, while study participants from Asia generally reported lowest satisfaction.



31 GIORNATE CARDIOLOGICHE TORINESI


TURIN
October
24th-26th
2019



ELSEVIER

International Journal of Cardiology

Volume 292, 1 October 2019, Pages 253-257



Design of CTP-PRO study (impact of stress Cardiac computed Tomography myocardial Perfusion on downstream resources and PROgnosis in patients with suspected or known coronary artery disease: A multicenter international study)

Gianluca Pontone ^{a, 1} ✉, Carlo De Cecco ^{b, 1}, Andrea Baggiano ^a, Andrea I. Guaricci ^a, Marco Guglielmo ^a, Tim Leiner ^d, Joao Lima ^e, Pál Maurovich-Horvat ^f, Giuseppe Muscogiuri ^a, John W. Nance ^g, U. Joseph Schoepf ^g

Highlights

- CTP-PRO study is a prospective, randomized study evaluating the cost-effectiveness of a CCTA+CTP strategy (Group A) versus usual care (Group B).
- A total sample size of 2000 subjects will be enrolled and followed up for 24 months.
- Primary endpoint: reclassification rate of CCTA in group B due to the addition of CTP.
- Secondary endpoint: comparison of downstream testing, prevalence of obstructive CAD, revascularization, cumulative ED and overall cost.
- Tertiary endpoint: comparison between each group in terms of MACE and cost-effectiveness at 1- and 2-years.