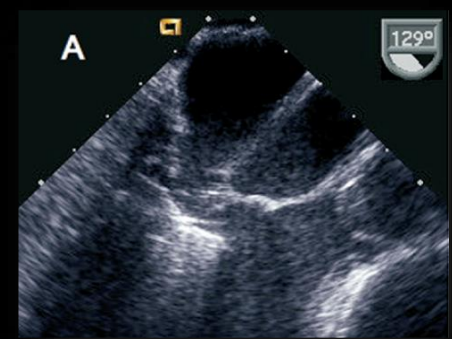
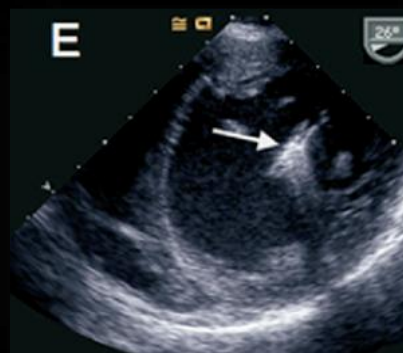
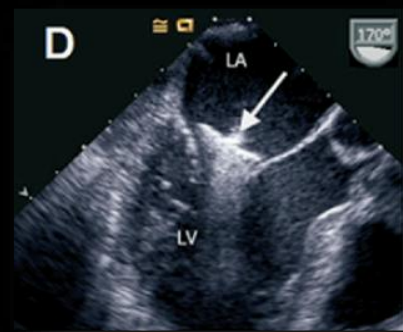
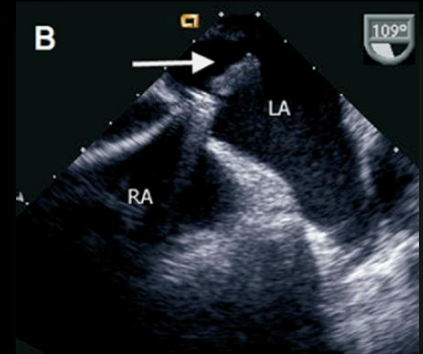
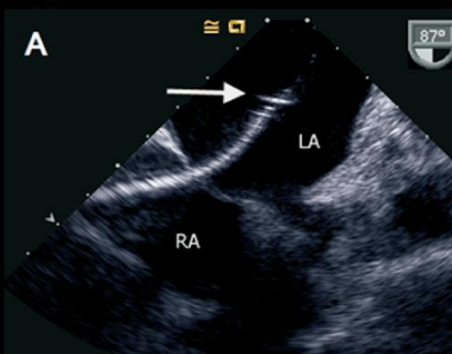
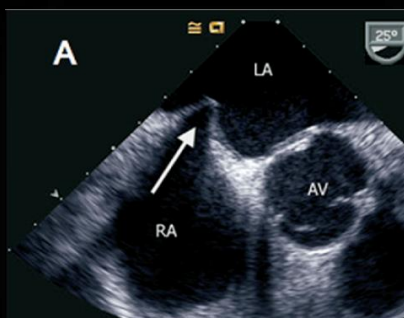


# Echocardiographic-fluoroscopic fusion imaging for transcatheter mitral valve repair guidance

Francesco Faletra

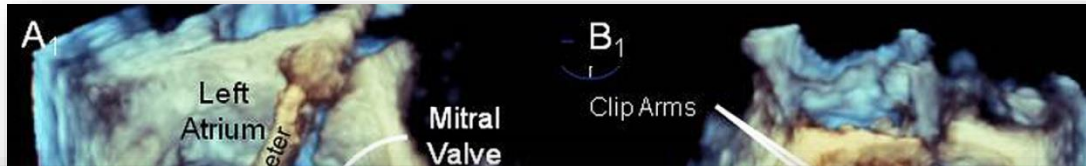

Echocardiography



J Am Soc Echocardiogr 2007;20:1131-1140

## Use of Real Time Three-Dimensional Transesophageal Echocardiography in Intracardiac Catheter Based Interventions



**Conclusion:** RT3D TEE is a powerful new imaging tool that may become the technique of choice and the standard of care for guidance of selected percutaneous catheter-based procedures. (J Am Soc Echocardiogr 2009;22:865-82.)



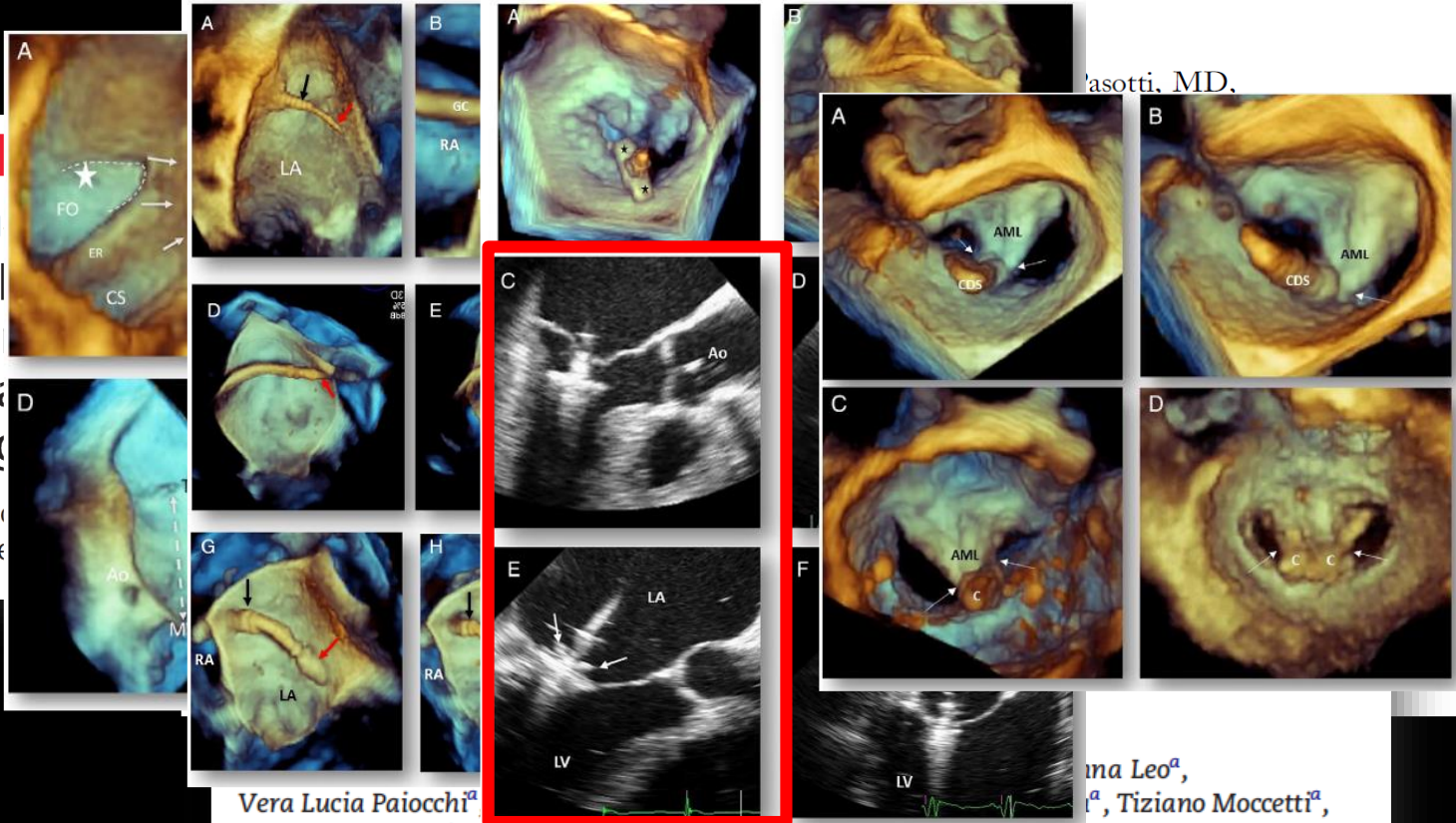
**Methods:** The authors used RT3D TEE to guide 72 catheter-based cardiac interventions. The procedures included the occlusion of atrial septal defects or patent foramen ovals (n = 25), percutaneous mitral valve repair (e-valve clipping; n = 3), mitral balloon valvuloplasty for mitral stenosis (n = 10), left atrial appendage obliteration (n = 11), left atrial or pulmonary vein ablation for atrial fibrillation (n = 5), percutaneous closures of prosthetic valve dehiscence (n = 10), percutaneous aortic valve replacement (n = 6), and percutaneous closures of ventricular septal defects (n = 2). In this review, the authors describe their experience with this technique, the added value over multiplanar two-dimensional TEE, and the pitfalls that were encountered.

**Results:** The main advantages found for the use RT3D TEE during catheter-based interventions were (1) the ability to visualize the entire lengths of intracardiac catheters, including the tips of all catheters and the balloons or devices they carry, along with a clear depiction of their positions in relation to other cardiac structures, and (2) the ability to demonstrate certain structures in an “en face” view, which is not offered by any other currently available real-time imaging technique, enabling appreciation of the exact nature of the lesion that is undergoing intervention.

**Conclusion:** RT3D TEE is a powerful new imaging tool that may become the technique of choice and the standard of care for guidance of selected percutaneous catheter-based procedures. (J Am Soc Echocardiogr 2009;22:865-82.)

STATE-OF-THE-ART PAPER

# 3D TEE During Catheter-Based



asotti, MD,

NON  
Rol  
tra  
ima  
edg  
Fran  
Agne

ageal  
its 3-  
s take  
these  
ogists  
aches  
f any  
useful  
otent  
ire of  
ology

Vera Lucia Paiocchi<sup>a</sup>  
Joseph F. Malouf<sup>c</sup>

ma Leo<sup>a</sup>,  
<sup>a</sup>, Tiziano Moccetti<sup>a</sup>,

<sup>a</sup>Fondazione Cardiocentro Ticino, Lugano, Switzerland  
<sup>b</sup>Hospital Européen G. Pompidou, Institut Mutualiste Montsouris, Paris, France  
<sup>c</sup>Mayo Clinic, Rochester, MN, United States

# Limitations of the dual approach (2D/3D TEE and fluoroscopy)

- *Two separates monitors*
- *Need of repeatedly and sequentially interrogate the two monitors*
- *Imaging data sets shown in different orientations*
- *Lack of optimal eye-hand coordination*

# All (images) in one (screen)

## *Fusion imaging*

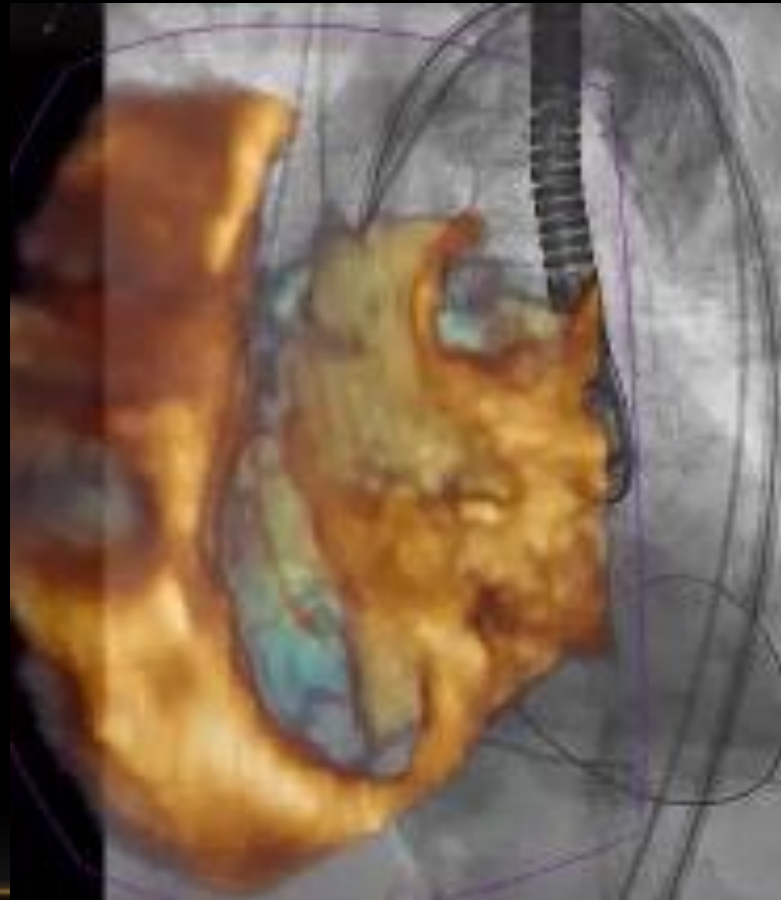
Echo and fluoroscopy are based on different physical principles (*ultrasound mechanical waves versus electromagnetic waves*) and remarkable differences in imaging generation (*echoes versus attenuation*).

They fit well when fused together in a single “*hybrid*” image because:

- Both are *real-time and complementary* imaging techniques:
- *Catheters and devices* are better visualized by fluoroscopy
- *Soft tissues* are better visualized by echocardiography

# Fusion imaging

*Co-registration: integration in space and time*



# Fusion or *confusion*?



# Tools can avoid *confusion*

# Fusion or *confusion*?

*Tools: cropping*

What the hell is  
this thing...!!!



*Confusion*

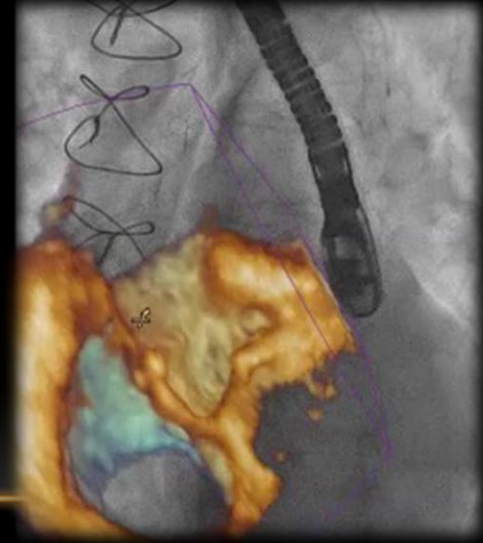
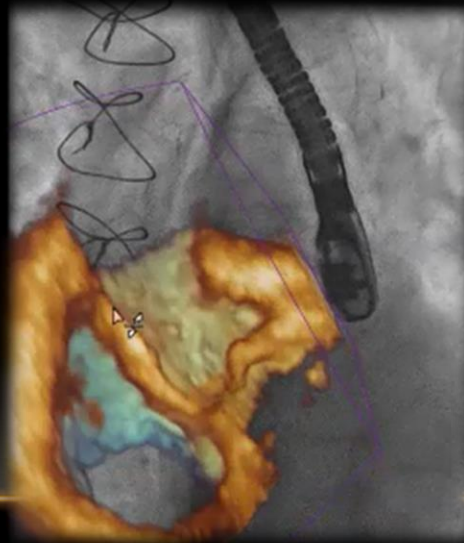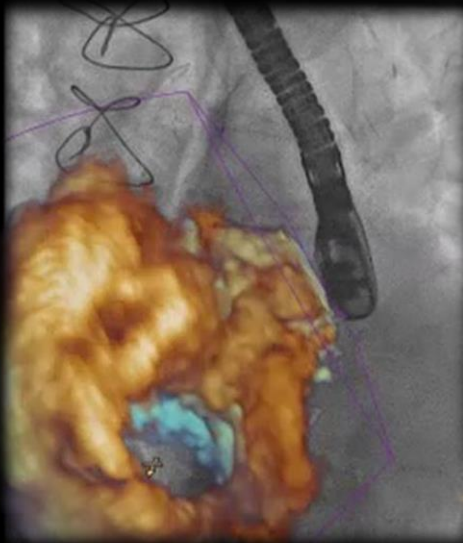Wait,  
second....



*Cropping*

Ha.. I see

*Fusion*



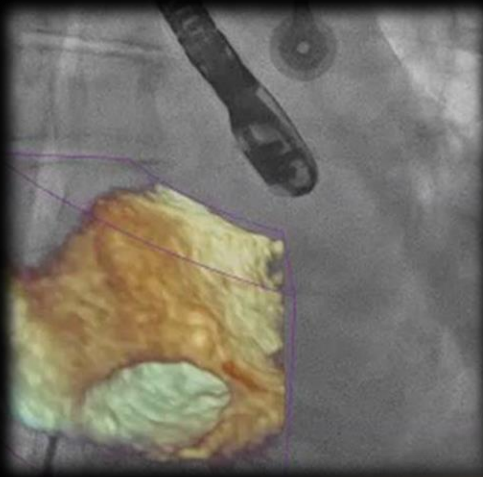
# Fusion or confusion?

*Tools: transparency*

**Where is the tip  
of my catheter ?**



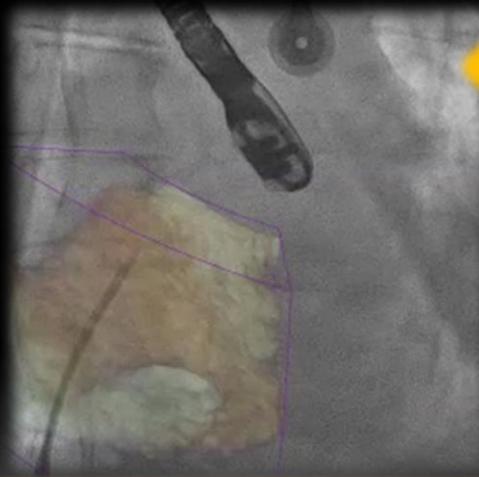**Confusion**



I will show you in a  
second.....



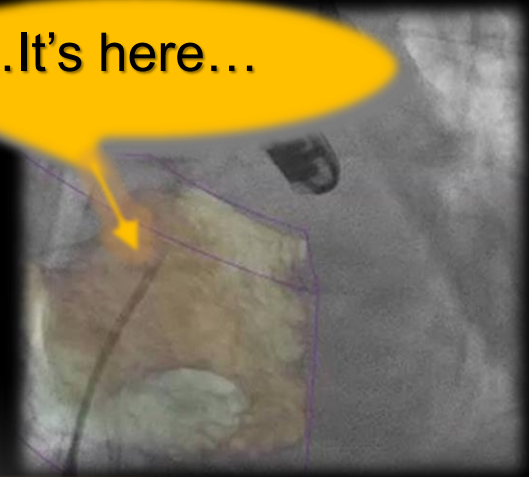
**Transparency**



Ha... I see it

**Fusion**

...It's here...

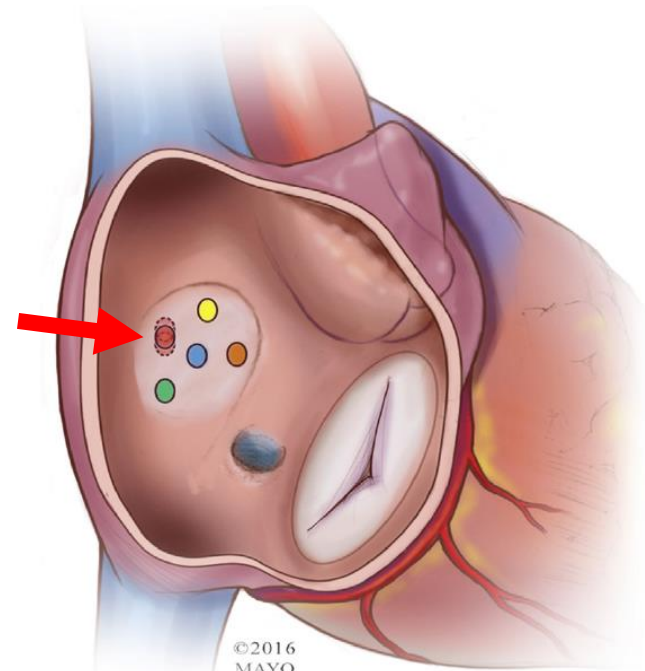
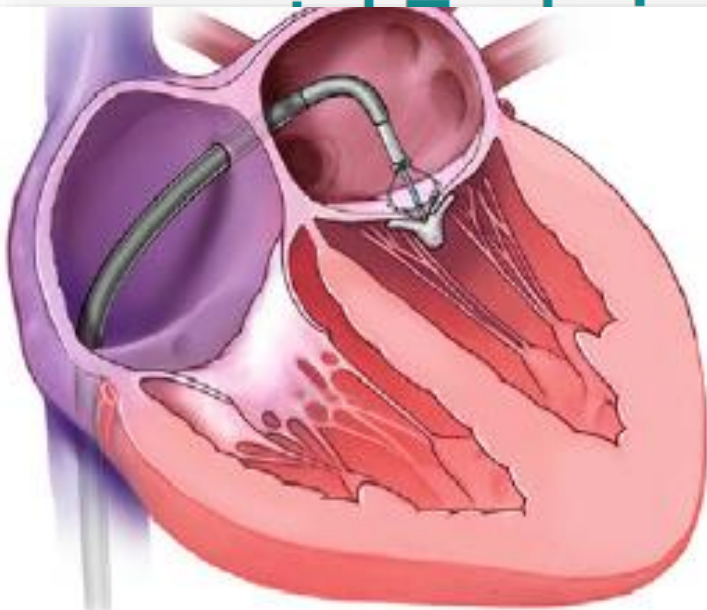


# Transseptal puncture

---

# Transseptal puncture

## Site-Specific



T  
E

Mc

es f  
-lea

d R. Hol

ventions  
iques. Th  
by-step  
9:2465-8

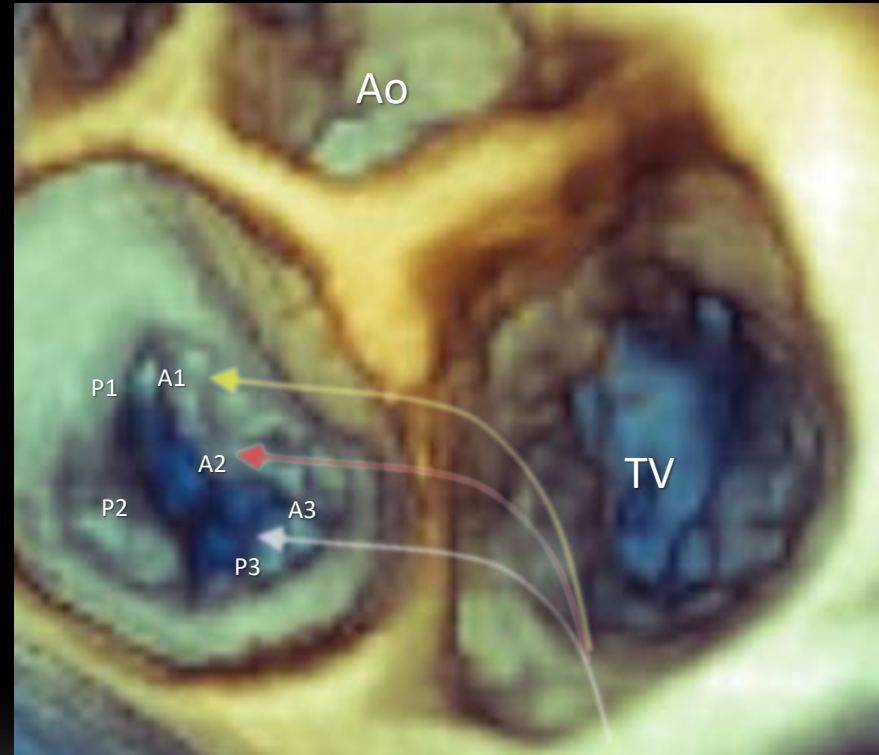
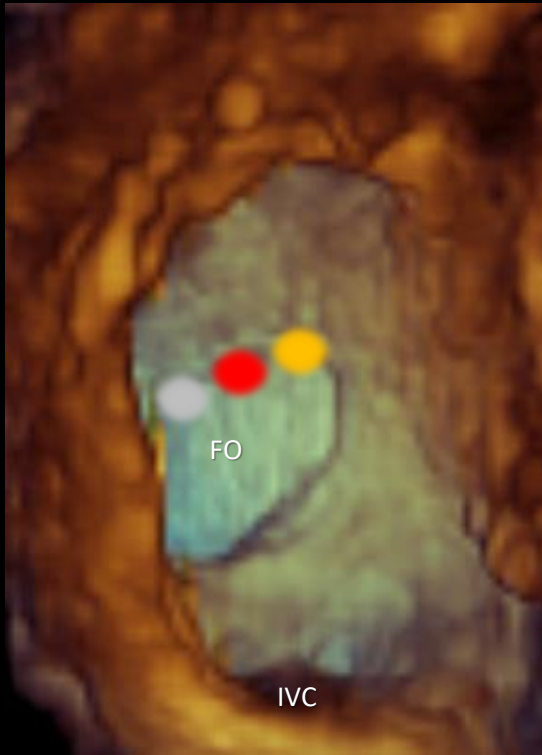
Foundation.

©2016  
MAYO

Mark

# Transseptal puncture

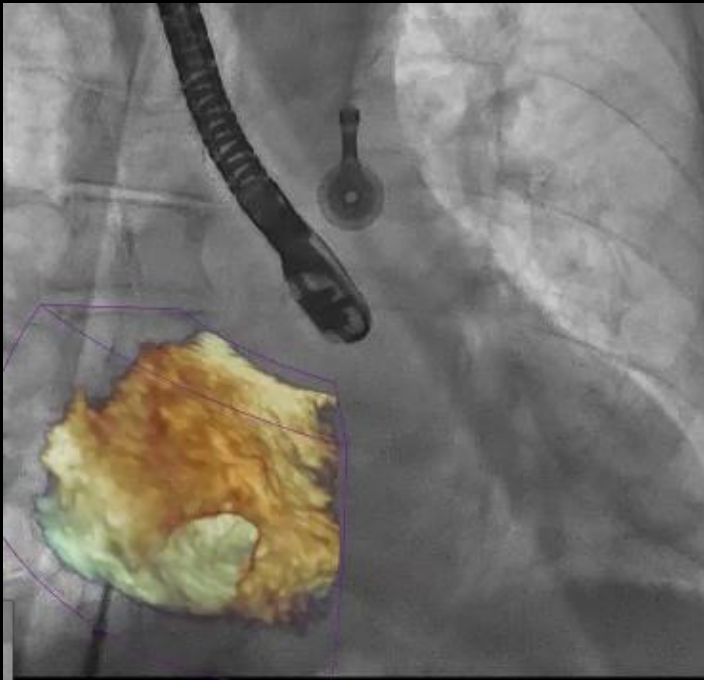
## Site-Specific



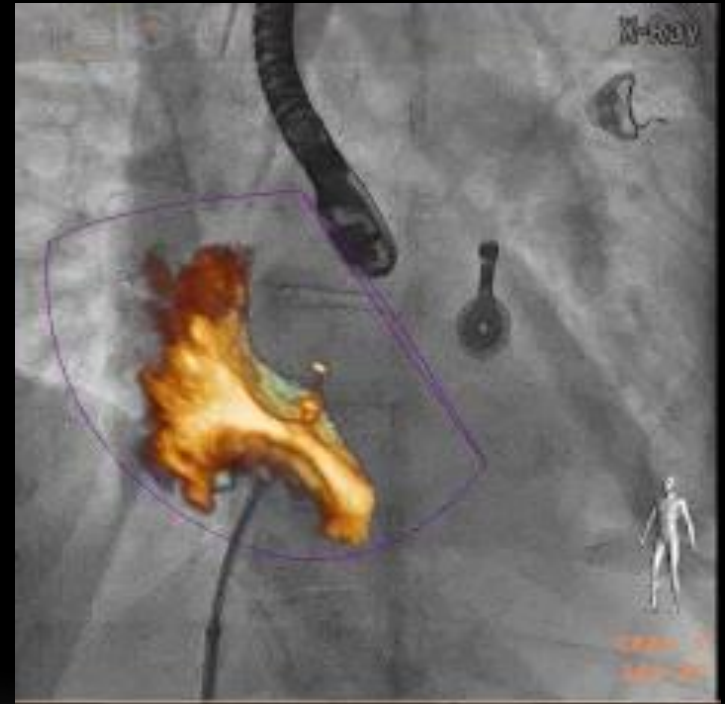
# Transseptal puncture

## Site-Specific

RAO 30°



LAO 30°

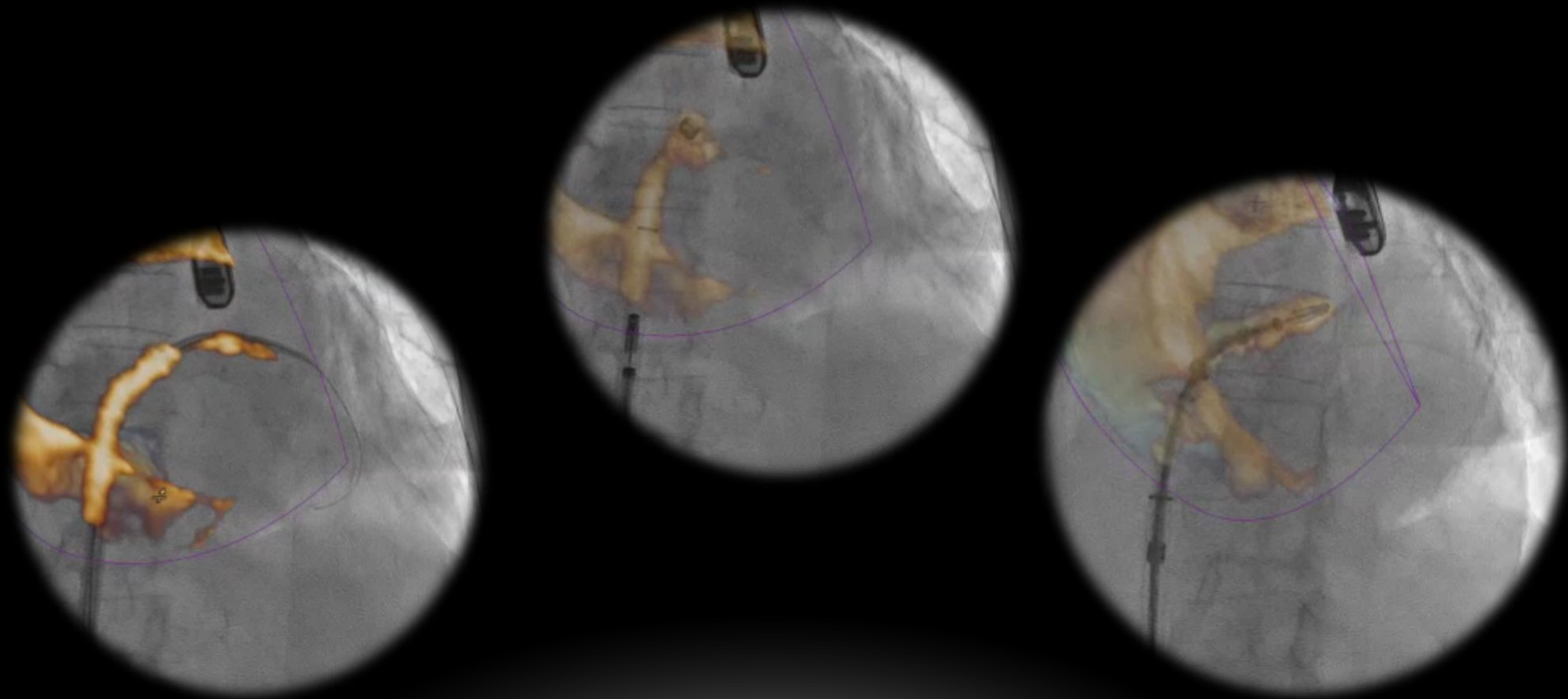


# Advancement of clip delivery system into the LA

---

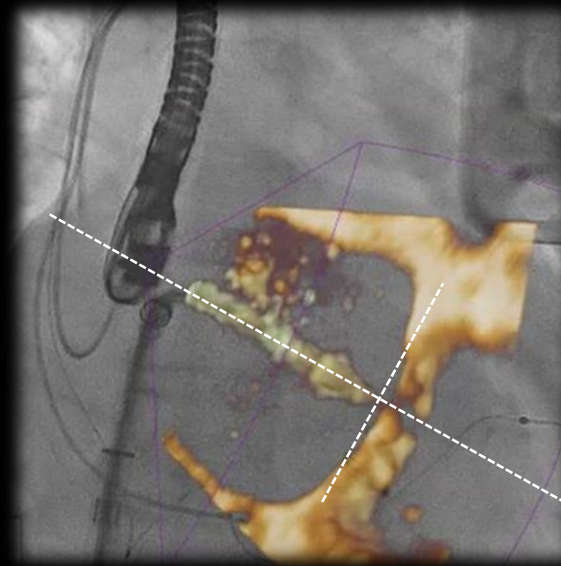
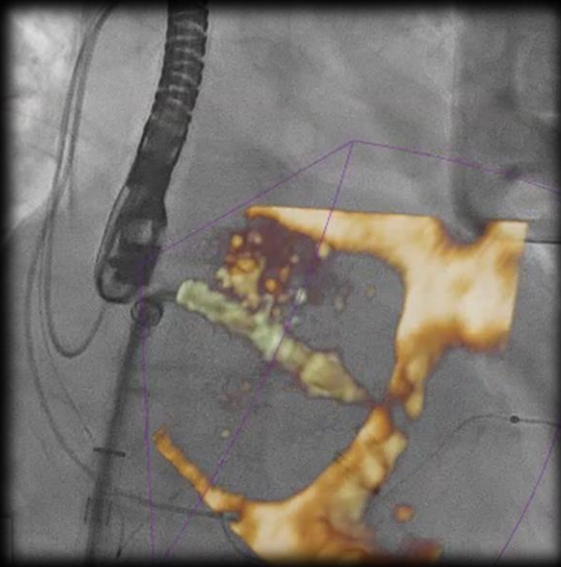


# Advancement of clip delivery system into LA

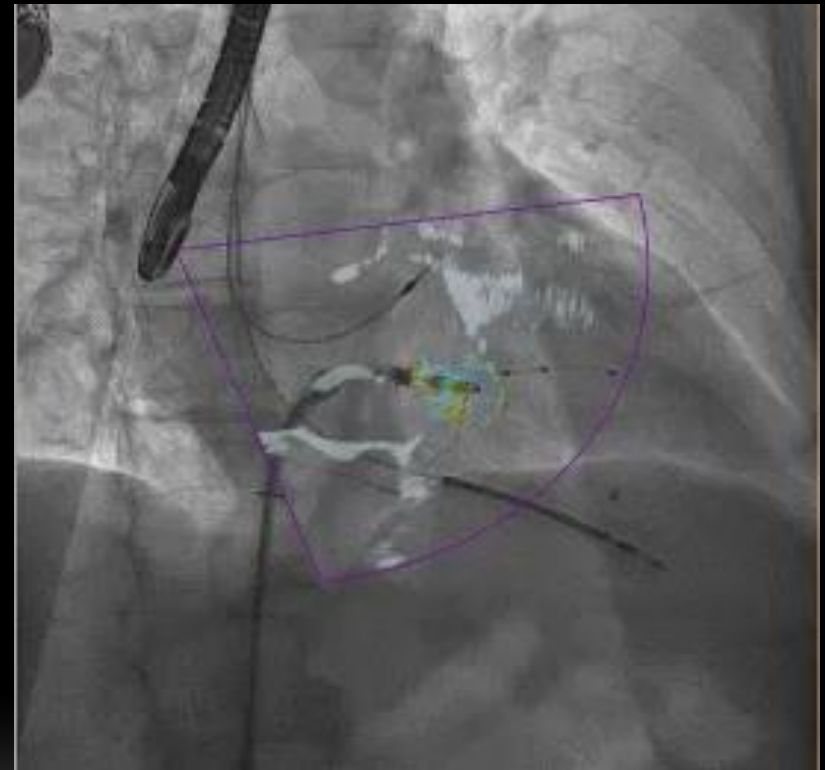
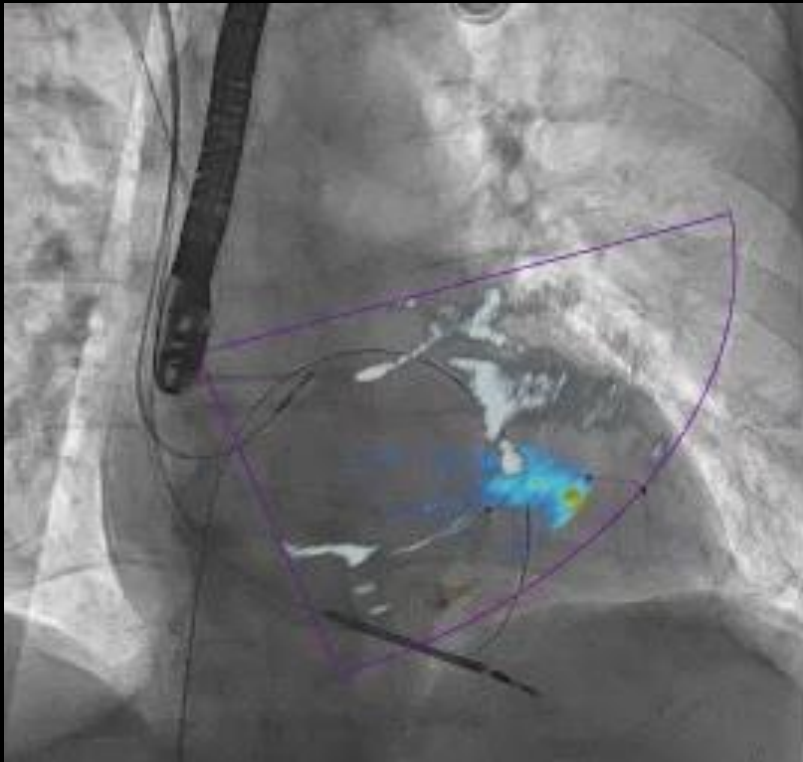


Positioning the clip delivery  
system perpendicular to MV  
orifice

# Positioning the clip delivery system perpendicular to MV orifice



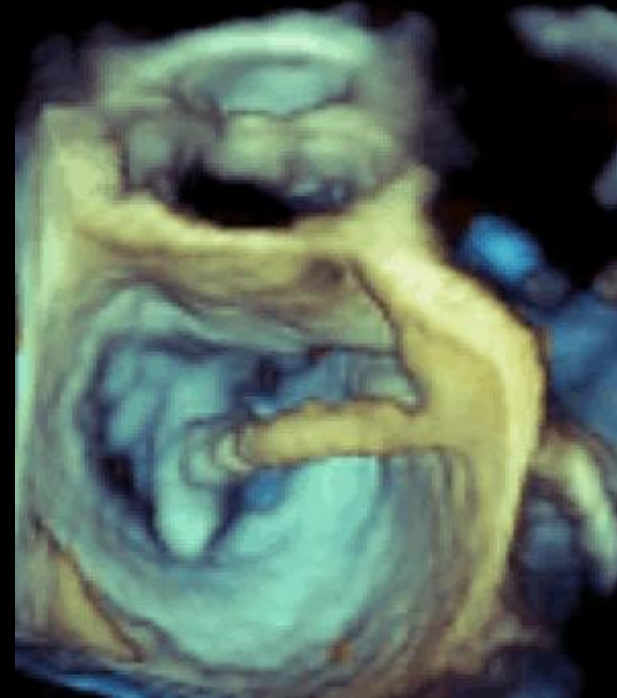
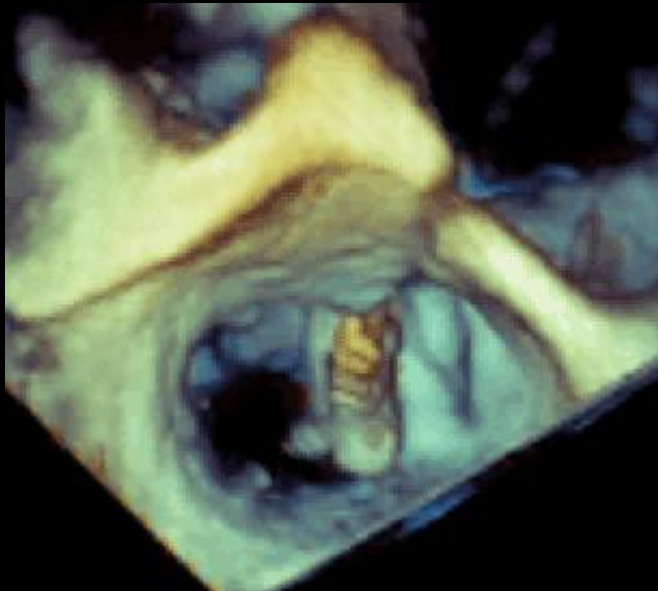
# Positioning the clip delivery system over the regurgitant jet



Positioning the clip arms  
perpendicular to the  
coaptation line

---

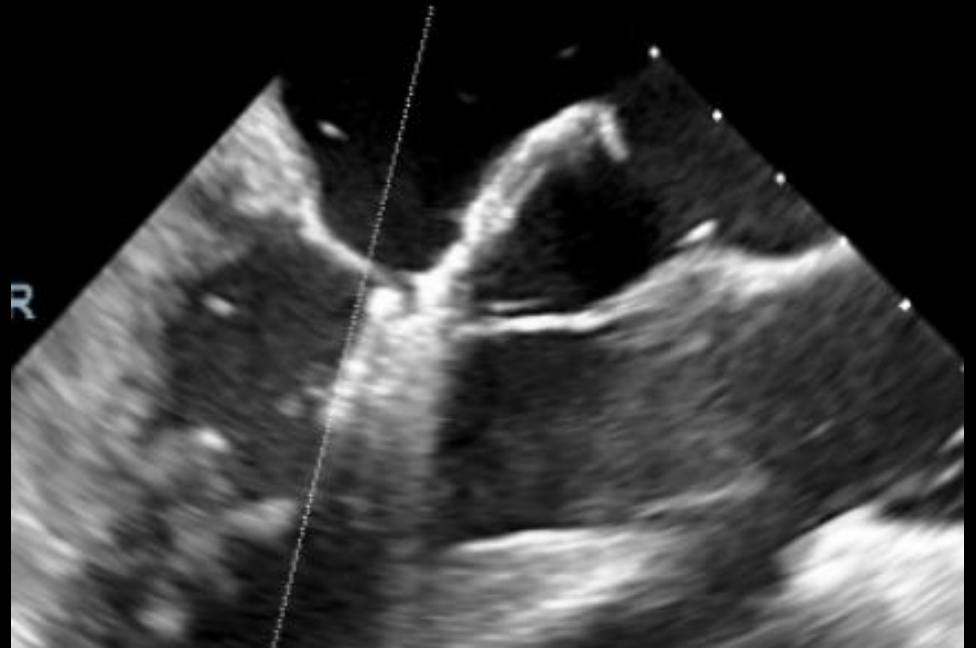
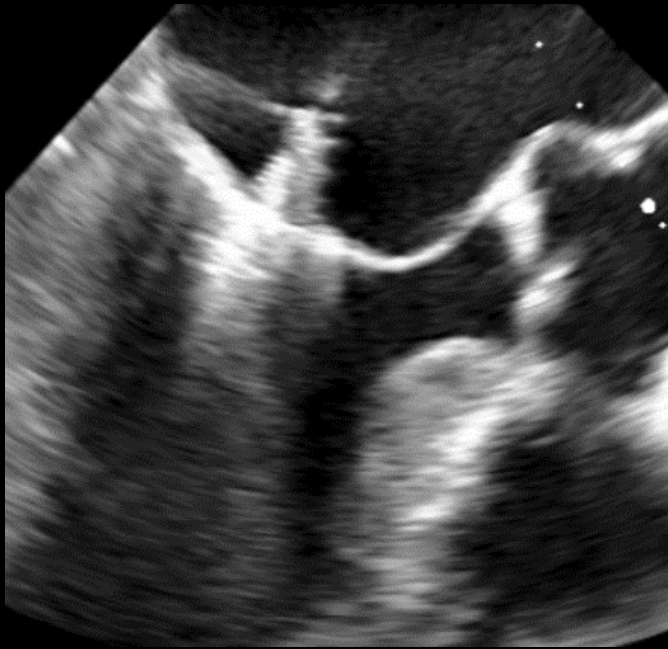
# Positioning the clip arms perpendicular to the coaptation line



# Grasping

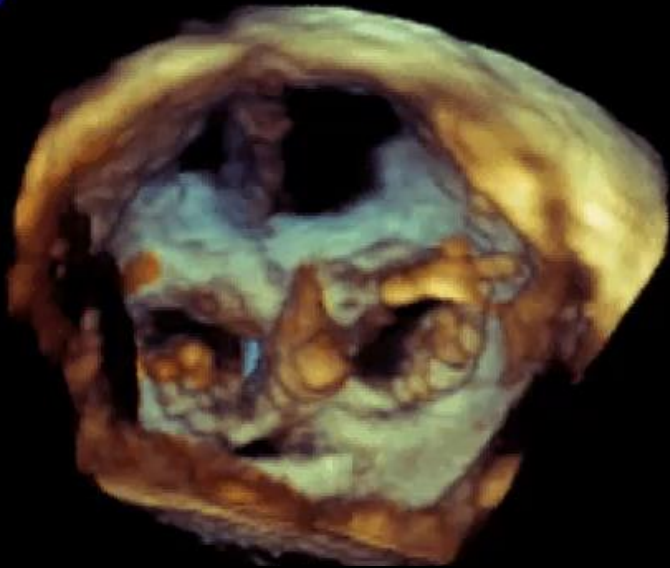


# Grasping

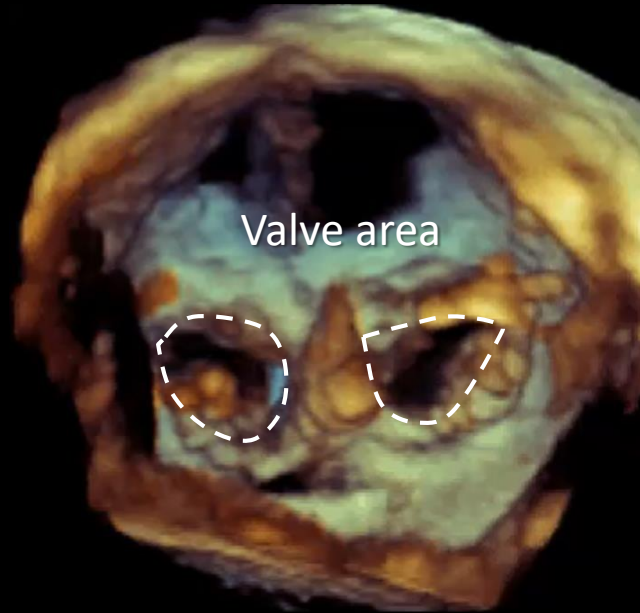
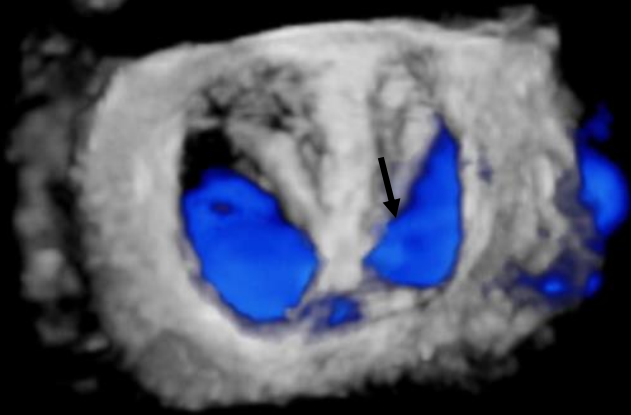




# After any clip

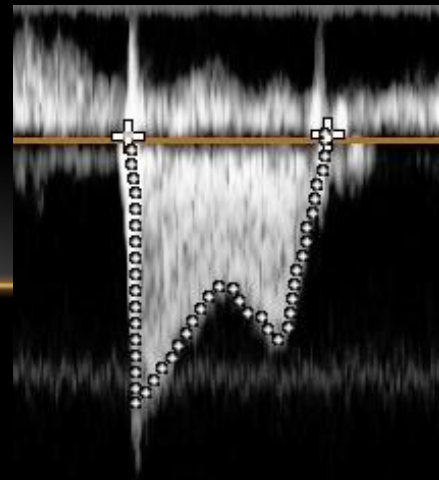


Residual mitral regurgitation



Valve area

Gradient



# Key questions

When compared with traditional 2D or 3D TEE guidance, does this novel technology add advantages in terms of *reduction* of procedural time, radiation exposure, incidence of complications ?

Does it increase operator's confidence?

# Safety and feasibility of novel technology fusing echocardiography and fluoroscopy images during MitraClip interventions

Simon H. Sünder  
Christian Felix<sup>3</sup>, I

1. Division of Cardiology  
Hospital Zurich, Zurich  
4. Institute of Anaes

S. H. Sündermann and

This paper also inclu

## KEYWORDS

- EchoNavigator
- MitraClip
- mitral valve disease
- percutaneous mitral valve repair
- real-time fusion
- structural heart disease interventions

**Table 2. Procedural data.**

	Total (n=42)	with EchoNavigator (n=21)	without EchoNavigator (n=21)	p
Number of clips implanted, n (%)	81 (100%)	45 (56%)	36 (44%)	0.3
Patients with 1/2/3/4 clips (n)	12/23/5/2	4/12/3/2	8/11/2/0	–
Length (minutes) all patients	131±50.3	136.2±50.2	125.7±51.2	0.5
Length (minutes) patients ≤2 clips	112.7±26.8	113.9±29.9	111.8±24.9	0.8
Fluoroscopy time (minutes) all patients	31.4±15.8	32.3±16.8	30.6±15.3	0.8
Fluoroscopy time (minutes) patients ≤2 clips	25.1±7.1	23.9±8.1	26.1±6.4	0.4
Radiation dose (Gy/cm <sup>2</sup> ) all patients	146.7±127.4	146.5±123.6	146.8±134.1	1.0
Radiation dose (Gy/cm <sup>2</sup> ) patients ≤2 clips	112.8±73	102.1±65	119.8±78.9	0.5
Time to first clip (minutes)	53.6±15.8	52.4±17.6 (n=21)	53.7±14.0 (n=21)	0.8
Time to second clip (minutes)	85.7±27.7	83.2±27.4 (n=17)	88.9±29.0 (n=13)	0.6
Time to third clip (minutes)	152.86±47.5	134.2±23.2 (n=5)	199.5±72.8 (n=2)	0.4

The numbers in brackets indicate the number of patients who had implantation of one, two or three clips in the respective group. Gy: gray

**Conclusions:** The use of EchoNavigator software was feasible and safe in all study patients. Further studies are necessary to confirm the benefits of using this software.

Gessat<sup>1,4</sup>, PhD;  
rti<sup>2</sup>, MD, PhD

diology, University  
h, Zurich, Switzerland;

ention/69th\_issue/203

lands) enables real-time  
raphy probe on the x-ray  
MitraClip procedures.

Navigator software (EN+  
dpoints were fluoroscopy  
ents treated immediately  
(6) were implanted in the  
radiation dose (Gy/cm<sup>2</sup>)  
procedure time (minutes)  
p=0.5). The main benefit  
oroscopy, leading to eas-

# Echo

## for tr

Francesco  
Luigi Biasi  
Kuwata<sup>3</sup>,  
Nietlispa

<sup>1</sup>Department of Ca  
Italy; and <sup>3</sup>Universit

Received 7 February

The echocardi  
cilitate cathete  
early developm  
mitral valve tra  
describe the ro  
ciples and the f

### Keywords

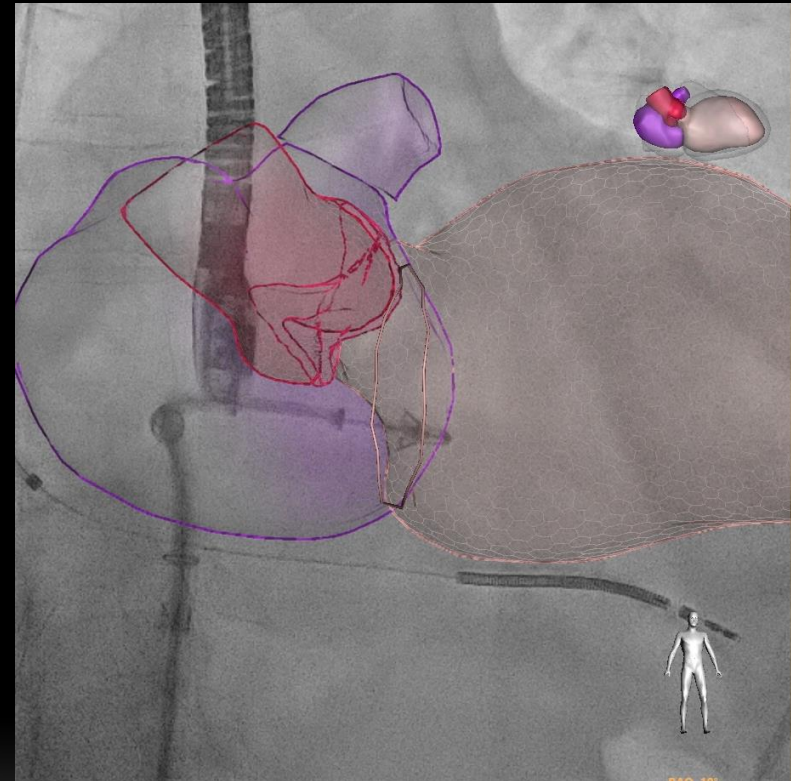
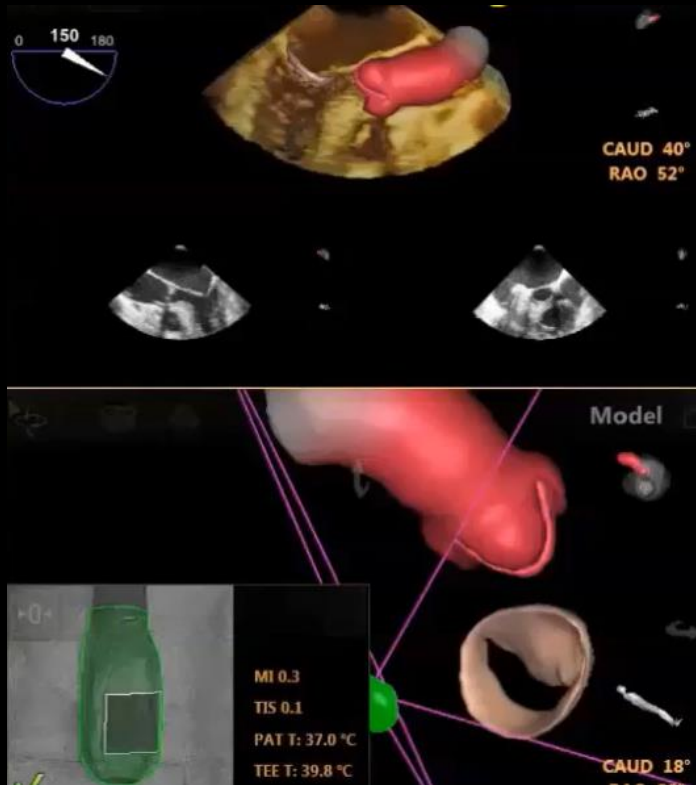
transoesophageal echocardiography • fluoroscopy • mitral valve repair • fusion images

**Table 2** Unpublished data from University Heart Center Zurich on procedural length, fluoroscopic time, and radiation dose with a without fusion

Mitral clip	With fusion	Without fusion	P-value
Degenerative/functional	11/8	11/8	
1, 2, and 3 clips	9/9/1	9/9/1	
Procedural length (min ± ds)			
1 clip	56 ± 20	61 ± 15	0.25 ns
2 clips	65 ± 16	75 ± 21	0.12 ns
3 clips	99 ± 35	108 ± 43	0.51 ns
Fluoroscopy time (min ± ds)			
1 clip	18 ± 7	17 ± 7	0.7 ns
2 clips	22 ± 6	23 ± 10	0.41 ns
3 clips	31 ± 15	33 ± 19	0.93 ns
Radiation dose (Gy/cm <sup>2</sup> ± ds)			
1 clip	25 ± 12	24 ± 15	0.61 ns
2 clip	31 ± 15	32 ± 19	0.73 ns
3 clip	66 ± 21	70 ± 19	0.71 ns
<b>Cardioband</b>	<b>With fusion</b>	<b>Without fusion</b>	<b>P-value</b>
Procedural length (min ± ds)	143 ± 36	125 ± 21	0.41 ns
Fluoroscopy time (min ± ds)	47 ± 12	52 ± 9	0.61 ns
Radiation dose (Gy/cm <sup>2</sup> ± ds)	36 ± 28	40 ± 31	0.85 ns
<b>Paravalvular leak</b>	<b>With EchoNav (2)</b>	<b>Without EchoNav (2)</b>	<b>P-value</b>
	2	2	1 ns
Procedural length (min ± ds)	128 ± 11	115 ± 35	0.65 ns
Fluoroscopy time (min ± ds)	83 ± 27	86 ± 36	0.9 ns

# Fusion Imaging

*Future scenarios Valve modeling*



Courtesy of Philip

# Echocardiographic-fluoroscopic fusion imaging for transcatheter mitral valve repair guidance

Francesco  
Luigi Biasci  
Kuwata<sup>3</sup>, M  
Nietlispach

<sup>1</sup>Department of Cardiac  
Italy; and <sup>3</sup>University H

Received 7 February 201

The echocardiogr  
cilitate catheters  
early development  
mitral valve transc  
describe the role  
ciples and the fluc

## Keywords

## Conclusion

Echocardiography-fluoroscopic fusion imaging couples two 'real-time' imaging techniques showing in the same screen a sort of 'hybrid image' where soft tissues appear onto the fluoroscopic cardiac silhouette. This new imaging modality has the potential to become the main imaging technique in catheter-based SHD interventions. However, the absence of data showing a reduction in terms of procedural and fluoroscopic times, radiation exposure and improved outcomes, hampers its clinical applicability. Though new approach to fusion imaging from different manufactures are likely to emerge in the near future, the fact that this imaging modality is currently provided by a single vendor limits its more widespread use, experience and data collection.

dotti<sup>3</sup>,  
ngo

na 60, 20132 Milan,

he proposal to fa-  
ave described the  
ing technology to  
ew, we, therefore,  
The technical prin-

# Take home message

Without fusion...

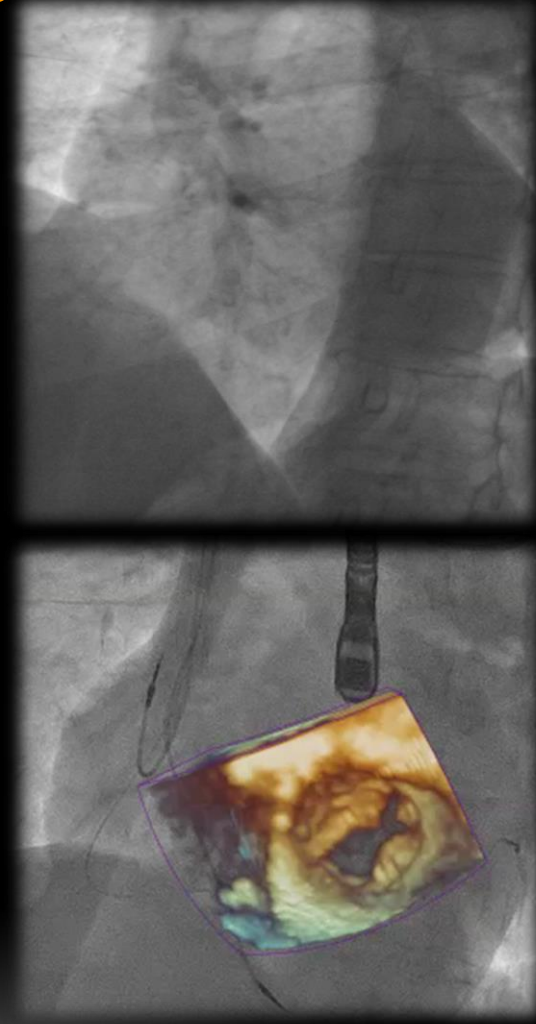
interventional

cardiologists...

*“Oculos habent et non  
videbunt....”*

*New advent Bible:*

*Salm 114/115*



Thank you for your patience

[francesco.faletra@cardiocentro.org](mailto:francesco.faletra@cardiocentro.org)

