



# 31 GIORNATE CARDIOLOGICHE TORINESI

TURIN  
October  
24<sup>th</sup>-26<sup>th</sup>  
2019

## “The challenge: a 90-year-old patient undergoing TAVI”

F. Giordana

Cardiologist

Città della Salute e della Scienza Hospital

Turin



# 31 GIORNATE CARDIOLOGICHE TORINESI

TURIN  
October  
24<sup>th</sup>-26<sup>th</sup>  
2019

**09/2014**

C.P.

94 yo

67 kg x 160 cm

Autonomous in the ADL

1977 AMI

Peripheral vasculopathy

Hospital admission for heart failure. Dyspnoea NYHA III.

**PE** : Killip II, rythmic tones, systolic murmur 4/6 para-sternal

**ECG** : RS FC 100 bpm, LV hypertrophy

**Lab**: crea 0.7 (GFR= 70 ml/min), Tnt 262, Hb 11 mg/dl





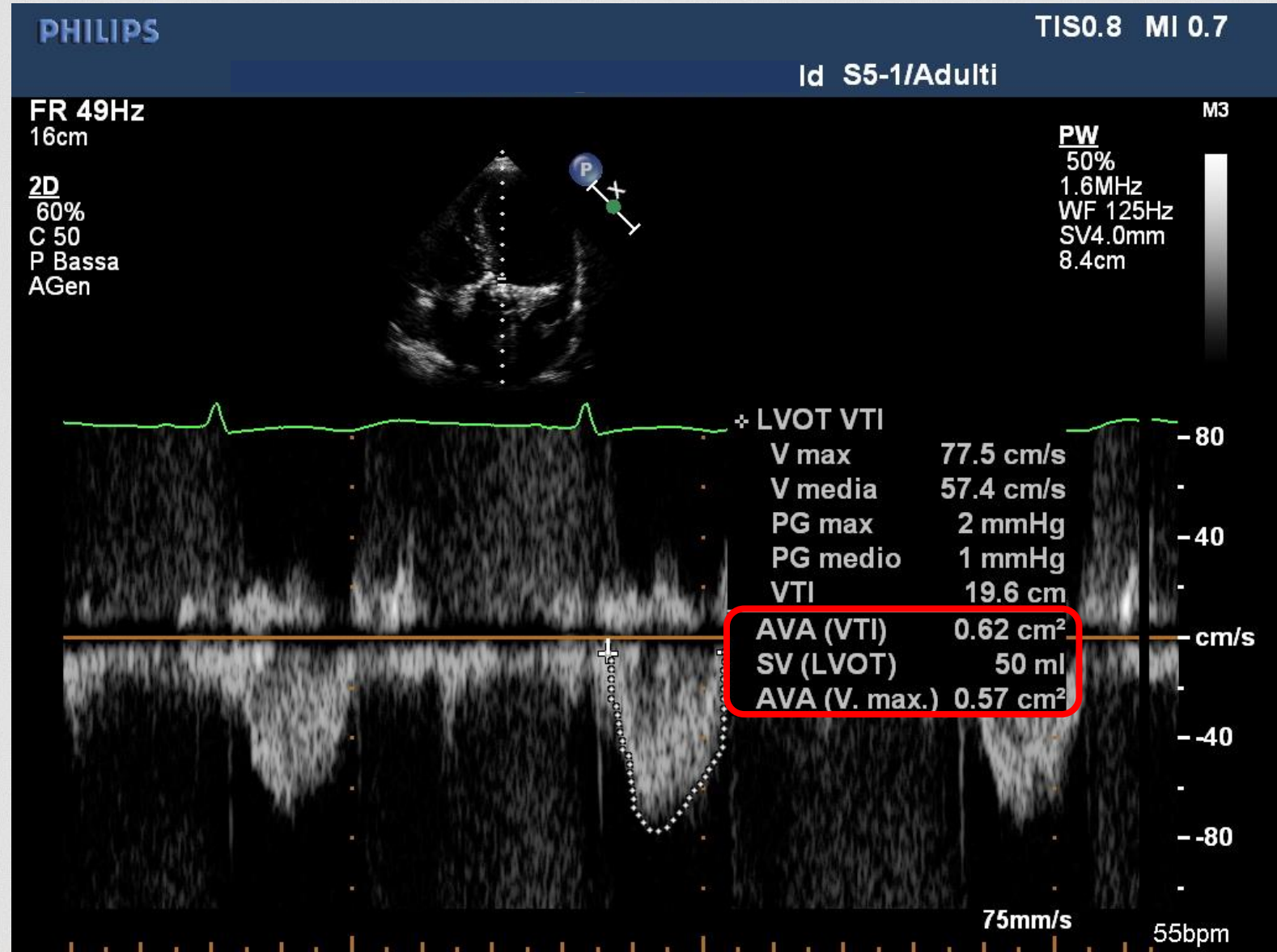
# 31 GIORNATE CARDIOLOGICHE TORINESI

TURIN  
October  
24<sup>th</sup>-26<sup>th</sup>  
2019

## TT echo

- LVEF 53%
- Moderate MR
- esPAP 50 mmHg

**PARADOXICAL SEVERE  
AORTIC STENOSIS**

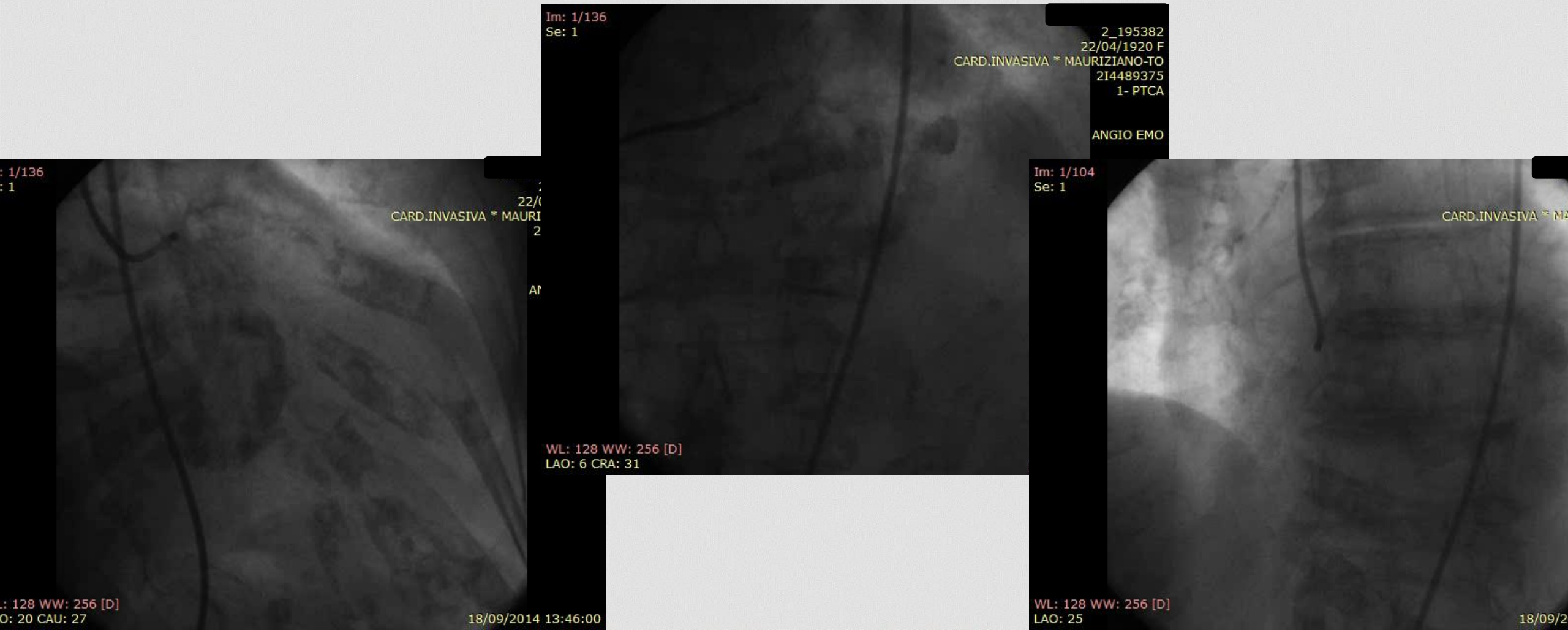




# 31 GIORNATE CARDIOLOGICHE TORINESI

TURIN  
October  
24<sup>th</sup>-26<sup>th</sup>  
2019

## Coronary angiogram: multivessel disease

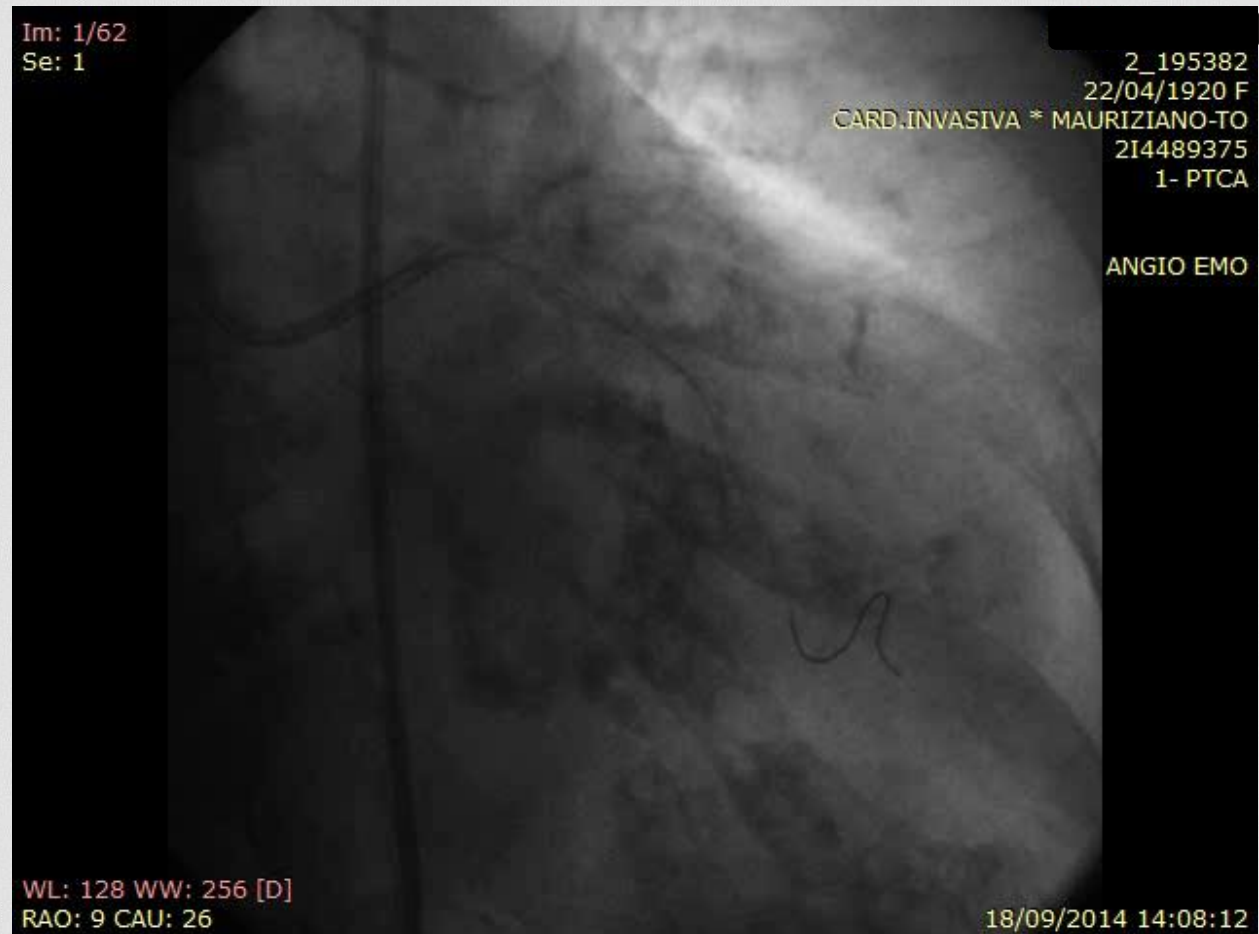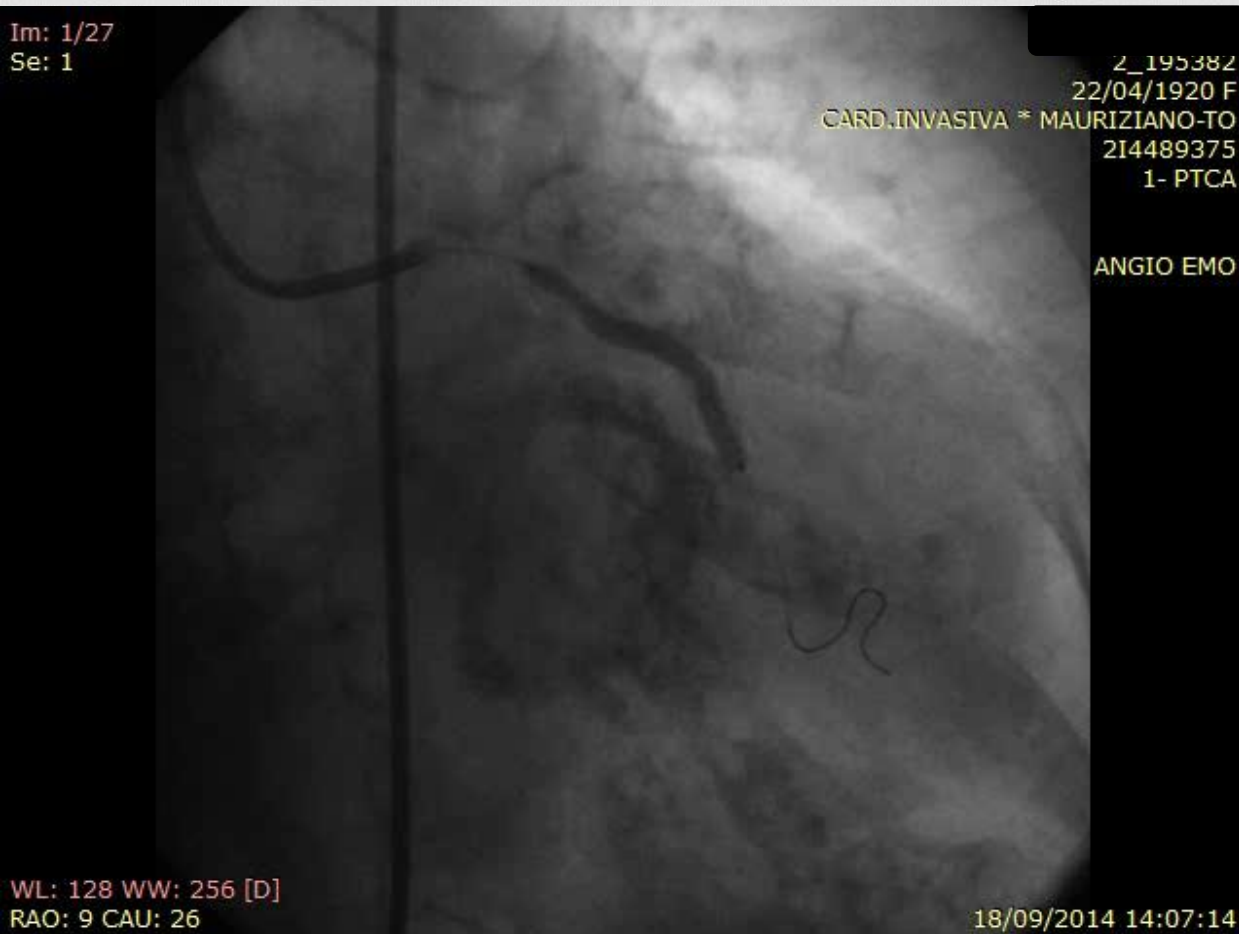




# 31 GIORNATE CARDIOLOGICHE TORINESI

TURIN  
October  
24<sup>th</sup>-26<sup>th</sup>  
2019

## PTCA+DES su Cfx

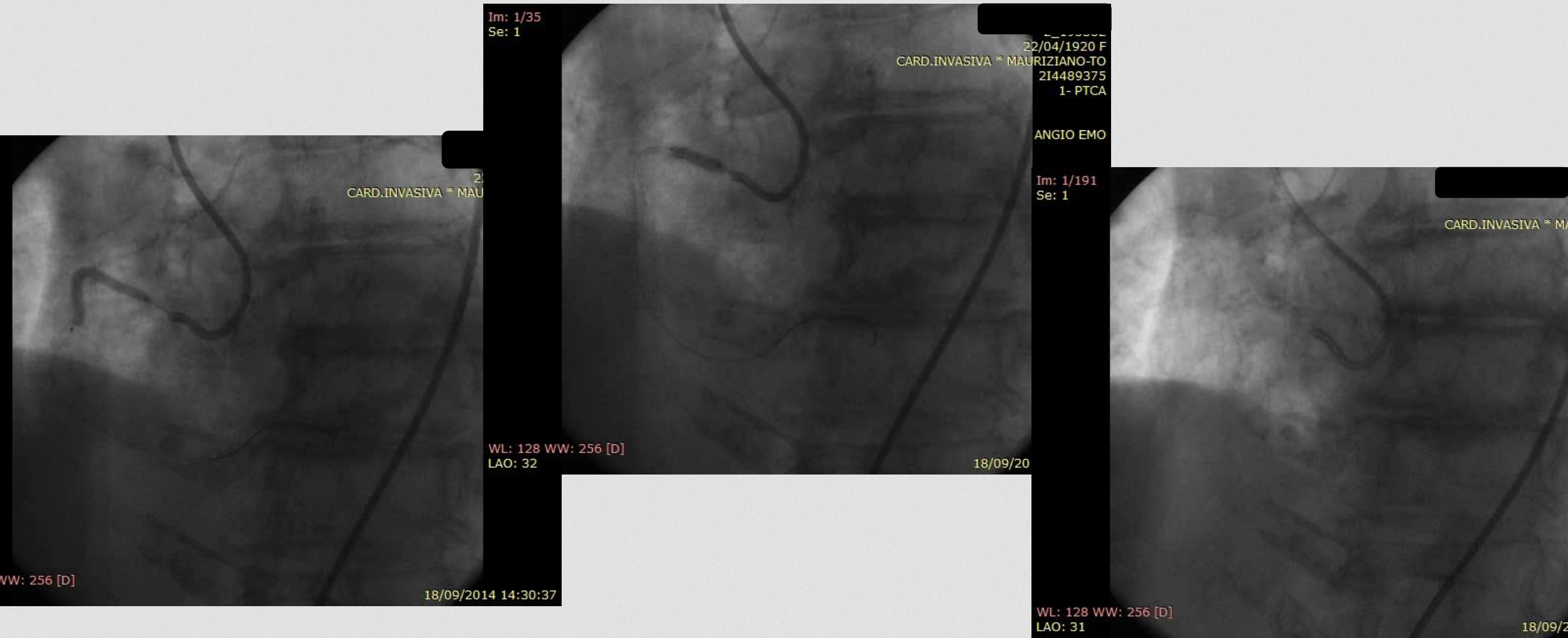




# 31 GIORNATE CARDIOLOGICHE TORINESI

TURIN  
October  
24<sup>th</sup>-26<sup>th</sup>  
2019

## PTCA+DES su RCA I-II





# 31 GIORNATE CARDIOLOGICHE TORINESI

TURIN  
October  
24<sup>th</sup>-26<sup>th</sup>  
2019



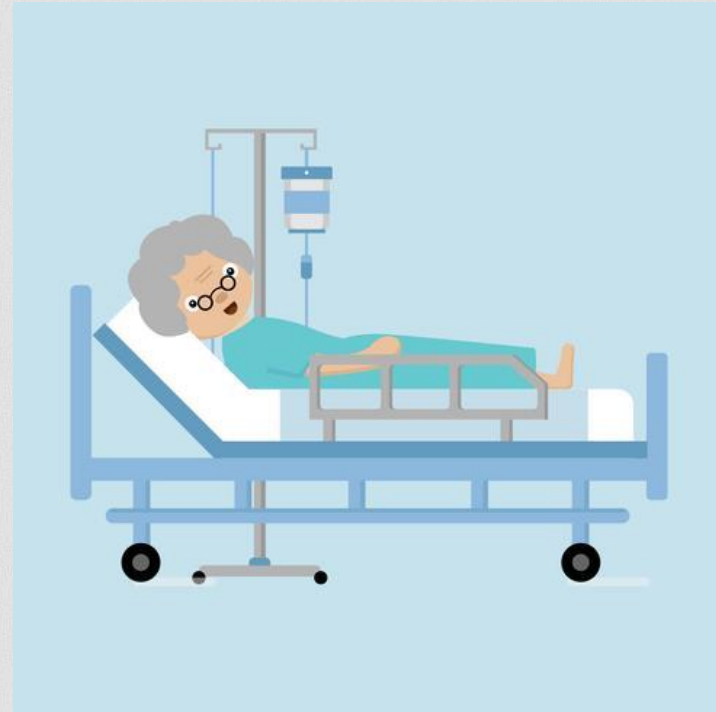




# 31 GIORNATE CARDIOLOGICHE TORINESI

TURIN  
October  
24<sup>th</sup>-26<sup>th</sup>  
2019

02/2015  
NYHA IIIb



**TT ECHO: FE 55%**  
**grad 50/30 mmHg**  
**AVA 0.6 cmq**  
**Svi 29 ml/mq**



# 31 GIORNATE CARDIOLOGICHE TORINESI

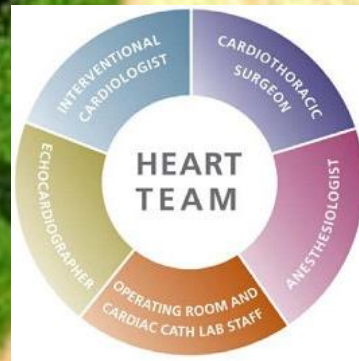
TURIN  
October  
24<sup>th</sup>-26<sup>th</sup>  
2019

1°

MT

BAV

TAVI



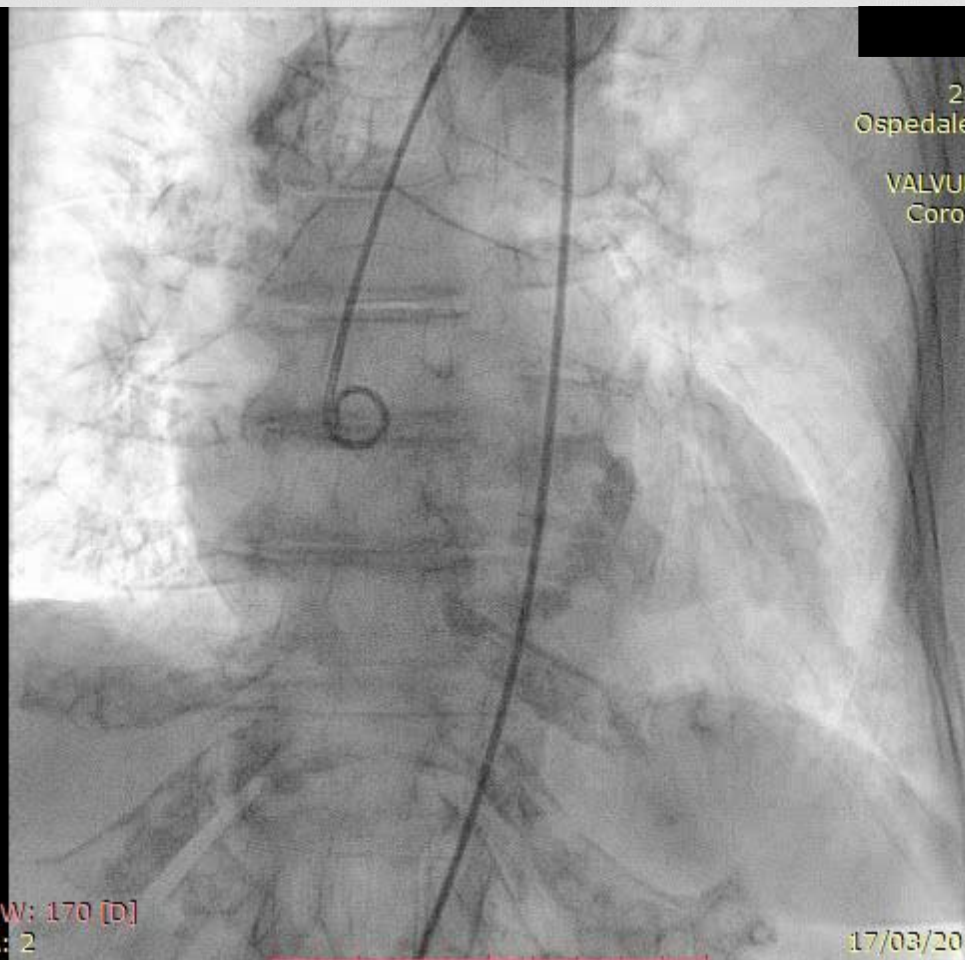


# 31 GIORNATE CARDIOLOGICHE TORINESI

TURIN  
October  
24<sup>th</sup>-26<sup>th</sup>  
2019

**BAV**

Im: 1/60  
Se: 15



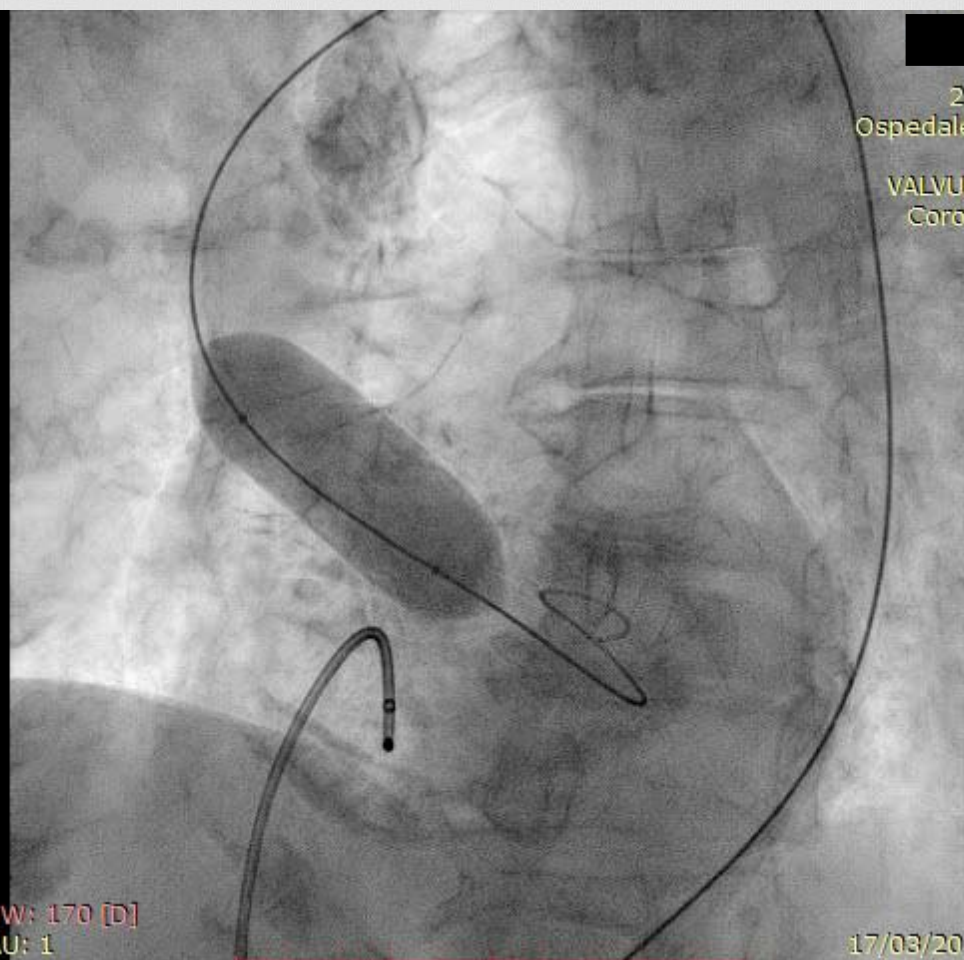
2\_195382  
22/04/1920 F  
Ospedale Mauriziano  
2I4681367  
VALVULOPLASTICA  
Coro 15 fpsNorm

ANGIO EMO

WL: 129 WW: 170 [D]  
LAO: 2 CRA: 2

17/03/2015 11:43:37

Im: 1/17  
Se: 18



2\_195382  
22/04/1920 F  
Ospedale Mauriziano  
2I4681367  
VALVULOPLASTICA  
Coro 15 fpsNorm

ANGIO EMO

WL: 129 WW: 170 [D]  
LAO: 35 CAU: 1

17/03/2015 11:43:37



# 31 GIORNATE CARDIOLOGICHE TORINESI

TURIN  
October  
24<sup>th</sup>-26<sup>th</sup>  
2019

FU 06/2015 : NYHA II, autonomous

FU 01/2016: NYHA IIIb



## **EChOFAST:**

Ao mean grad = 42 mmHg

LVEF 58%

mild to moderate MR



# 31 GIORNATE CARDIOLOGICHE TORINESI

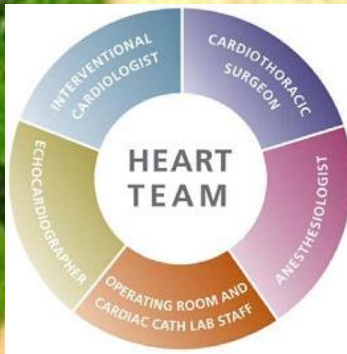
TURIN  
October  
24<sup>th</sup>-26<sup>th</sup>  
2019

2°

MT

BAV

TAVI





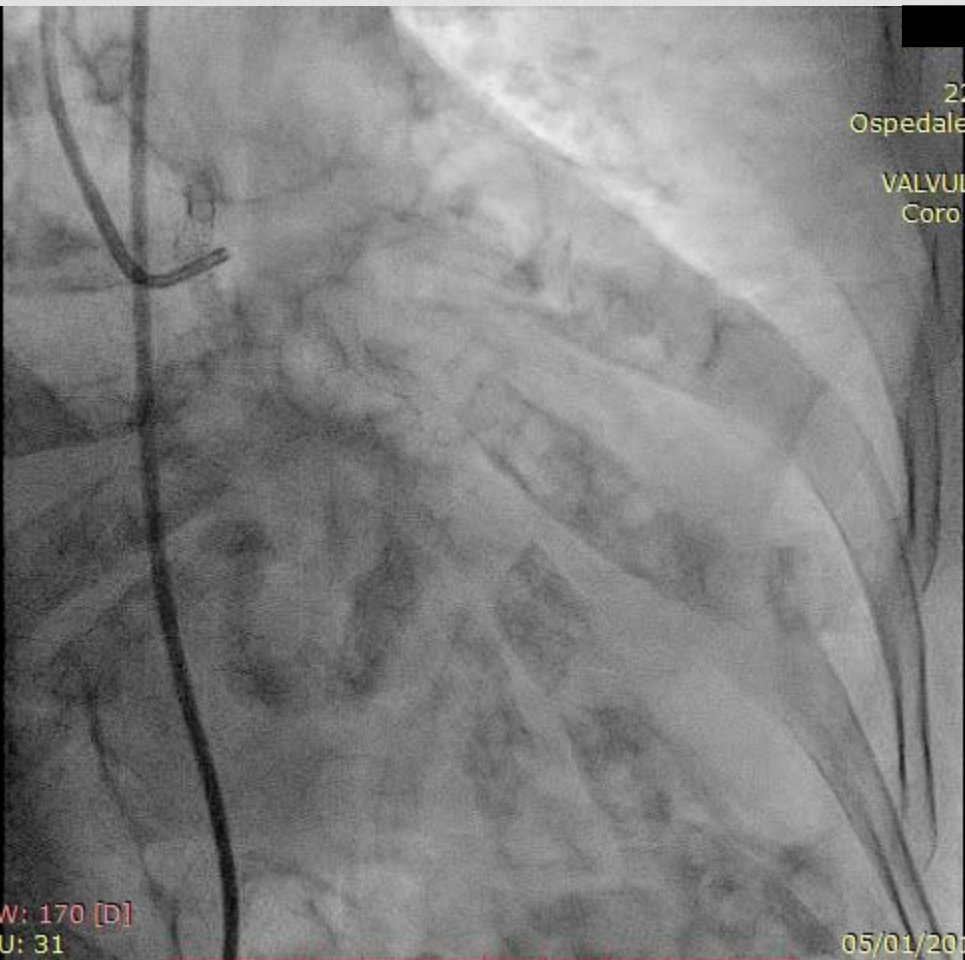# 31 GIORNATE CARDIOLOGICHE TORINESI

TURIN  
October  
24<sup>th</sup>-26<sup>th</sup>  
2019

Coronary angiogram

ISR RCA II

Im: 1/65  
Se: 1



Im: 1/69  
Se: 4  
2\_195382  
22/04/1920 F  
Ospedale Mauriziano  
214962972  
VALVULOPLASTICA  
Coro 15 fpsNorm

ANGIO EMO

WL: 129 WW: 170 [D]  
RAO: 21 CAU: 31

05/01/2016 10:12:14

Im: 1/69  
Se: 4  
2\_195382  
22/04/1920 F  
Ospedale Mauriziano  
214962972  
VALVULOPLASTICA  
Coro 15 fpsNorm

ANGIO EMO

WL: 129 WW: 170 [D]

LAO: 28 CRA: 4

05/01/2016 10:12:14

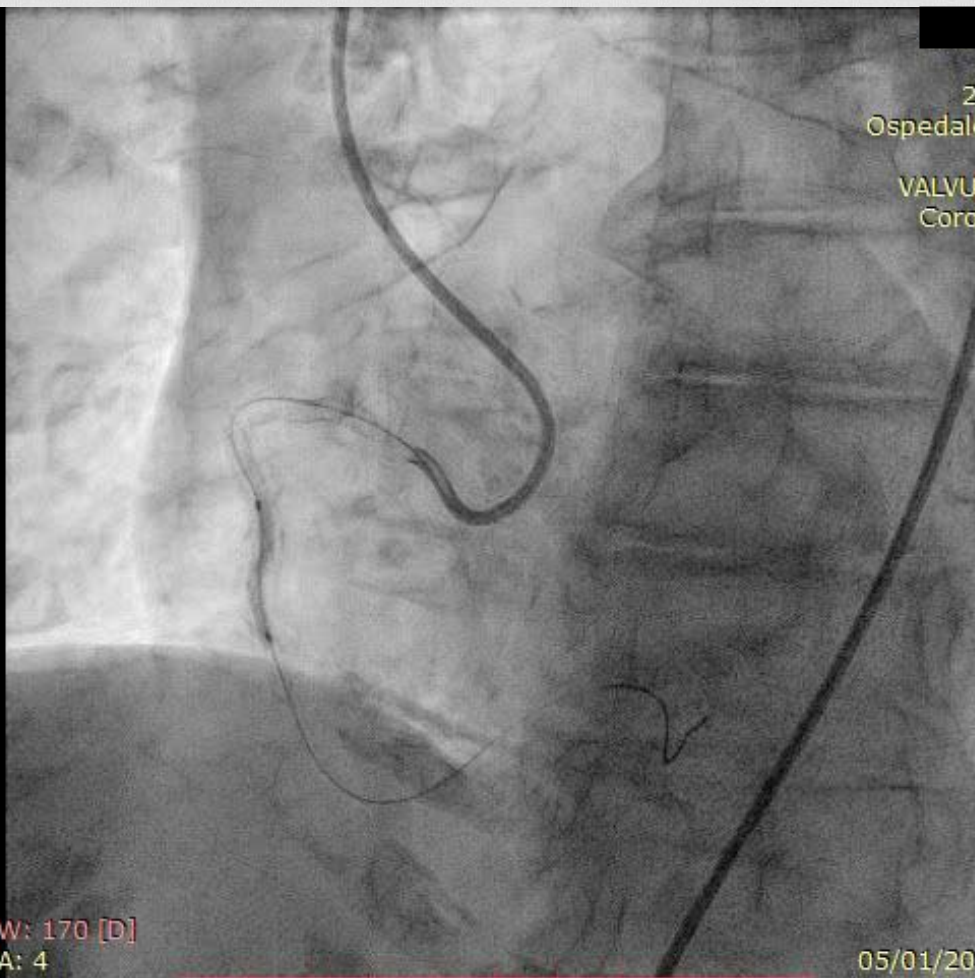


# 31 GIORNATE CARDIOLOGICHE TORINESI

TURIN  
October  
24<sup>th</sup>-26<sup>th</sup>  
2019

## POBA + DEB RCA II

Im: 1/23  
Se: 5

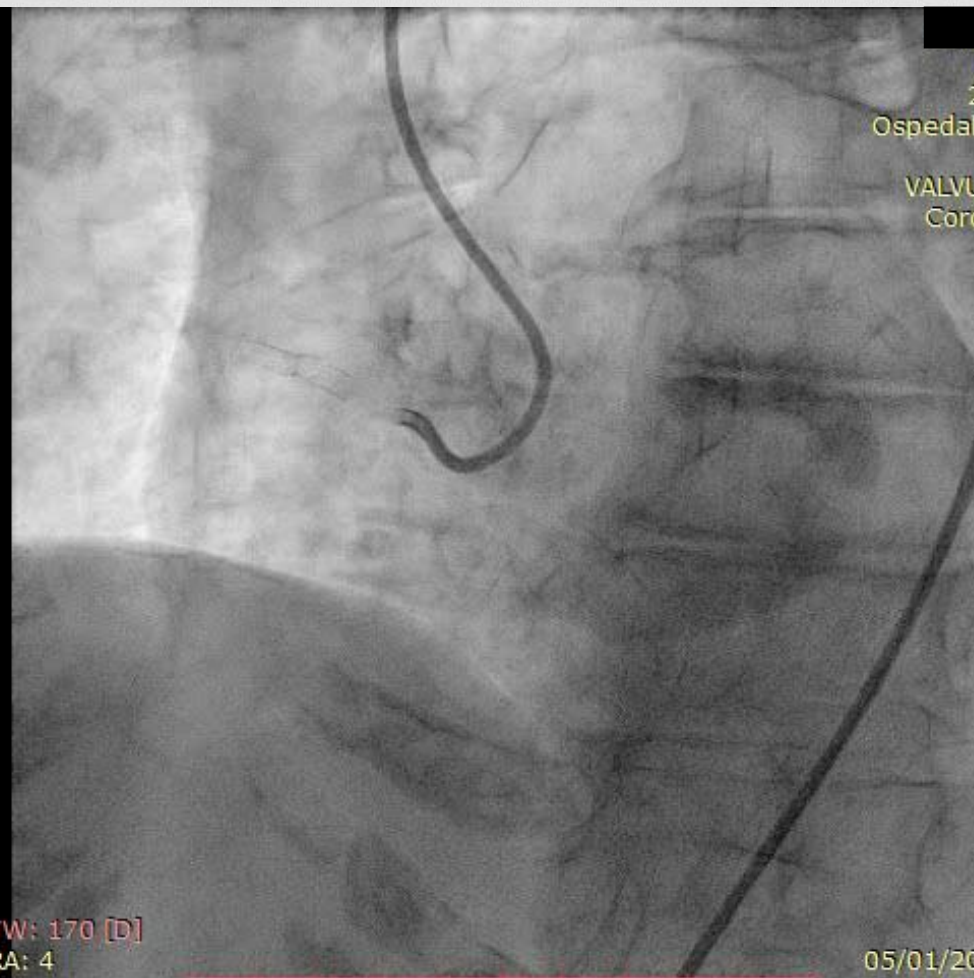


2\_195382  
22/04/1920 F  
Ospedale Mauriziano  
2I4962972  
VALVULOPLASTICA  
Coro 15 fpsNorm  
ANGIO EMO

WL: 129 WW: 170 [D]  
LAO: 28 CRA: 4

05/01/2016 10:12:14

Im: 1/72  
Se: 13



2\_195382  
22/04/1920 F  
Ospedale Mauriziano  
2I4962972  
VALVULOPLASTICA  
Coro 15 fpsNorm  
ANGIO EMO

WL: 129 WW: 170 [D]  
LAO: 28 CRA: 4

05/01/2016 10:12:14

05/01/2016 10:12:14

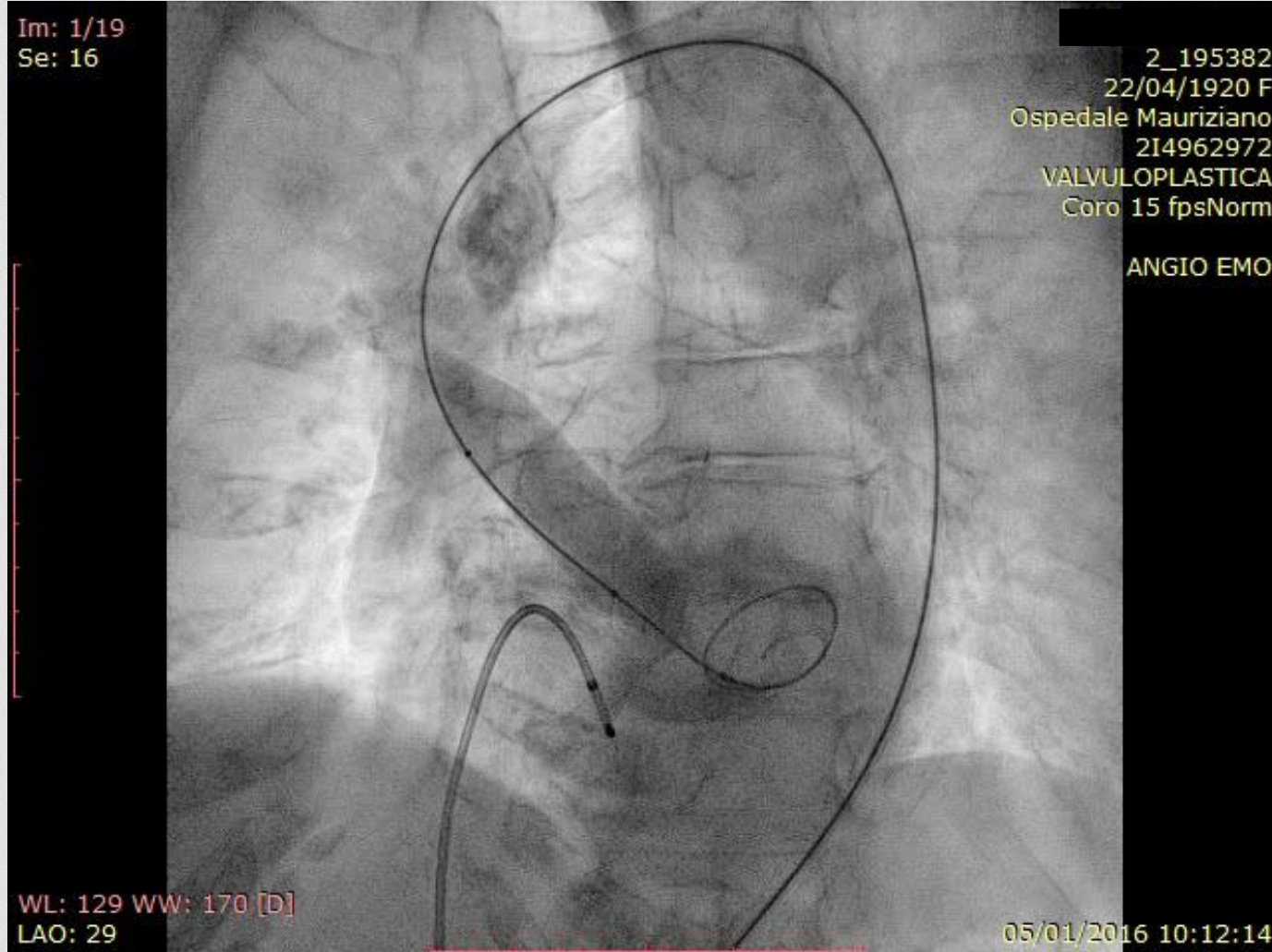


# 31 GIORNATE CARDIOLOGICHE TORINESI

TURIN  
October  
24<sup>th</sup>-26<sup>th</sup>  
2019

BAV

Im: 1/19  
Se: 16



2\_195382  
22/04/1920 F  
Ospedale Mauriziano  
2I4962972  
VALVULOPLASTICA  
Coro 15 fpsNorm

ANGIO EMO

WL: 129 WW: 170 [D]  
LAO: 29

05/01/2016 10:12:14





# 31 GIORNATE CARDIOLOGICHE TORINESI

TURIN  
October  
24<sup>th</sup>-26<sup>th</sup>  
2019

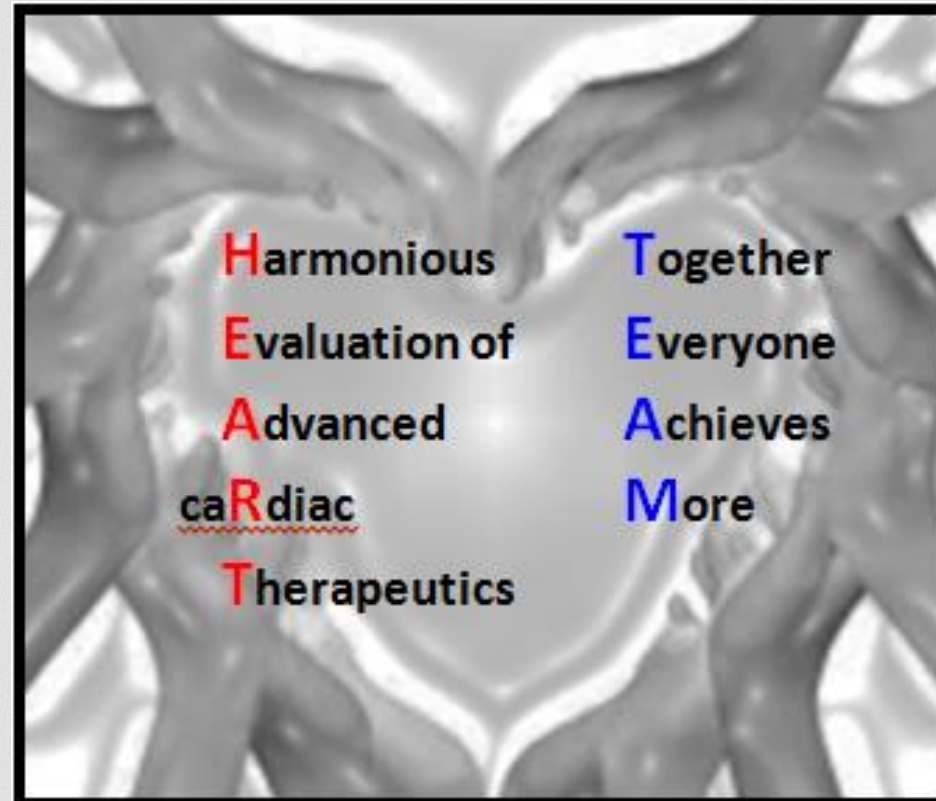
- 03/2016 FU NYHA II-III , stable
- 10/2016 Acute pulmonary edema

Age

Vasculopathy

Life expectancy

Cost/benefit





# 31 GIORNATE CARDIOLOGICHE TORINESI

TURIN  
October  
24<sup>th</sup>-26<sup>th</sup>  
2019

