



31 GIORNATE CARDIOLOGICHE TORINESI

TURIN
October
24th-26th
2019



**WE DON'T HAVE ENOUGH EVIDENCE, WE TRUST OUR
EXPERIENCE - Part 1**

Chairpersons: C. DI MARIO, A. LERMAN

Expert Discussants: M. LEONCINI, M. MARCOLONGO, F. MARIANI,
U. PARRAVICINI, A. ROGNONI, A. TRUFFA-GIACHET



**A patient with Takotsubo and co-existent CAD:
“the challenge”**



Giorgio Quadri

Interventional Cardiology Unit

ASL TORINO 3 Ospedale degli Infermi - Rivoli (TO)

AOU San Luigi Gonzaga - Orbassano (TO)





31 GIORNATE CARDIOLOGICHE TORINESI

TURIN
October
24th-26th
2019



WE DON'T HAVE ENOUGH EVIDENCE, WE TRUST OUR
EXPERIENCE - Part 1

Chairpersons: C. DI MARIO, A. LERMAN

Expert Discussants: M. LEONCINI, M. MARCOLONGO, F. MARIANI,
U. PARRAVICINI, A. ROGNONI, A. TRUFFA-GIACHET



**Two patients with Takotsubo and co-existent CAD:
“the challenge”**



Giorgio Quadri

Interventional Cardiology Unit

ASL TORINO 3 Ospedale degli Infermi - Rivoli (TO)

AOU San Luigi Gonzaga - Orbassano (TO)





31 GIORNATE CARDIOLOGICHE TORINESI

TURIN
October
24th-26th
2019

Marta, 76 y.o woman

CV risk factors: none

CV history: silent

Comorbidities : depressive disorder

Therapy : paroxetine

Giulia, 82 y.o woman

CV risk factors: hypertension

CV history: silent

Comorbidities: GERD

Therapy : ramipril 2.5 mg, esomeprazol



31 GIORNATE CARDIOLOGICHE TORINESI

TURIN
October
24th-26th
2019

Marta



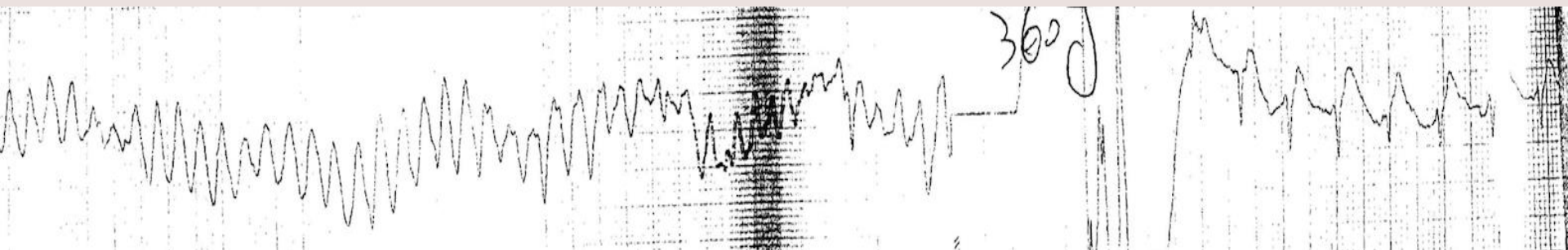


31 GIORNATE CARDIOLOGICHE TORINESI

TURIN
October
24th-26th
2019

Marta

Three days after: loss of consciousness → CPR by son → 118



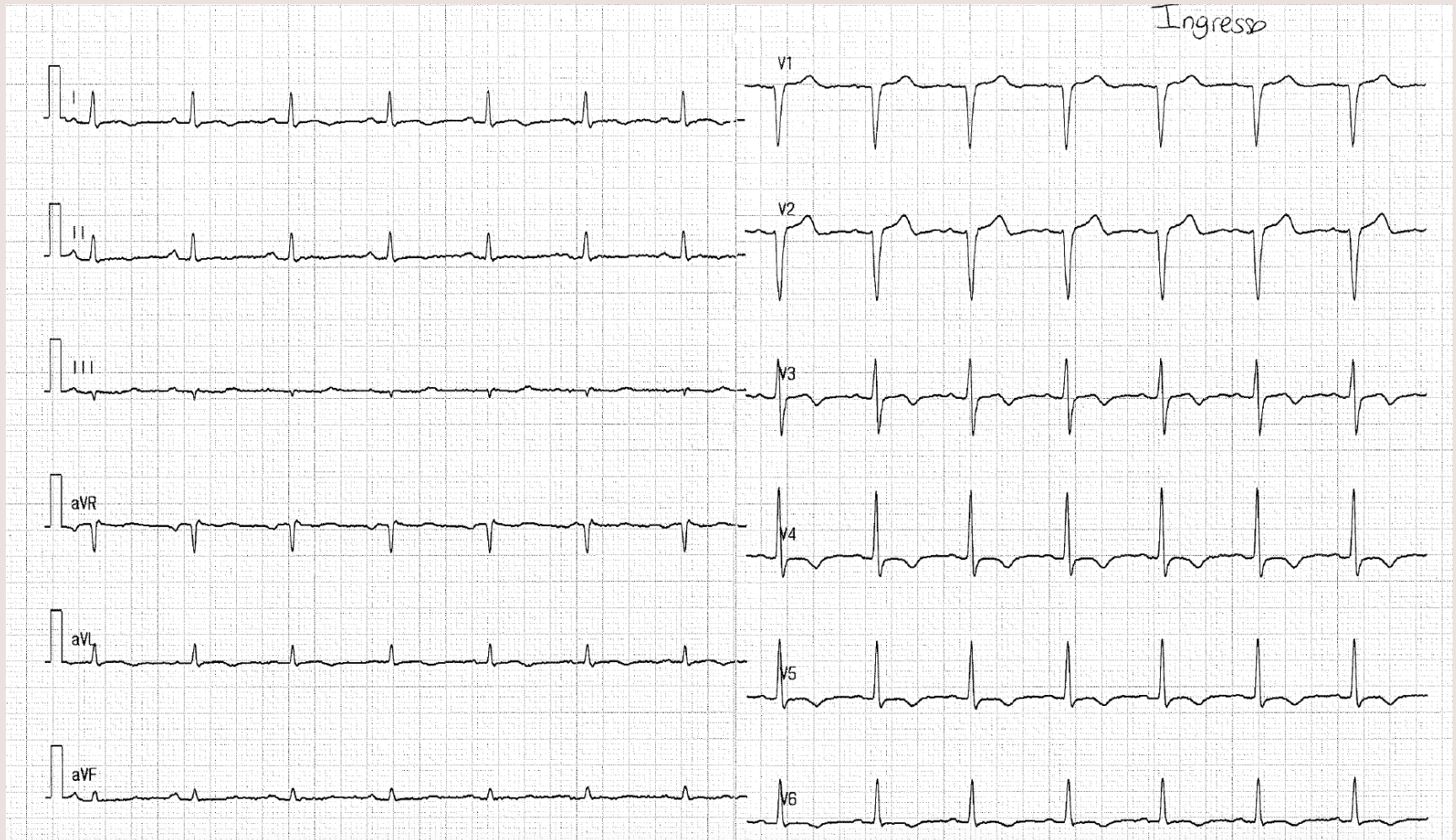
EMERGENCY DEPARTMENT



31 GIORNATE CARDIOLOGICHE TORINESI

TURIN
October
24th-26th
2019

Marta

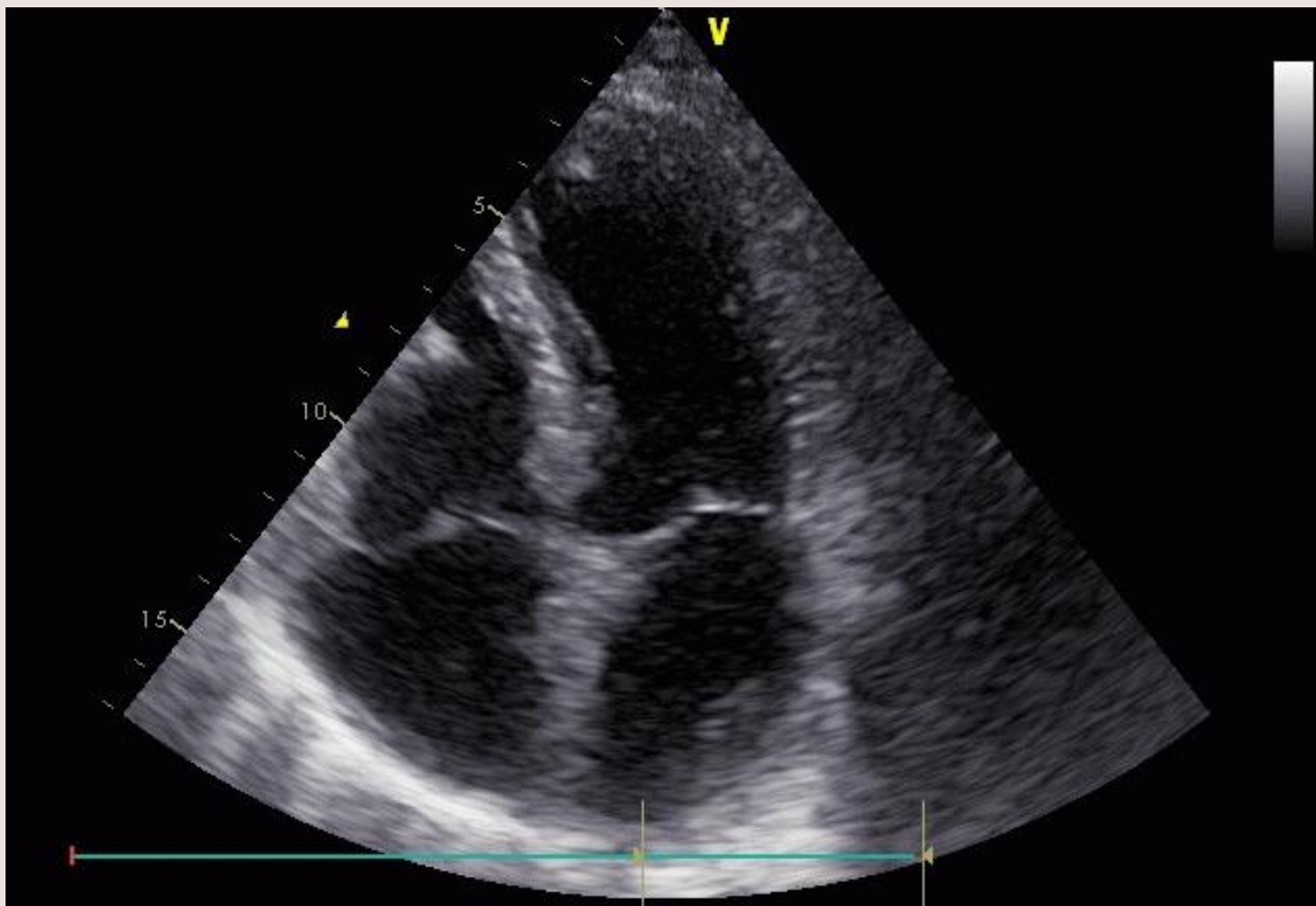



31 GIORNATE CARDIOLOGICHE TORINESI

TURIN
October
24th-26th
2019

Marta





31 GIORNATE CARDIOLOGICHE TORINESI

TURIN
October
24th-26th
2019

Marta

Therapy

ACETILSALICILIC ACID 250 MG
TICAGRELOR 180 MG
UFH 5000 U



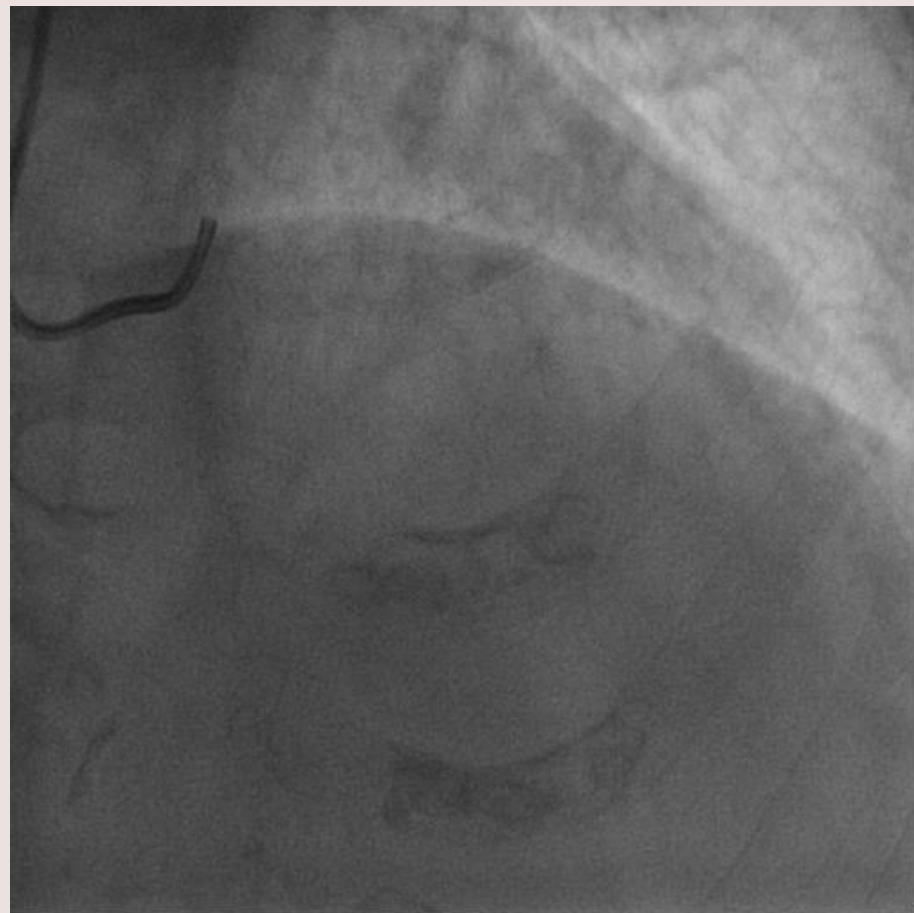
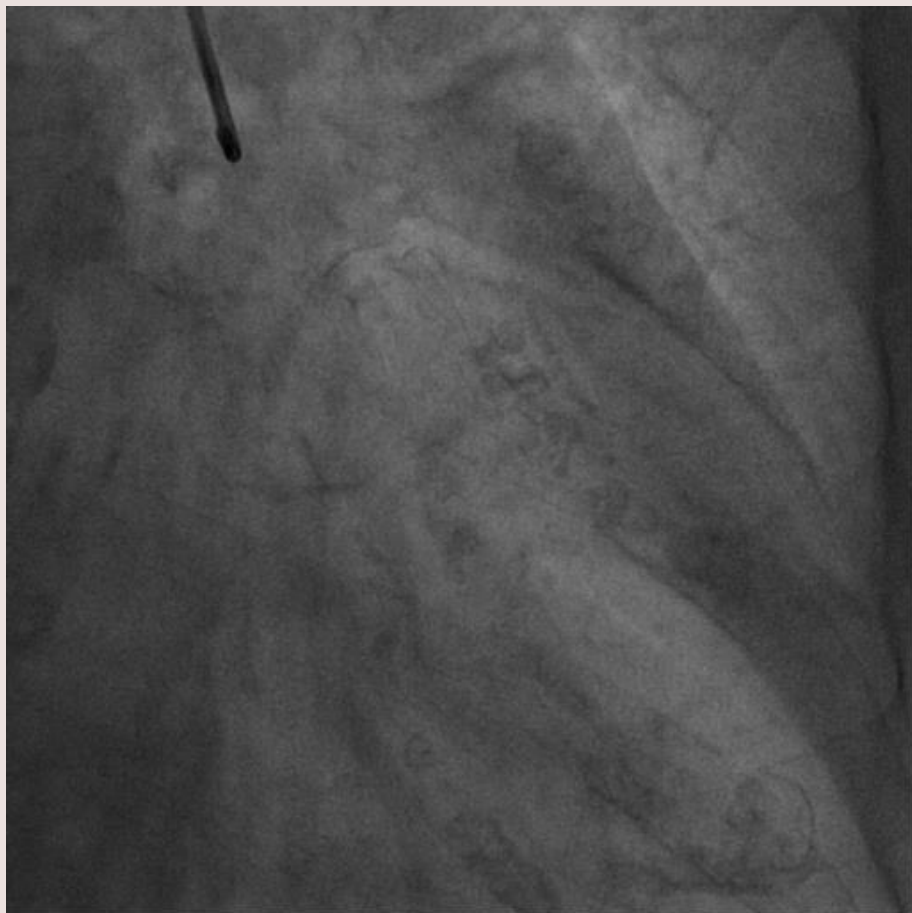
CATH LAB



31 GIORNATE CARDIOLOGICHE TORINESI

TURIN
October
24th-26th
2019

Marta

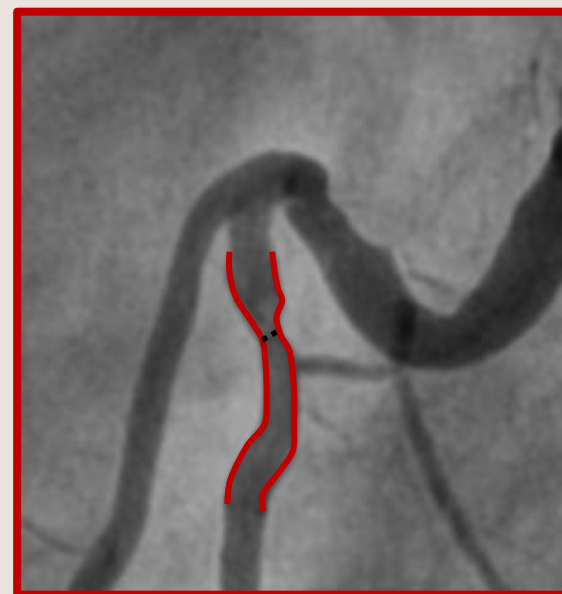
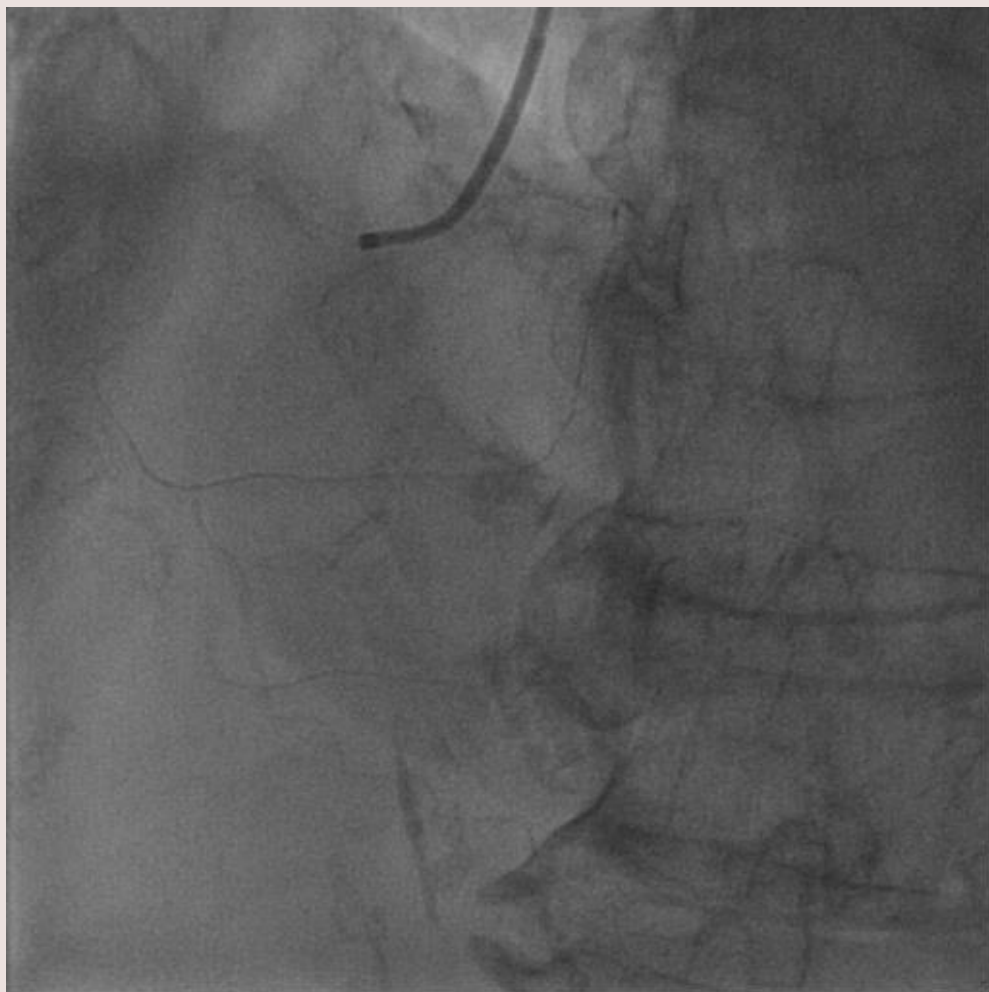




31 GIORNATE CARDIOLOGICHE TORINESI

TURIN
October
24th-26th
2019

Marta



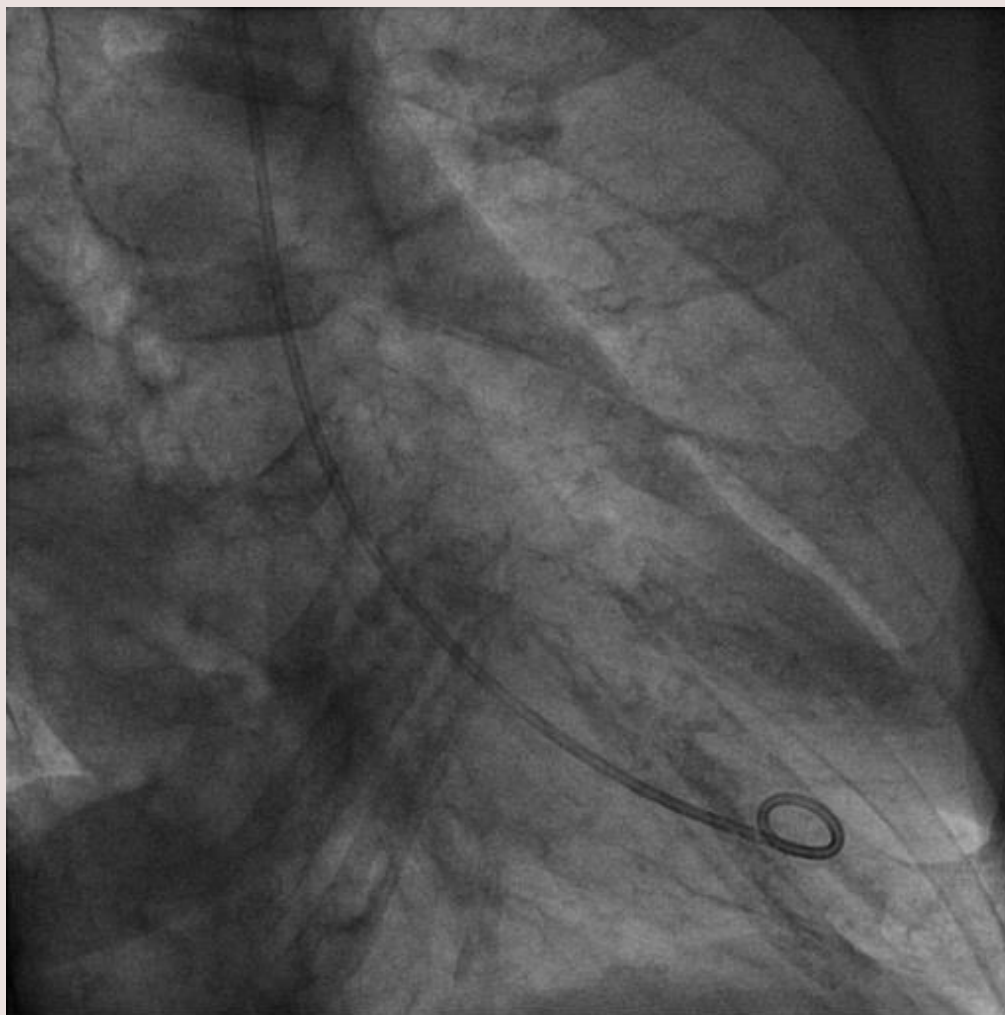
50-60% stenosis



31 GIORNATE CARDIOLOGICHE TORINESI

TURIN
October
24th-26th
2019

Marta





31 GIORNATE CARDIOLOGICHE TORINESI

TURIN
October
24th-26th
2019

Giulia



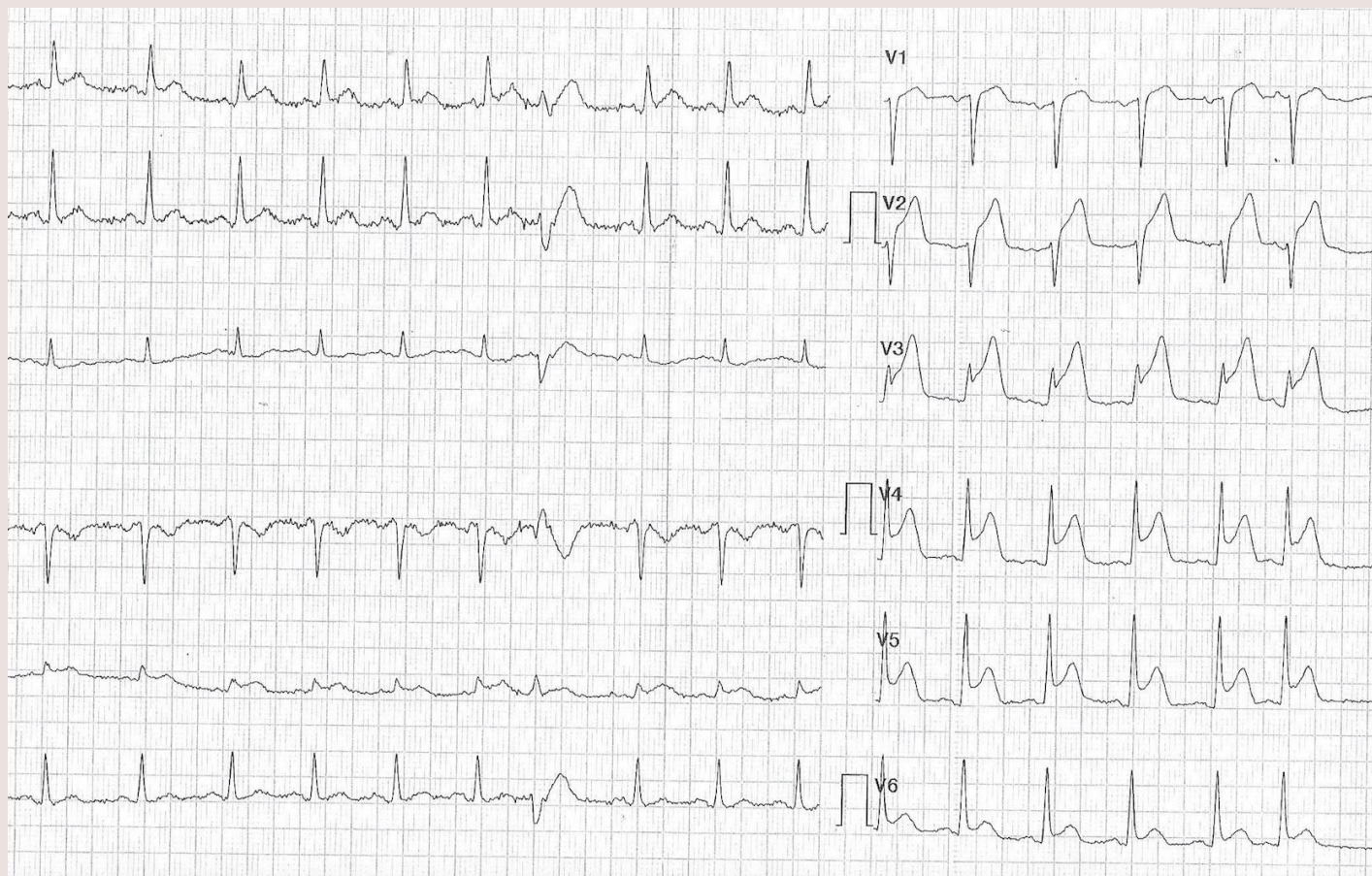


31 GIORNATE CARDIOLOGICHE TORINESI

TURIN
October
24th-26th
2019

Giulia

The day after: **CHEST PAIN → ED**





31 GIORNATE CARDIOLOGICHE TORINESI

TURIN
October
24th-26th
2019

Giulia

Therapy

ACETILSALICILIC ACID 250 MG

TICAGRELOR 180 MG

UFH 5000 U



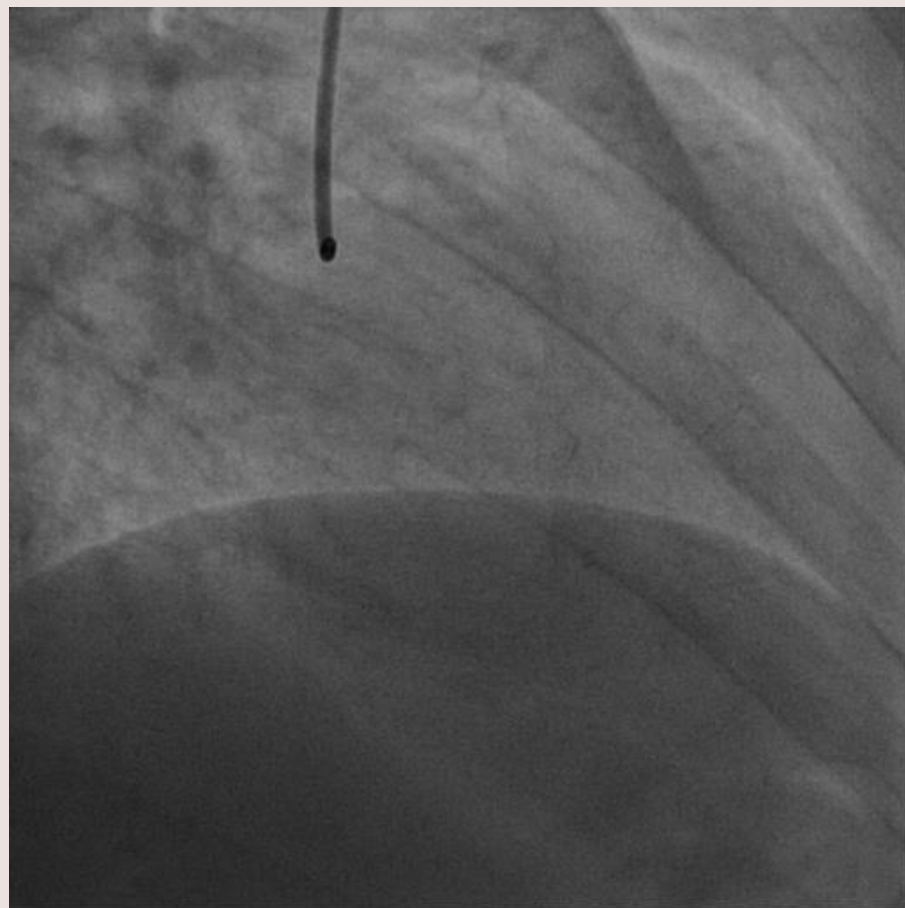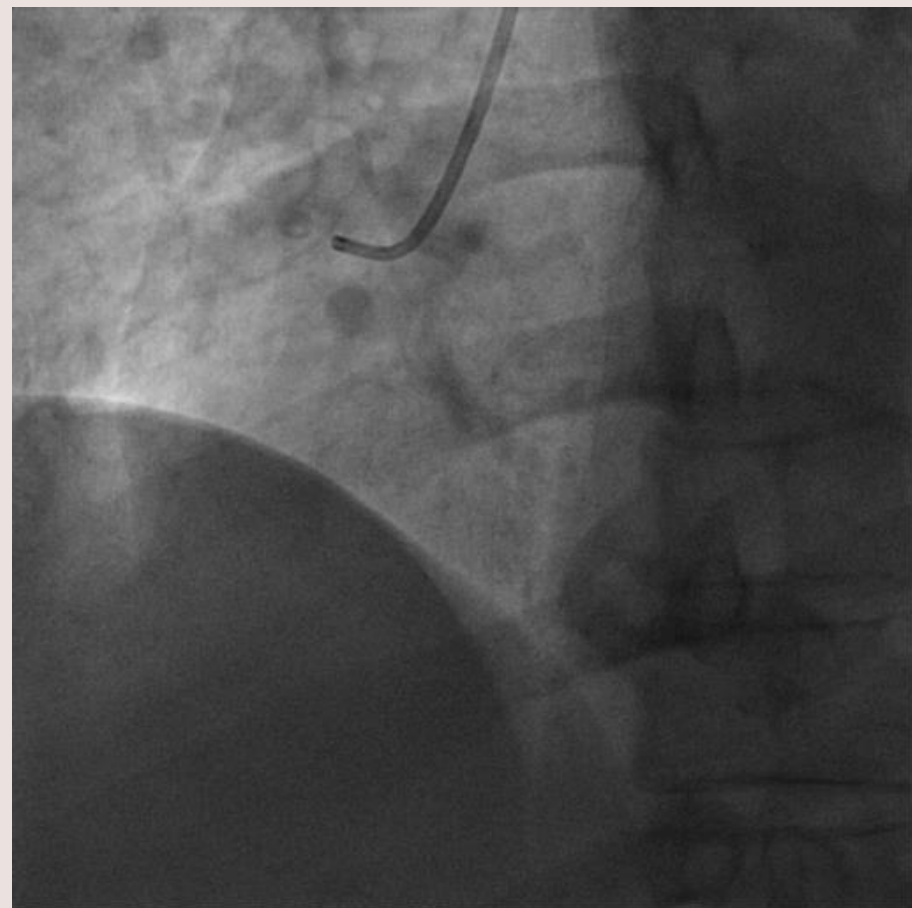
CATH LAB



31 GIORNATE CARDIOLOGICHE TORINESI

TURIN
October
24th-26th
2019

Giulia

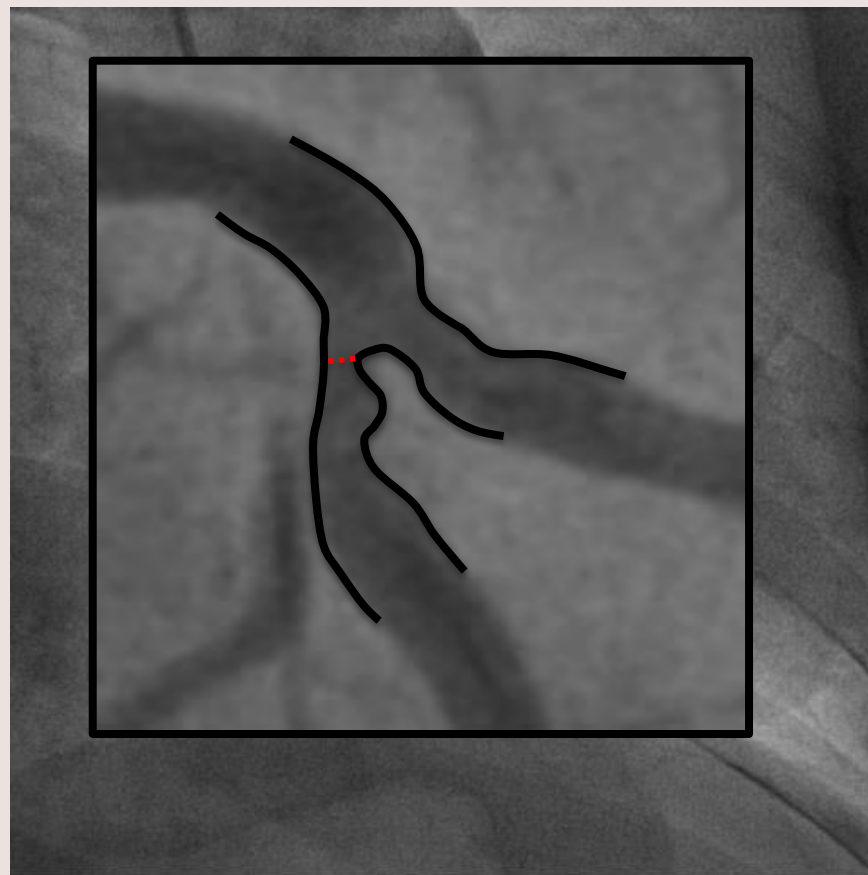
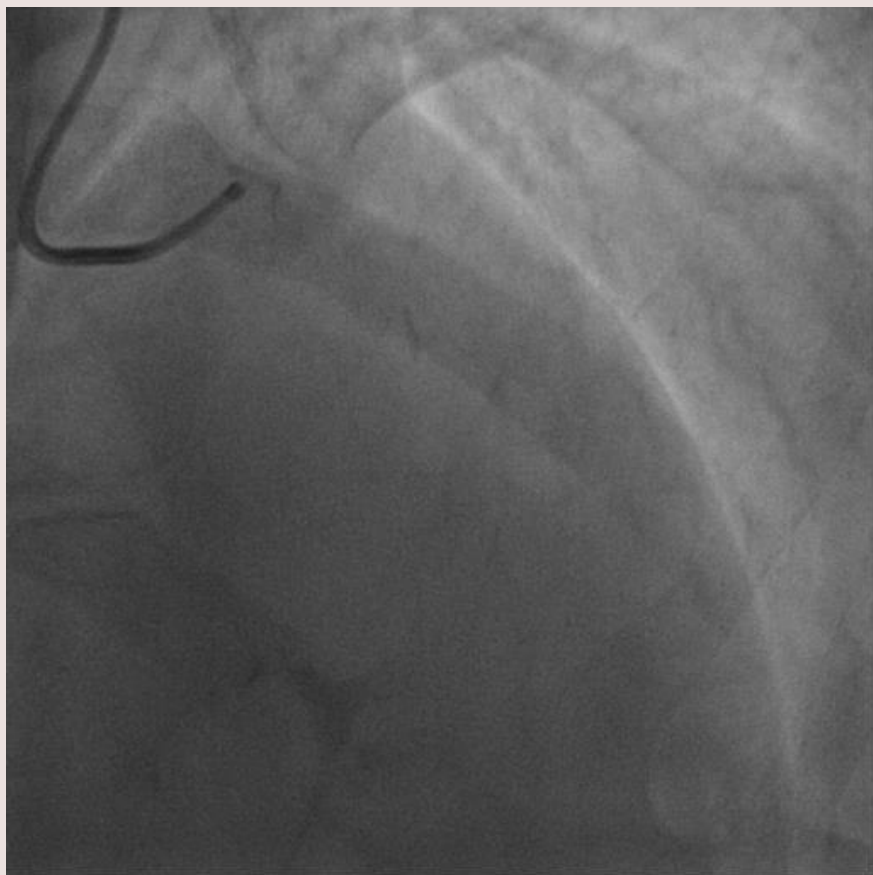




31 GIORNATE CARDIOLOGICHE TORINESI

TURIN
October
24th-26th
2019

Giulia



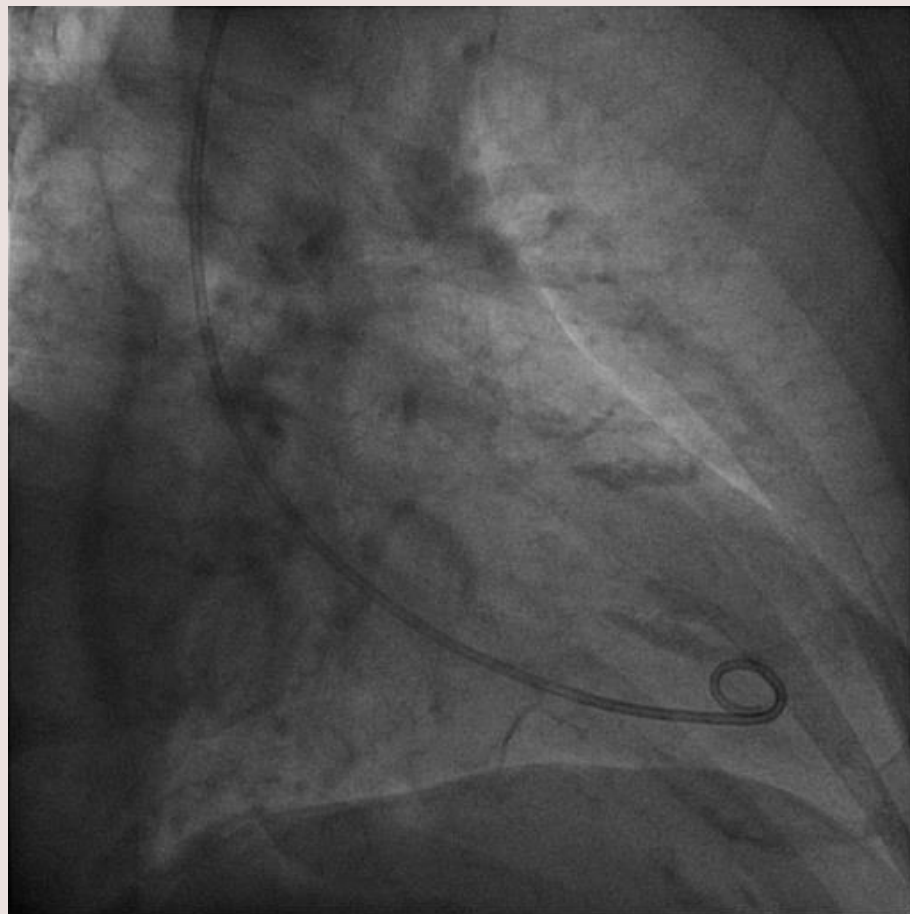
70-80% stenosis



31 GIORNATE CARDIOLOGICHE TORINESI

TURIN
October
24th-26th
2019

Giulia





31 GIORNATE CARDIOLOGICHE TORINESI

TURIN
October
24th-26th
2019

SUMMARY

Marta, 76 y.o woman

CV risk factors: none

CV history: silent

Comorbidities : depression

Therapy : paroxetine

Possible trigger : husband's death

Clinical presentation: cardiac arrest

EKG: VF → t wave inversion

L. ventricle: apical ballooning

Angio: 1-vessel disease
intermediate RCA stenosis

Giulia, 82 y.o woman

CV risk factors: hypertension

CV history: silent

Comorbidities: GERD

Therapy : ramipril 2.5 mg, esomeprazol

Possible trigger : grandson's graduation

Clinical presentation: chest pain

EKG: anterior ST-segment elevation

L. ventricle: apical ballooning

Angio: 1-vessel disease:
70-80% LAD stenosis



31 GIORNATE CARDIOLOGICHE TORINESI

TURIN
October
24th-26th
2019

Marta, 76 y.o woman

Giulia, 82 y.o woman

BOTH TAKOTSUBO?

WHICH TREATMENT FOR CAD?